Anatomy and Testing Procedures: Hormonal, Neurologic, Vascular

Irwin Goldstein, MD
Director, San Diego Sexual Medicine
Director, Sexual Medicine, Alvarado Hospital, San Diego, CA
Clinical Professor of Surgery, University of California at San Diego
Editor-in-Chief, *Sexual Medicine Reviews*
Editor Emeritus, *The Journal of Sexual Medicine*
Editor Emeritus, *International Journal of Impotence Research*

Diagnosis and Treatment Algorithm for Sexual Dysfunction

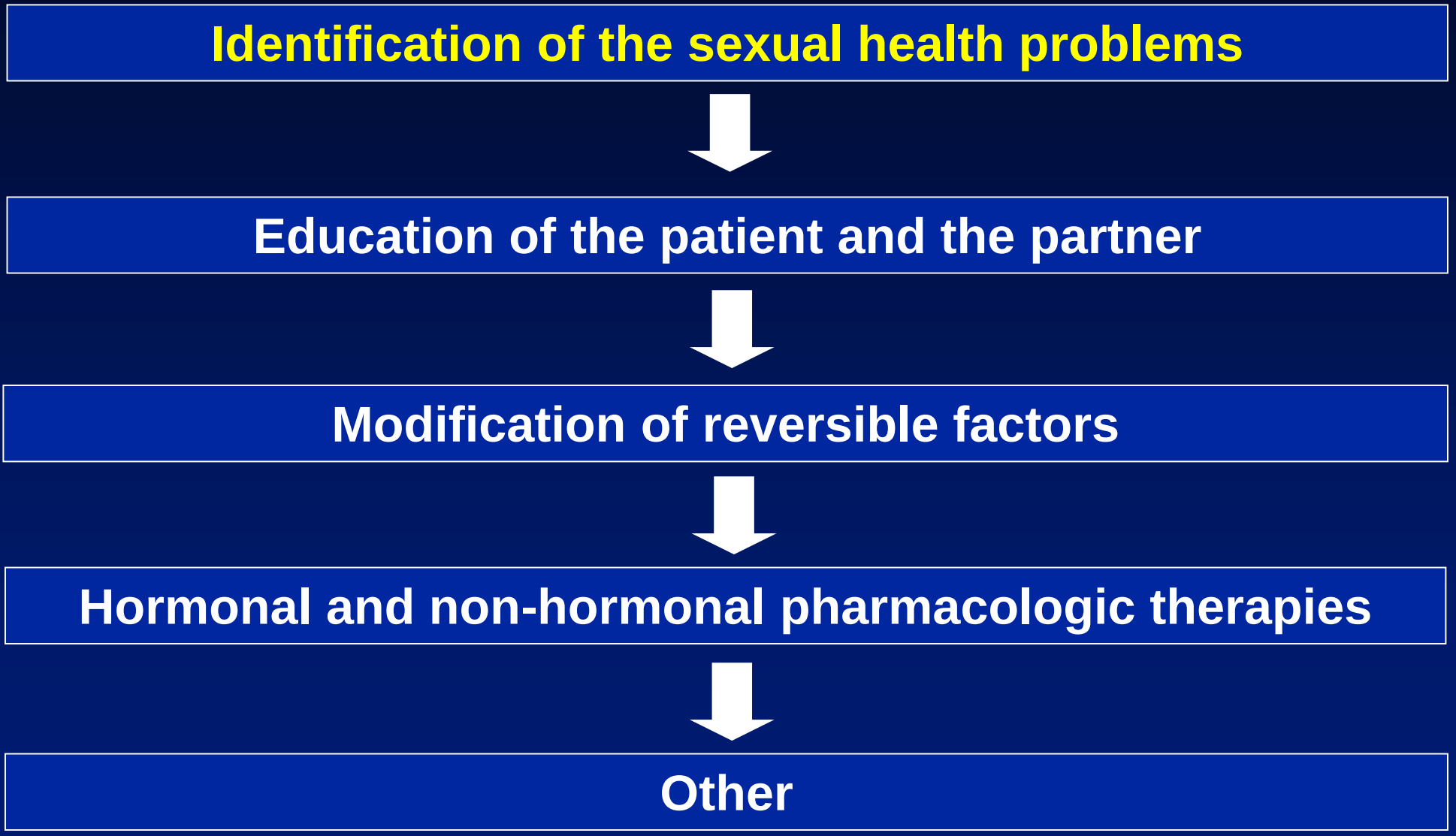

Goldstein I, Alexander JL. Practical aspects in the management of vaginal atrophy and sexual dysfunction in perimenopausal and postmenopausal women. J Sex Med. 2005 Sep;2 Suppl 3:154-65.

There are many “genital” organs involved in women’s sexuality

Genital organ “injury” may have sexual health consequences

Anatomy

G-spot
Clitoris Glans, Clitoral Corona, Clitoral Frenula
Corpora Spongiosa (Vestibular Bulbs)
Clitoris Shaft, Clitoris Crus
Female Prostate, Peri-urethral Tissue
Cervix
Vulva
Vestibule
Vagina
Urethral Meatus/Urethral Glans
Sacral and Lumbar Spinal Cord

G- spot

DOI: 10.1111/1471-0528.12707
www.bjog.org

Verification of the anatomy and newly discovered histology of the G-spot complex*

A Ostrzenski,[a] P Krajewski,[b] P Ganjei-Azar,[c] AJ Wasiutynski,[d] MN Scheinberg,[e] S Tarka,[b] M Fudalej[b]

[a] Institute of Gynecology Inc., St Petersburg, FL, USA [b] The Department of Forensic Medicine, Warsaw Medical University, Warsaw, Poland [c] The Department of Pathology, University of Miami, FL, USA [d] The Department of Pathomorphology, Warsaw Medical University, Warsaw, Poland [e] Center for Cosmetic & Reconstructive Gynecology, Deerfield Beach, FL, USA
Correspondence: Prof. Dr. A Ostrzenski, Institute of Gynecology Inc., 7001 Central Avenue, St Petersburg, FL 33710, USA. Email ao@baymedical.com

Accepted 23 October 2013. Published Online 19 March 2014.

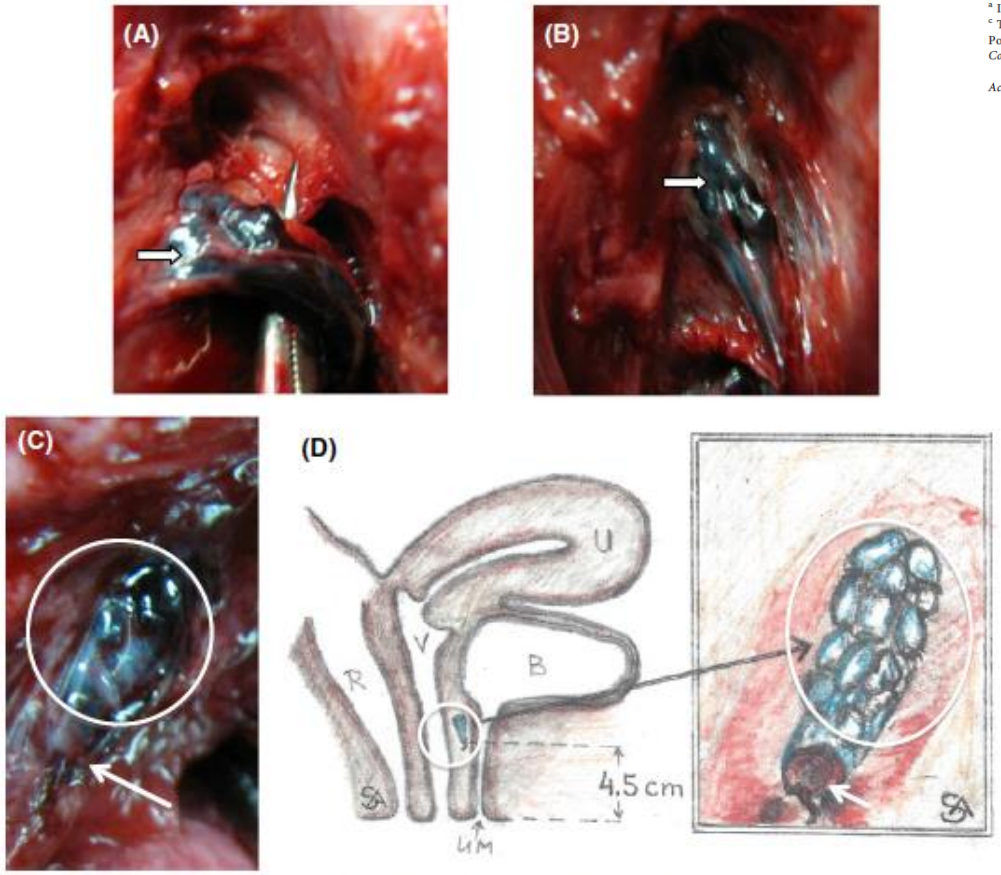

Figure 1. Gross anatomical views of the G-spot and surrounding distended vessels. (A) The G-spot sac is opened and G-spot (the white arrow) with surrounding vessels resembling a blue grape-like cluster structure above the instrument is depicted. (B) The vascular bundle migrates into the distal part of the G-spot. The wall of the G-spot sac is visible under the arrowhead. (C) A sagittal close-up view of the G-spot complex is presented. The tail of the G-spot is depicted (the arrow). The rope-like vascular structure protrudes from the G-spot tail (the arrow). The pink colour of the G-spot (arrow) distinguishes this structure from th surrounding vessels, which appear dark blue and are filled with retained blood (the white circle). (D) The left side of the diagram is an illustration of the location of the G-spot complex, which is embedded within the vaginal wall (the white circle) (U, uterus; V, vagina; B, bladder; UM, urethral meatus; R, rectum). On the right, the G-spot complex is presented. The arrow indicates the tail of the G-spot and the white circle encompasses the fused vessels with the G-spot structure.

G- spot

Mechanical distortion of the anterior vaginal wall can stimulate more erotogenic structures than comparable distortion of the lateral or posterior vaginal walls

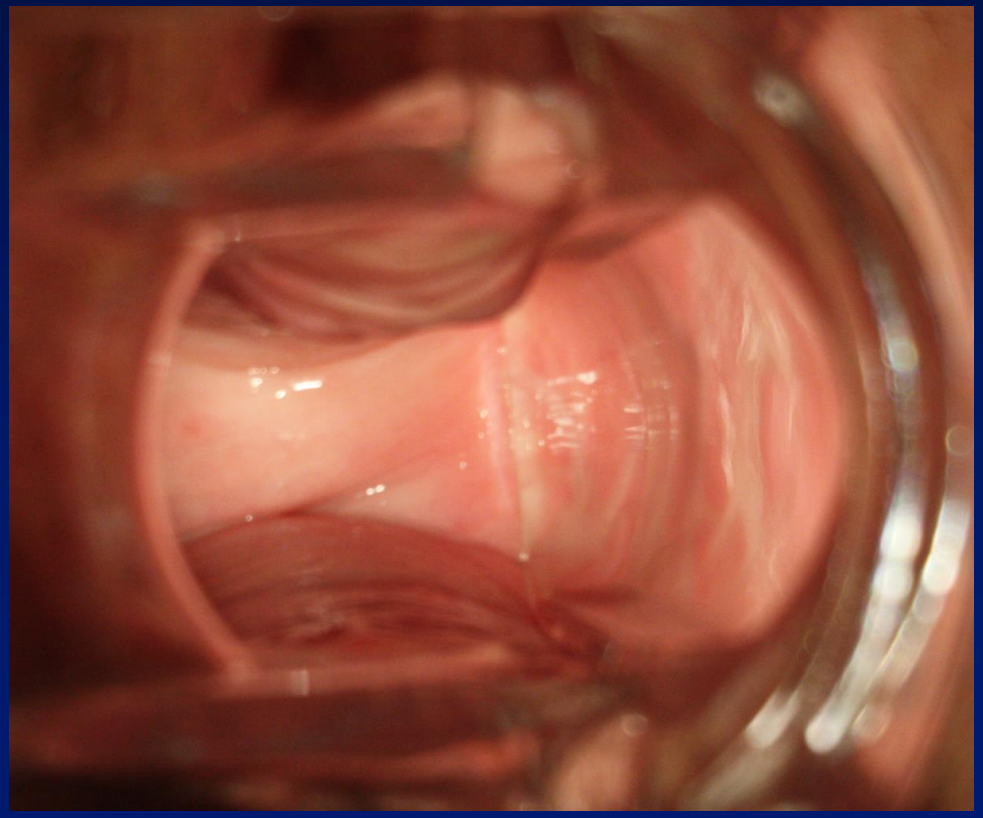

MRI image (axial) WITH gel opacification of vagina

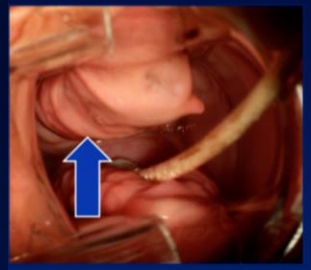

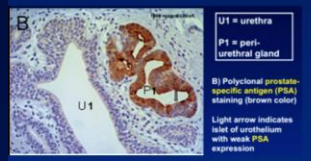

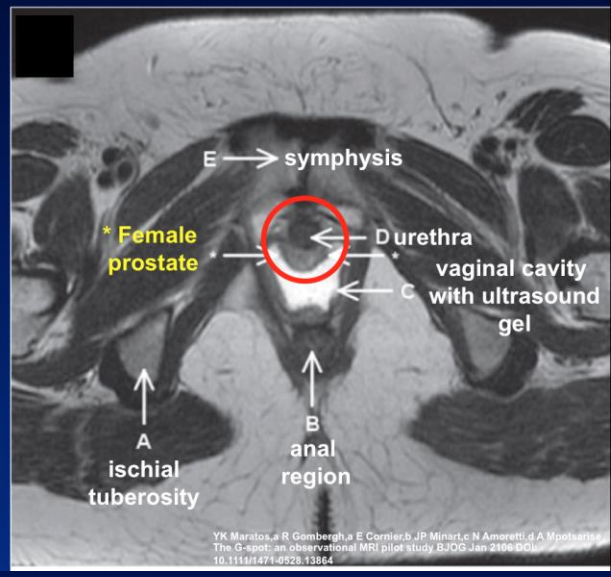

Relationship Among: Clitoral Crus, Clitoral Glans, Corpora Spongiosa, Urethra, Urethral Meatus/Urethral Glans, Female Prostate, Vestibule, Vagina, Bartholin Glands

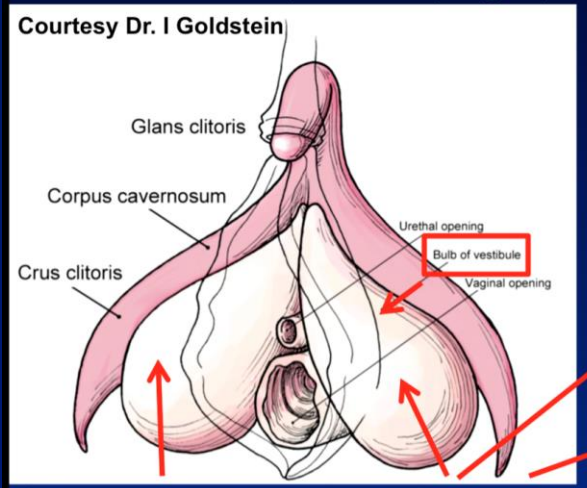

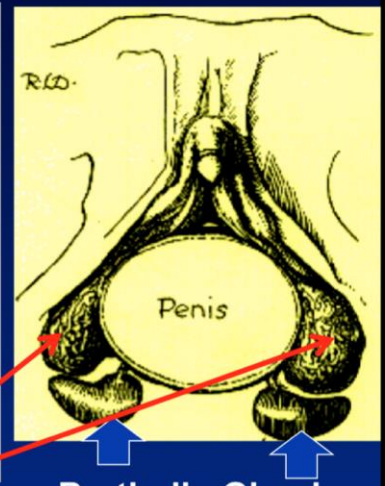

G- spot

Pushing on the anterior vaginal wall can stimulate in addition, the crura of the clitoris and bulbs of the vestibule, plus the female prostate plus the urethra, and urethral glans, which would be different from distorting the lateral or posterior vaginal walls.

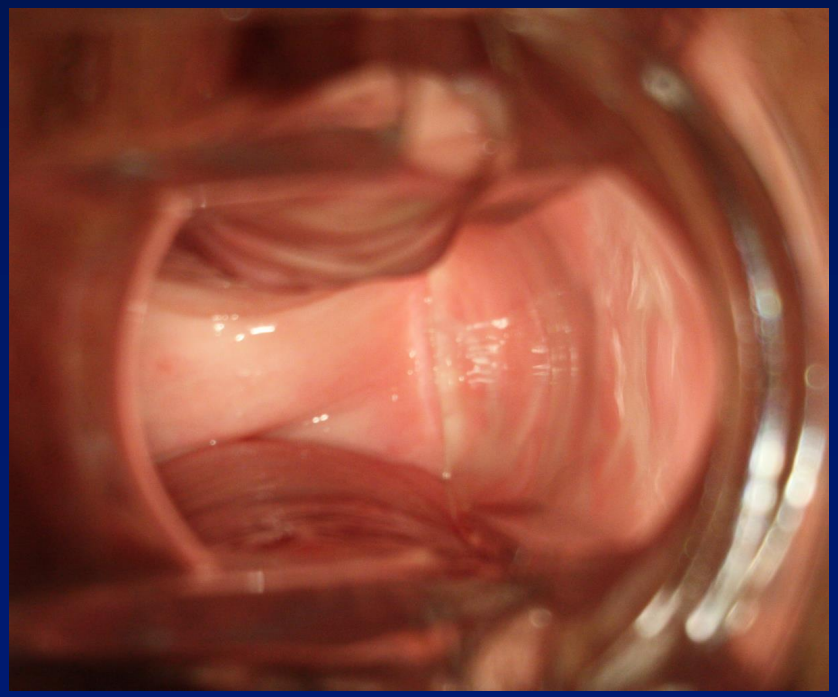

MRI image (axial) WITH gel opacification of vagina

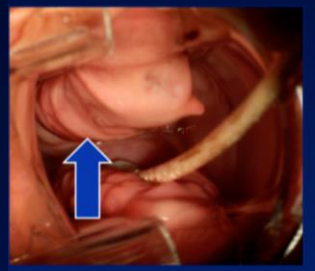

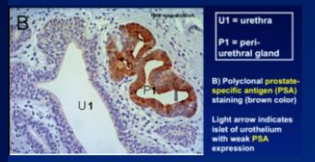

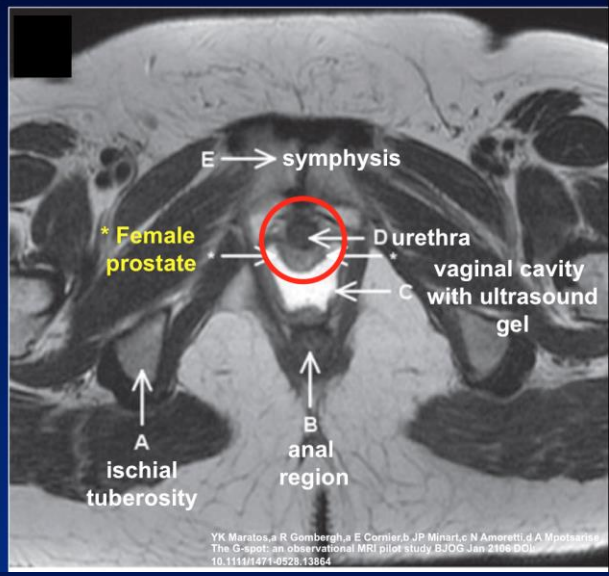

Relationship Among: Clitoral Crus, Clitoral Glans, Corpora Spongiosa, Urethra, Urethral Meatus/Urethral Glans, Female Prostate, Vestibule, Vagina, Bartholin Glands

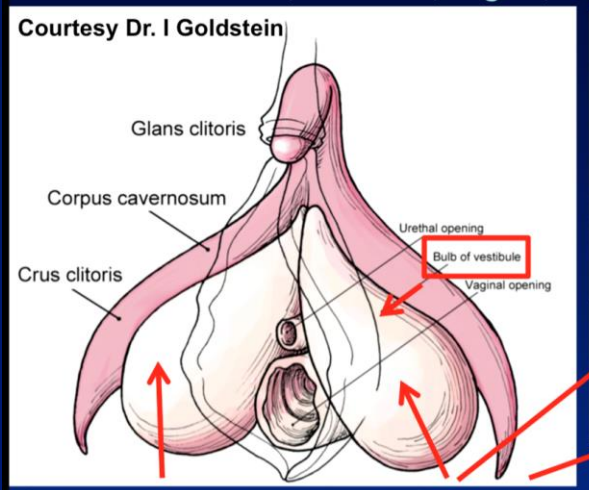

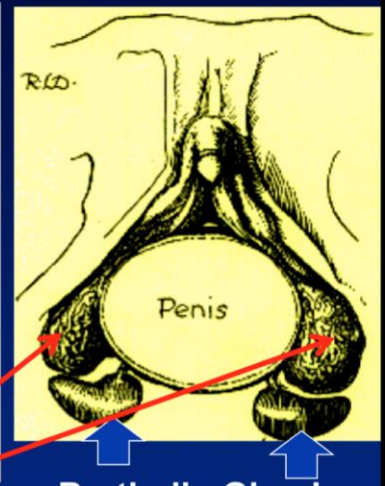

G- spot

With that consideration, the "G-spot" might be more of an anatomical nexus of multiple erotogenic regions all of which are stimulated jointly by mechanical distortion, than a distinct 'structure'

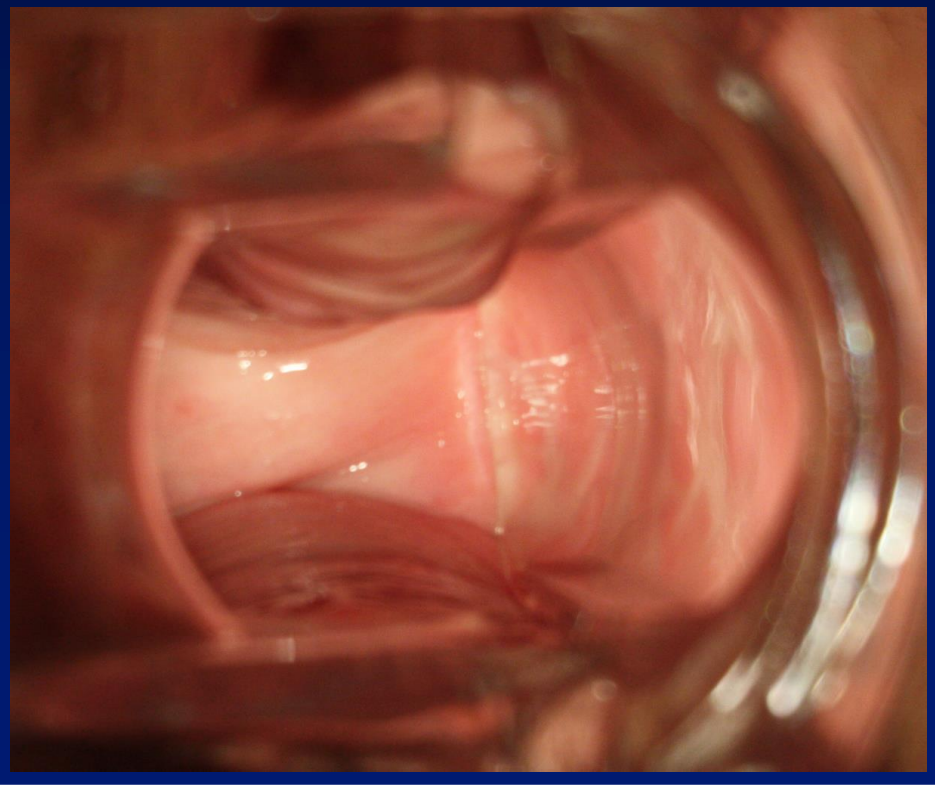

MRI image (axial) WITH gel opacification of vagina

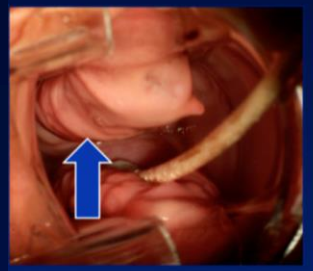

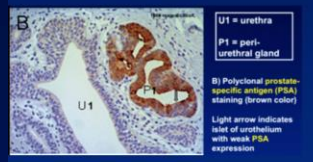

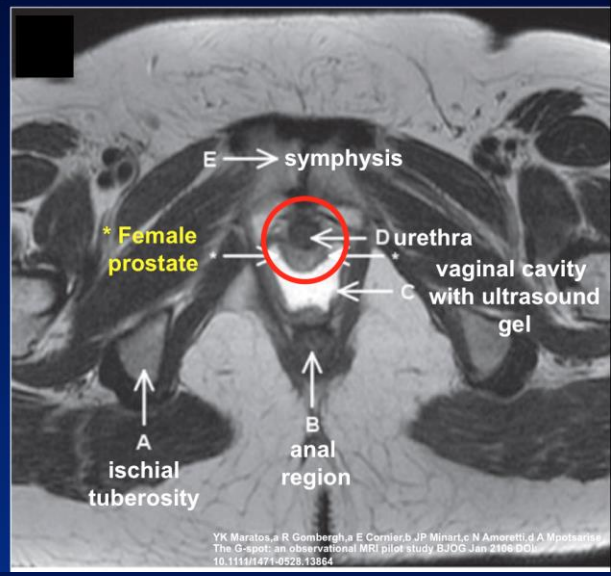

Relationship Among: Clitoral Crus, Clitoral Glans, Corpora Spongiosa, Urethra, Urethral Meatus/Urethral Glans, Female Prostate, Vestibule, Vagina, Bartholin Glands

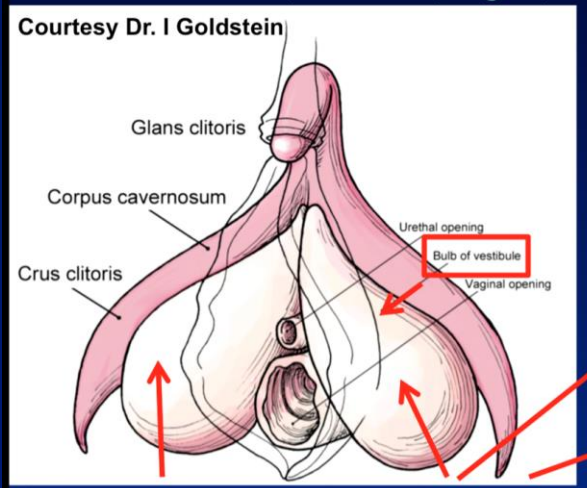

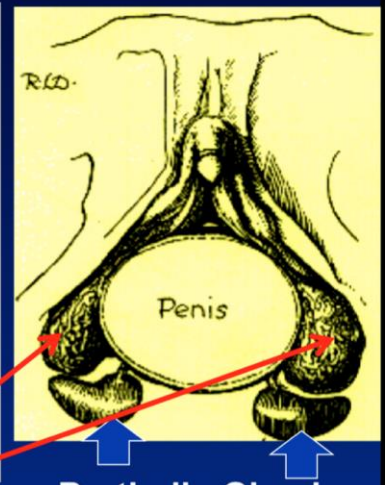

Anatomy

G-spot
Clitoris Glans, Clitoral Corona, Clitoral Frenula
Corpora Spongiosa (Vestibular Bulbs)
Clitoris Shaft, Clitoris Crus
Female Prostate, Peri-urethral Tissue
Cervix
Vulva
Vestibule
Vagina
Urethral Meatus/Urethral Glans
Sacral and Lumbar Spinal Cord

Clitoral Glans, Frenula, Corona

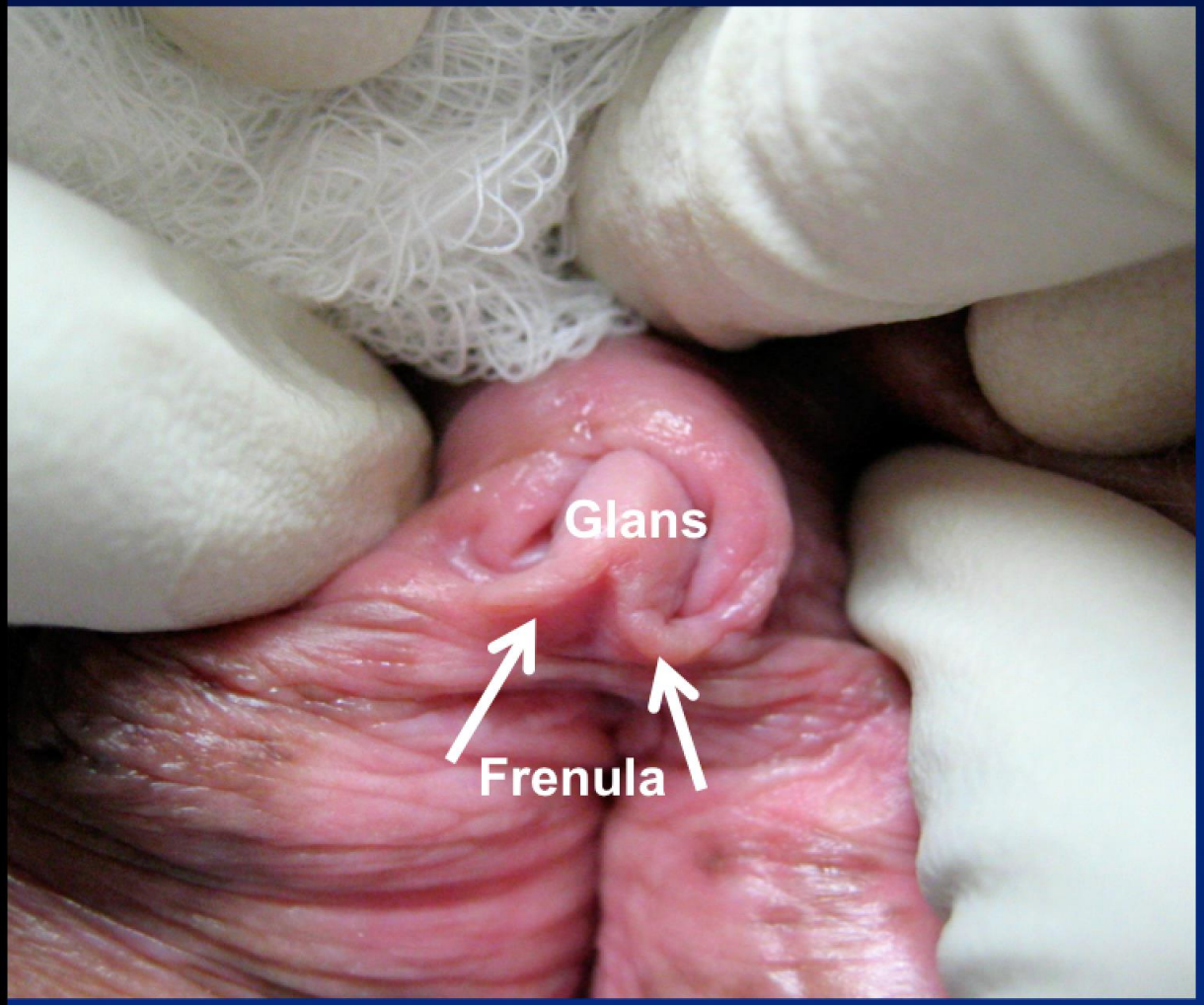

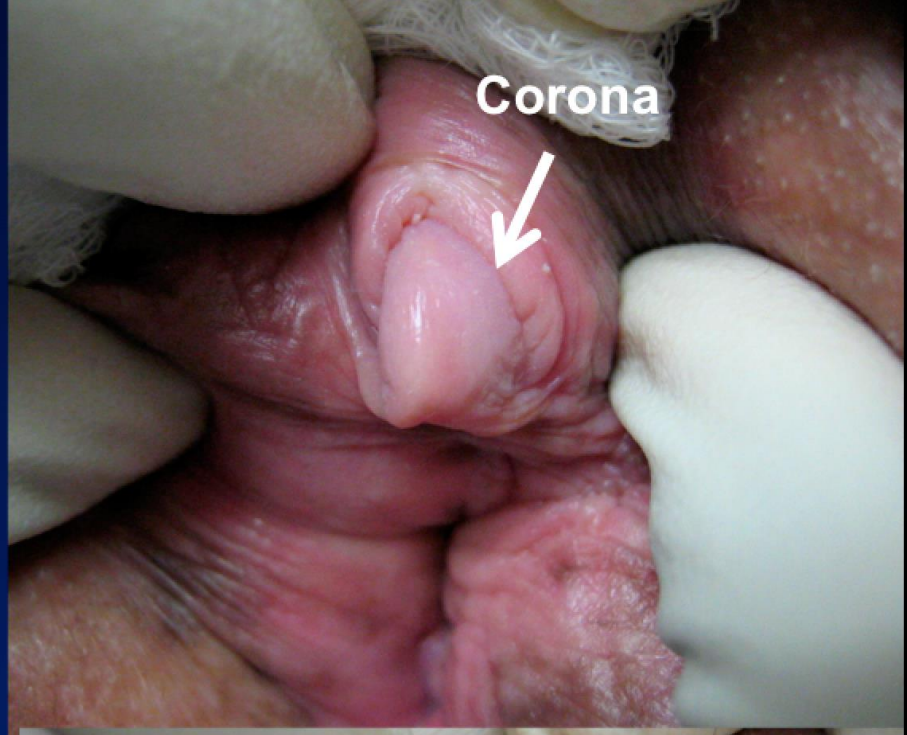

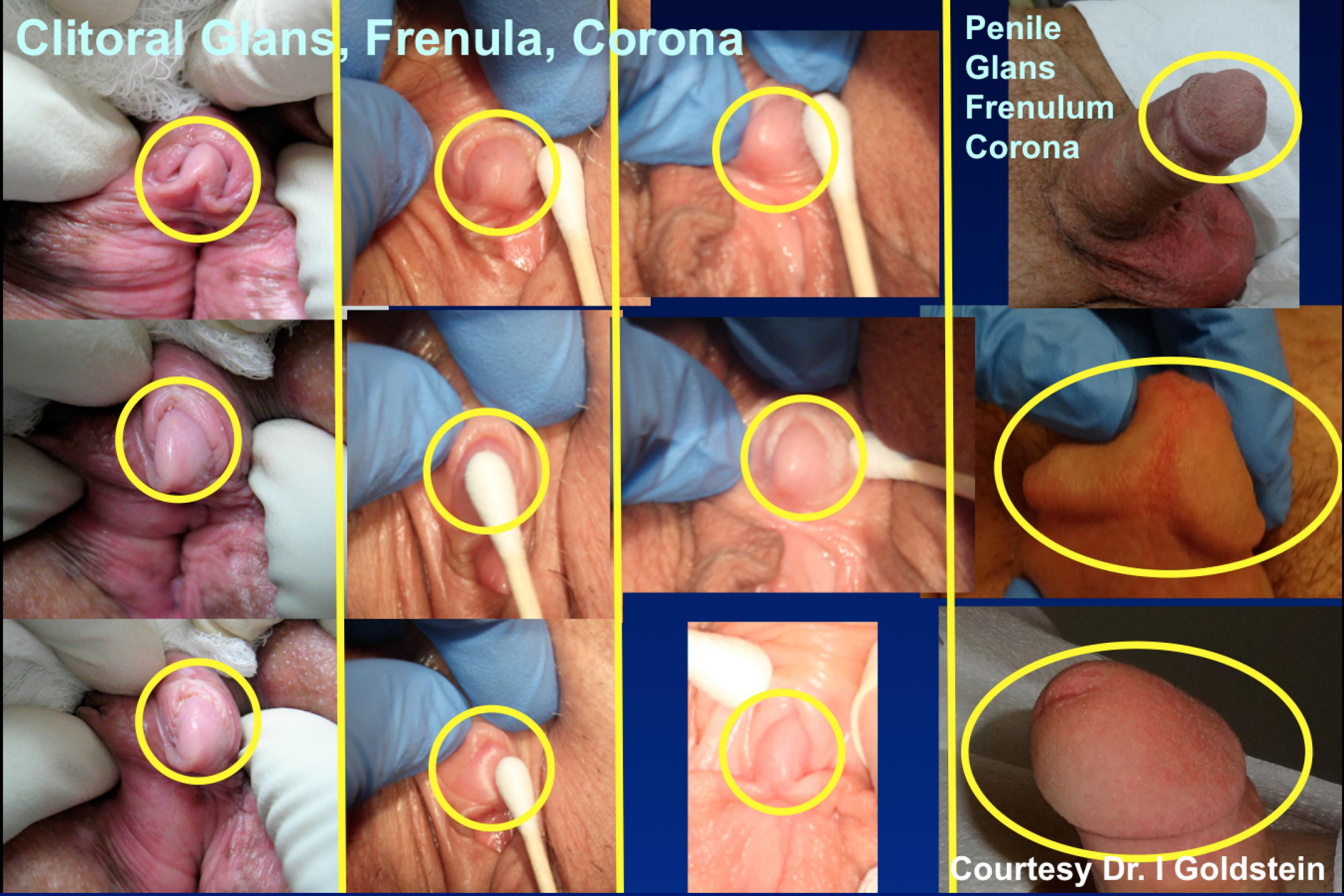
Clitoral Glans, Frenula, Corona
Penile
Glans
Frenulum
Corona
Courtesy Dr. I Goldstein

Failure to Visualize Clitoral Corona

Failure to Visualize Penile Corona

Courtesy Dr. I Goldstein

Anatomy

G-spot
Clitoris Glans, Clitoral Corona, Clitoral Frenula
Corpora Spongiosa (Vestibular Bulbs)
Clitoris Shaft, Clitoris Crus
Female Prostate, Peri-urethral Tissue
Cervix
Vulva
Vestibule
Vagina
Urethral Meatus/Urethral Glans
Sacral and Lumbar Spinal Cord

Relationship Among: Clitoral Crus, Clitoral Glans, Corpora Spongiosa, Urethra, Urethral Meatus/Urethral Glans, Female Prostate, Vestibule, Vagina, Bartholin Glands

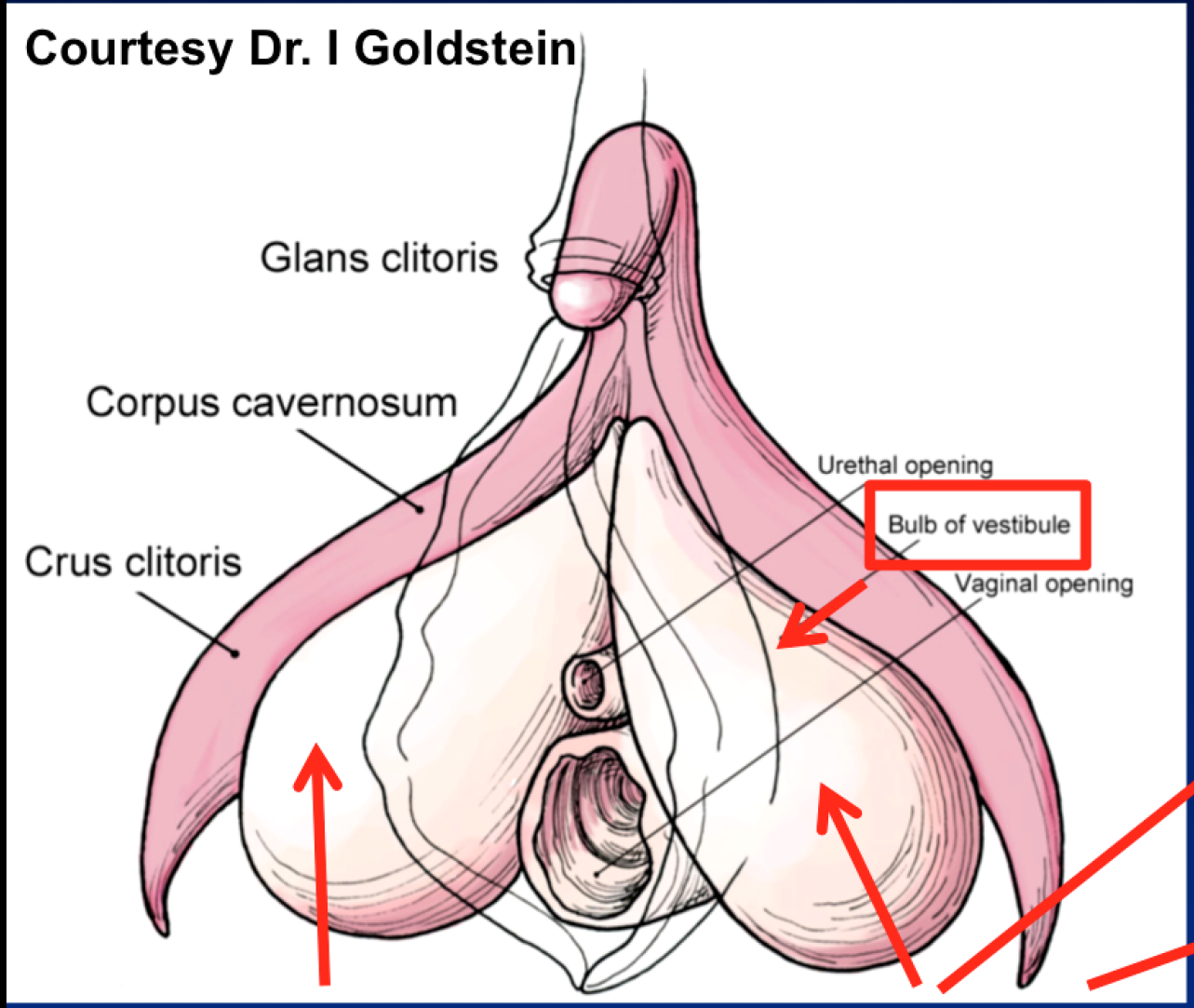

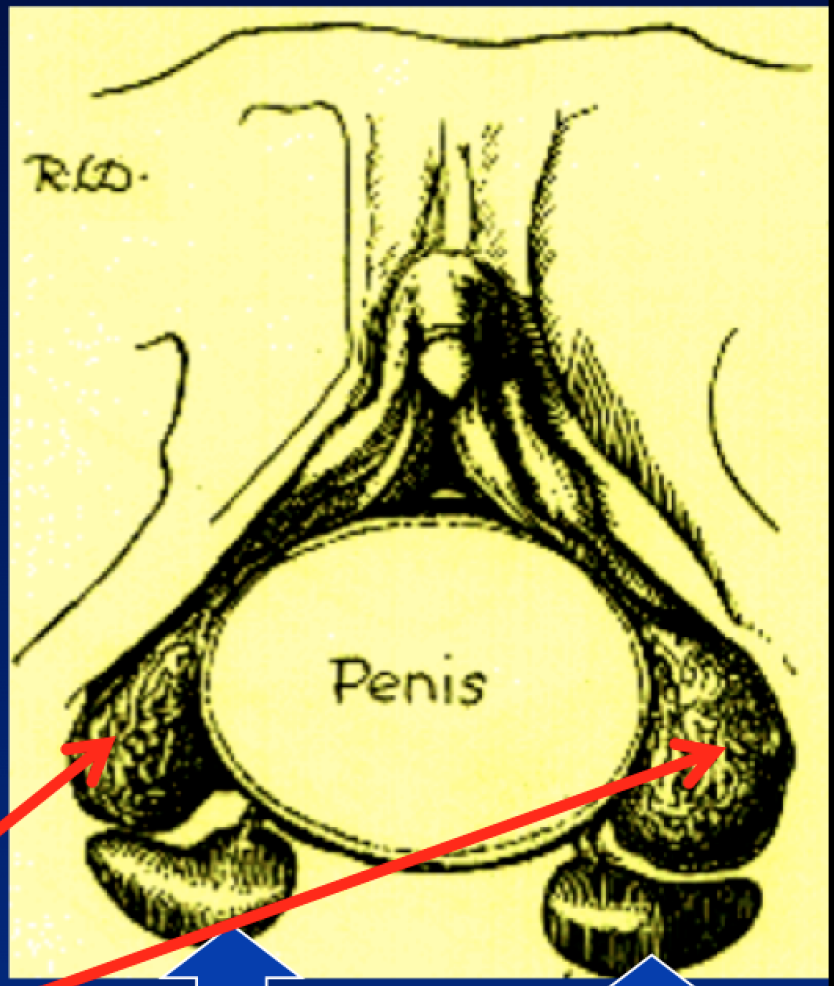

Corpora Spongiosa – Bulb of Vestibule

Bartholin Glands

Corpus Spongiosum, Bartholin Gland

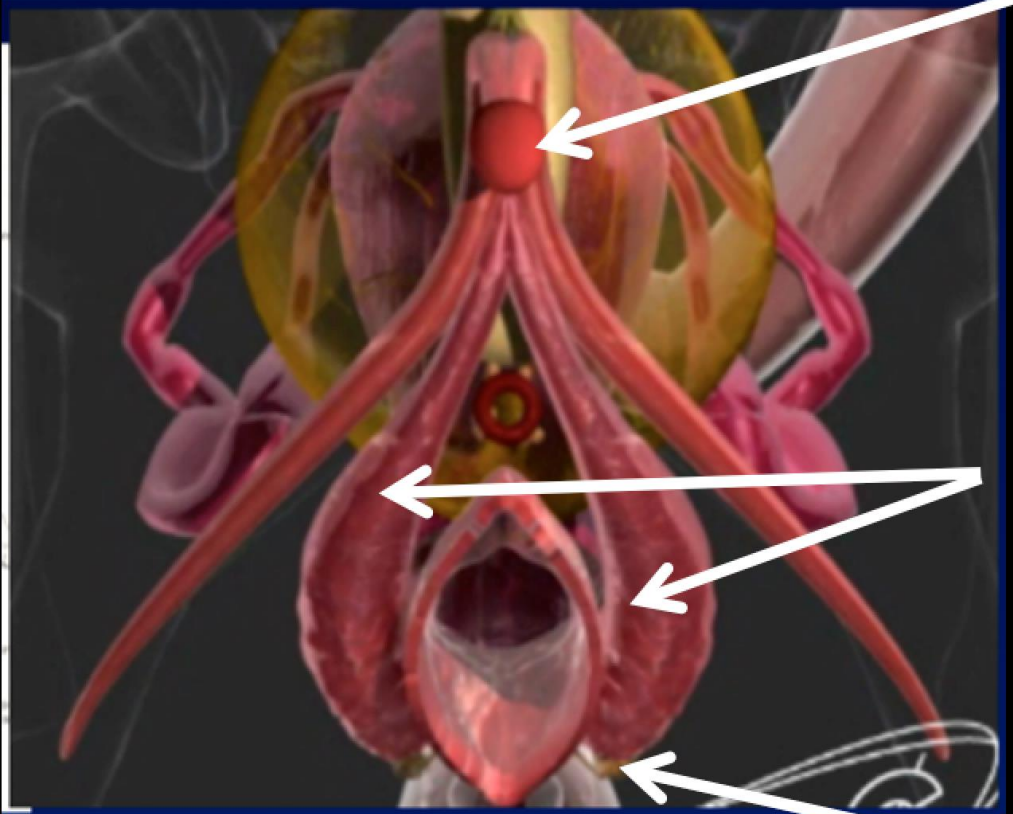

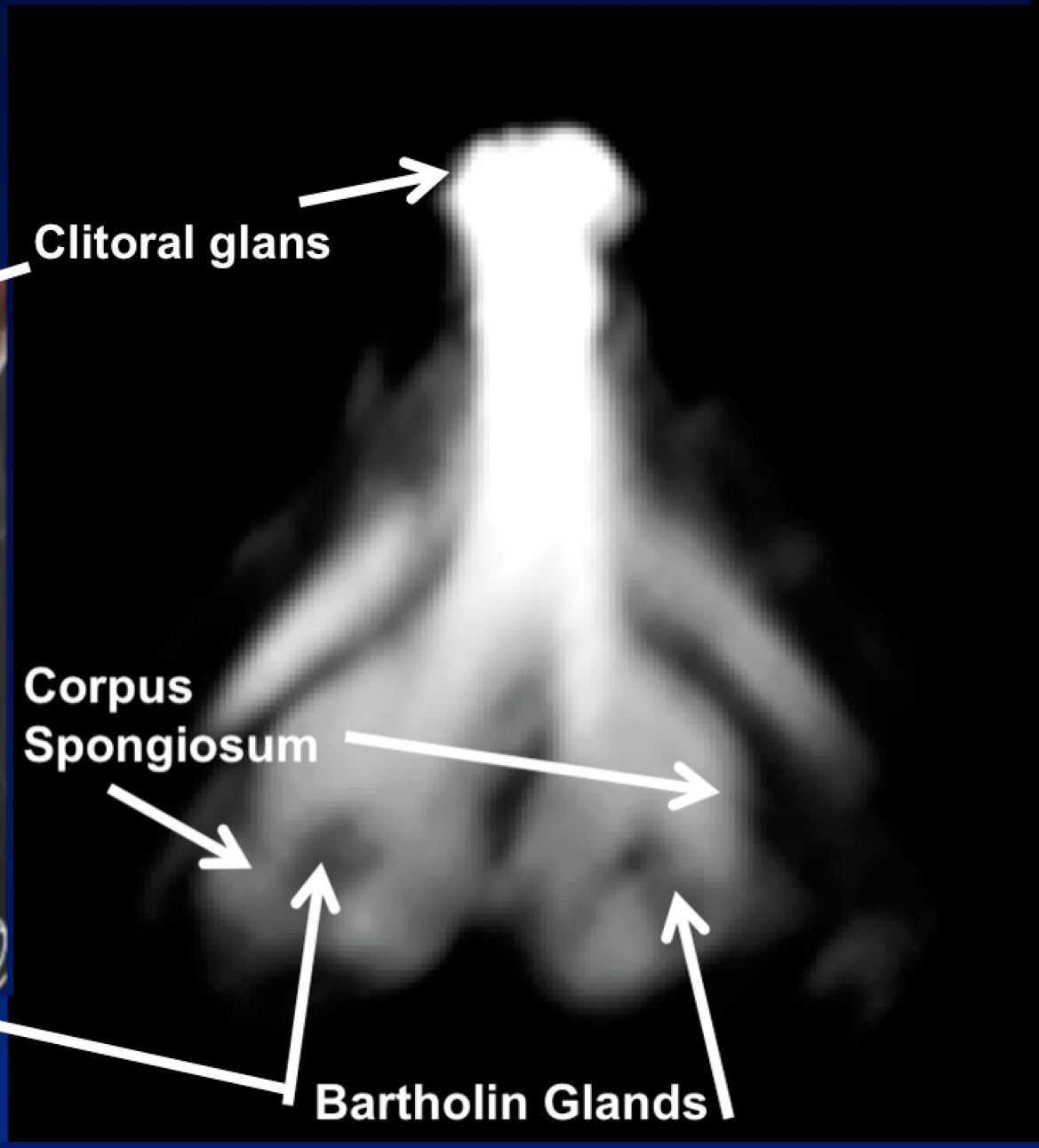

Courtesy Dr. I Goldstein

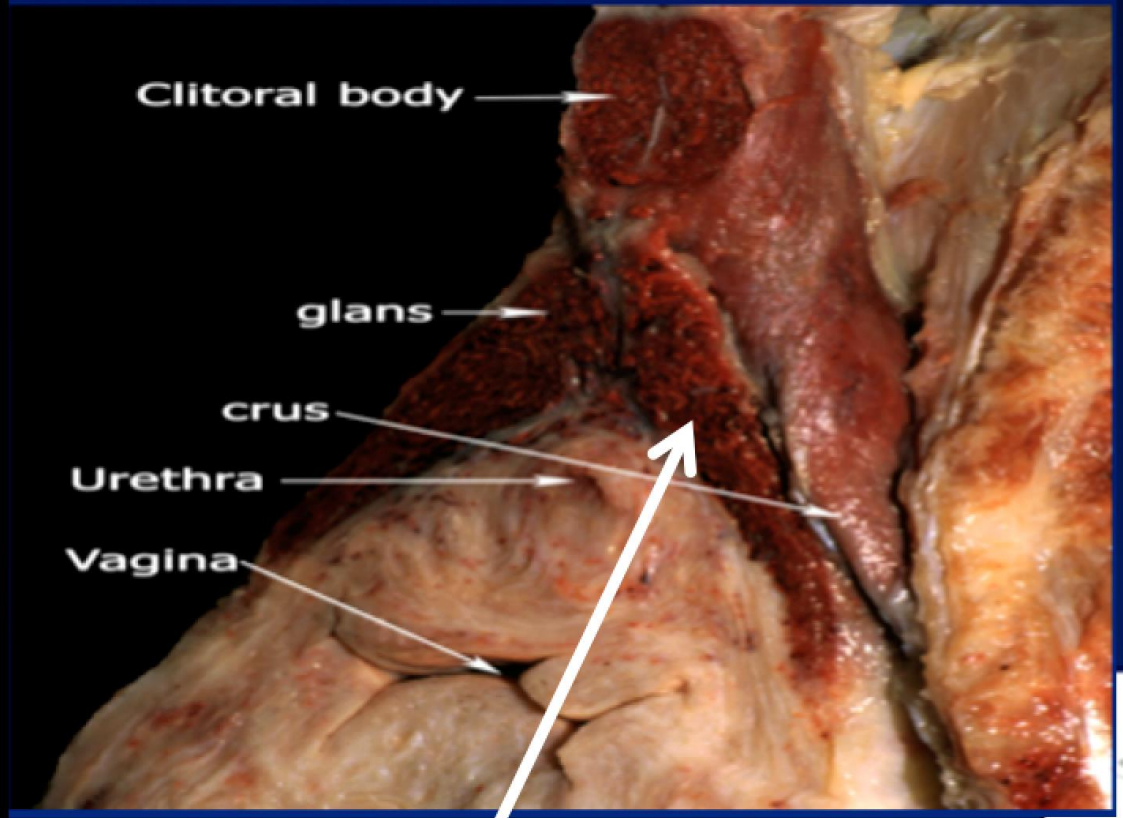

Corpus spongiosum or bulb of vestibule

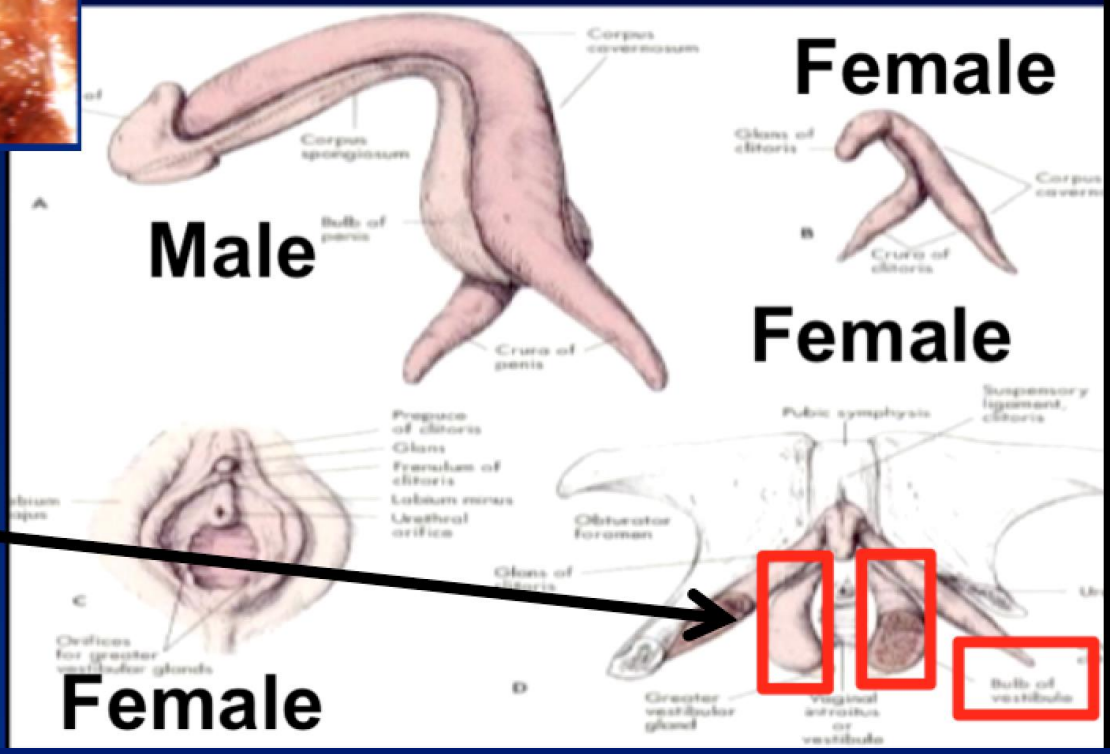

Corpus spongiosum or bulb of vestibule

Courtesy Dr. I Goldstein

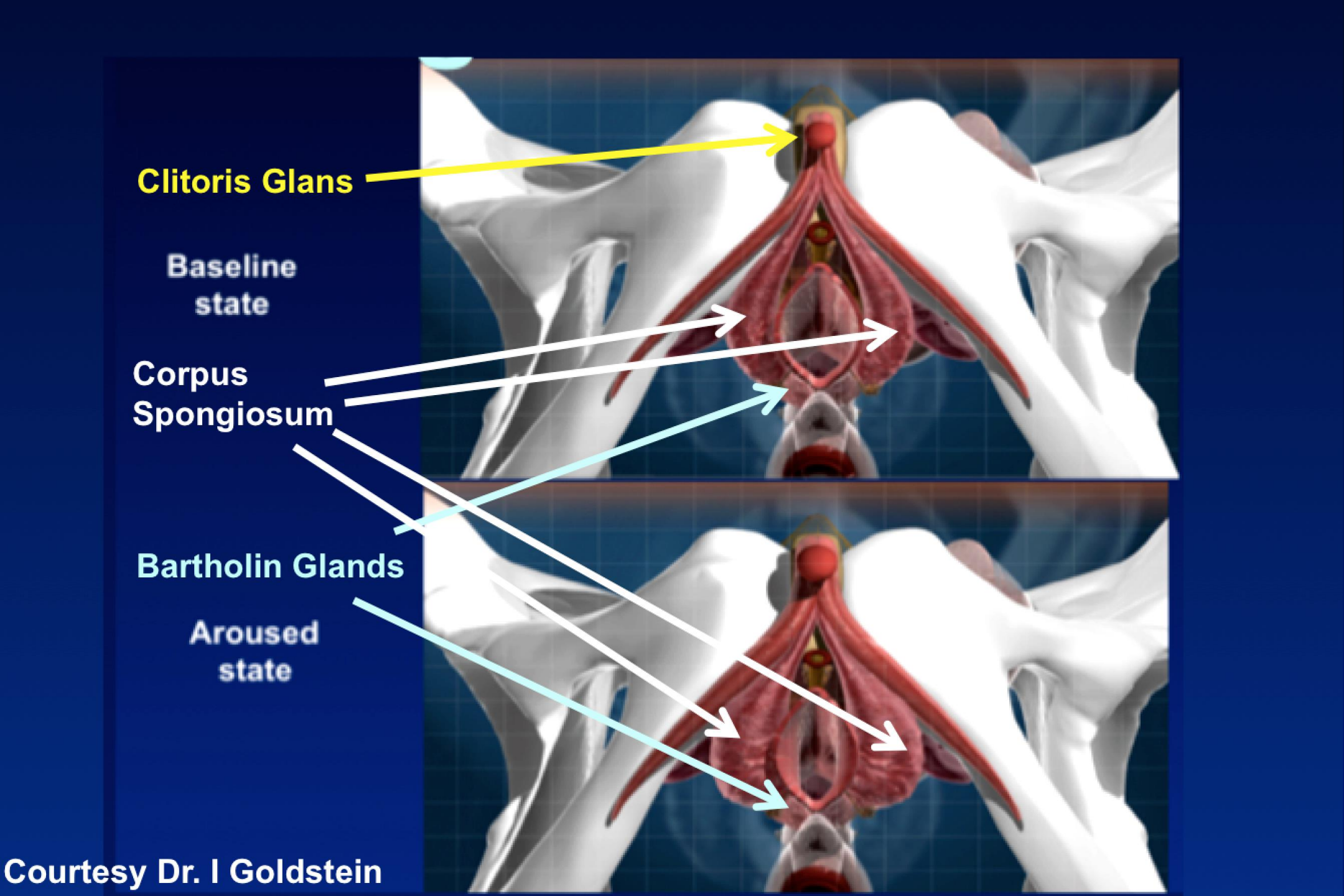
Clitoris Glans
Baseline state
Corpus Spongiosum
Bartholin Glands
Aroused state
Courtesy Dr. I Goldstein

Anatomy

G-spot
Clitoris Glans, Clitoral Corona, Clitoral Frenula
Corpora Spongiosa (Vestibular Bulbs)
Clitoris Shaft, Clitoris Crus
Female Prostate, Peri-urethral Tissue
Cervix
Vulva
Vestibule
Vagina
Urethral Meatus/Urethral Glans
Sacral and Lumbar Spinal Cord

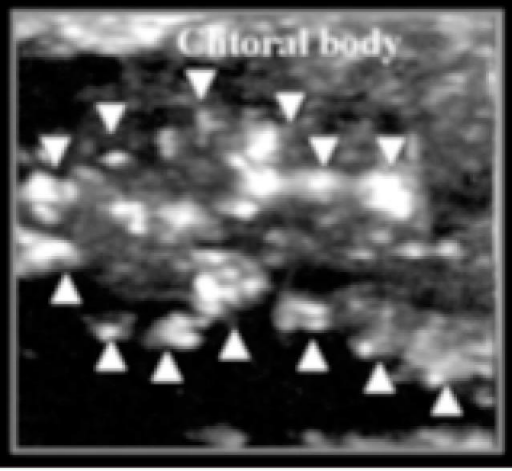

Ultrasonographic and Doppler Findings of Subclinical Clitoral Microtraumatisms in Mountain Bikers and Horseback Riders

Cesare Battaglia, MD, PhD,* Rossella Elena Nappi, MD,† Fulvia Mancini, MD, PhD,* Arianna Cianciosi, MD,* Nicola Persico, MD,* and Paolo Busacchi, MD*

*Department of Obstetrics and Gynaecology, University of Bologna, Bologna, Italy; †Department of Obstetrics and Gynaecology, University of Pavia Research Centre for Reproductive Medicine, Pavia, Italy

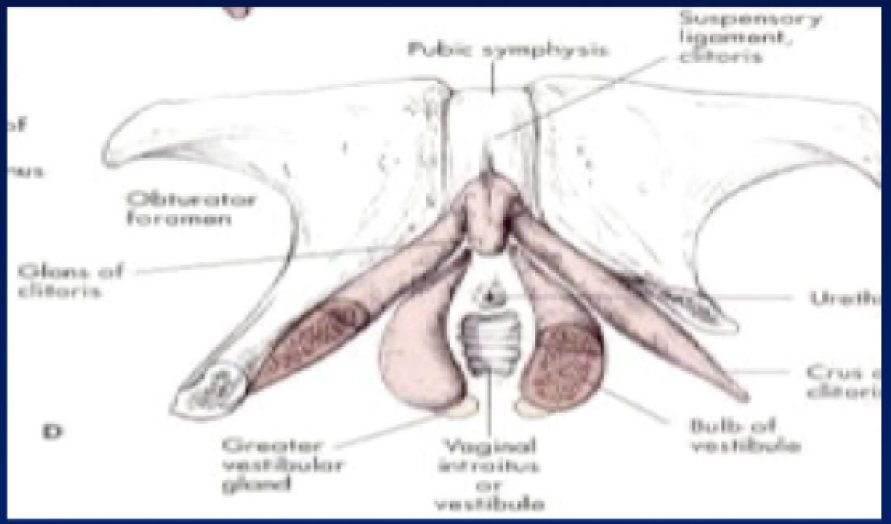

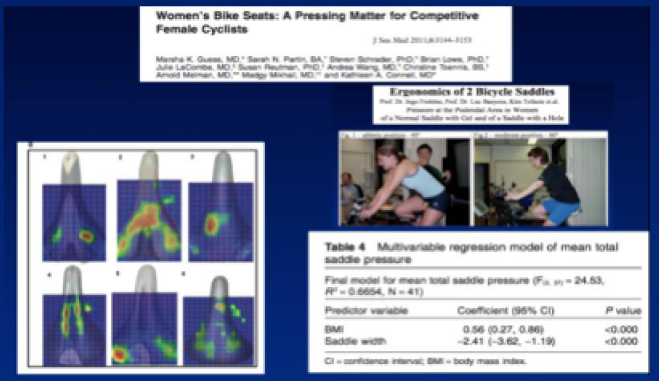

J Sex Med 2009;6:464–468

Clitoral Priapism

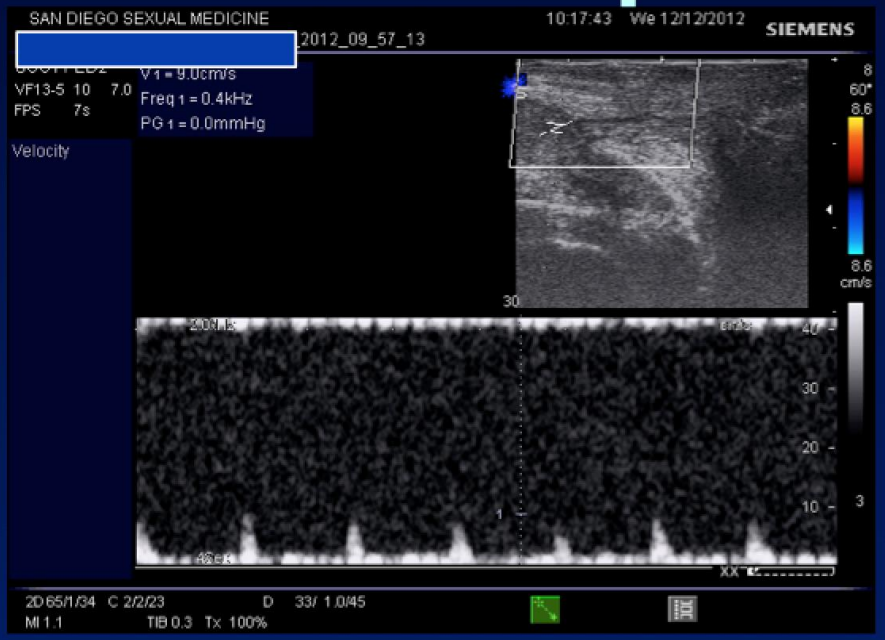

Clitoral Priapism

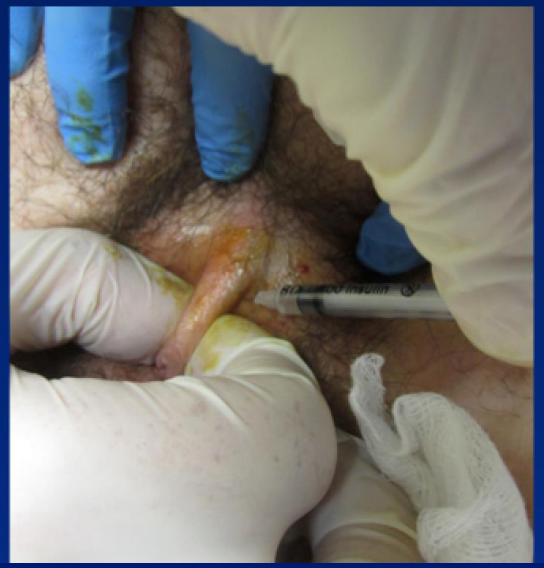

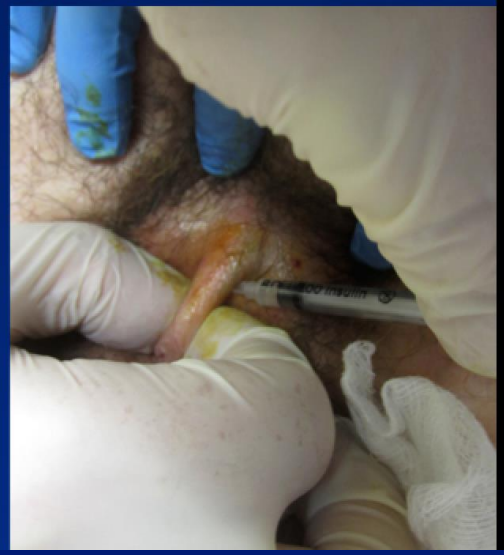

Modified Corporal Glanular Shunt with Corporal Snake Maneuver

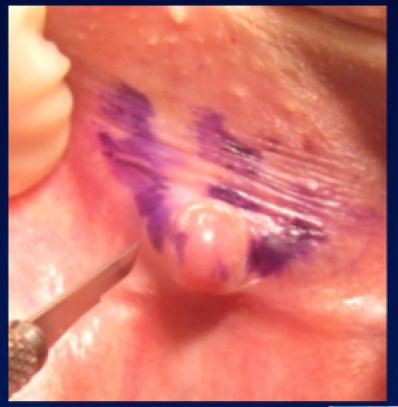
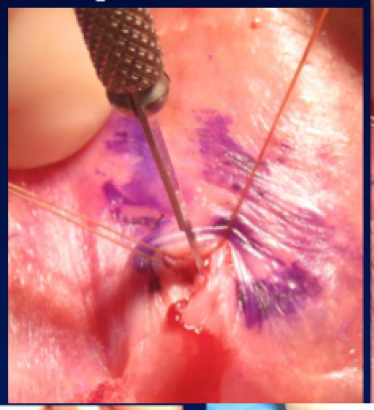

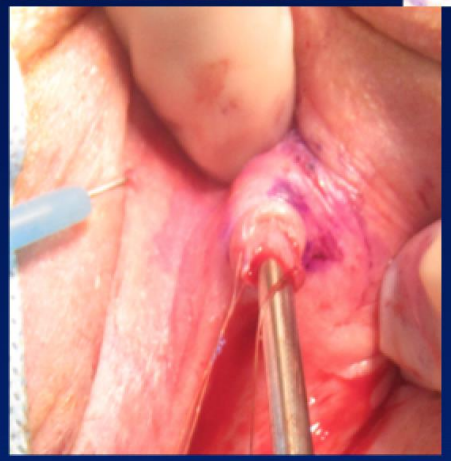
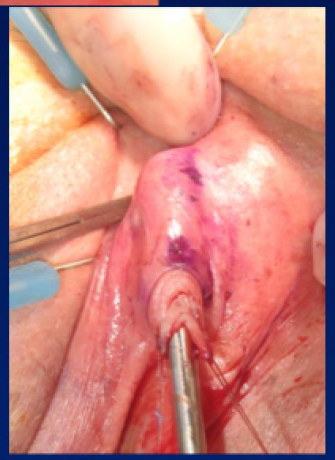

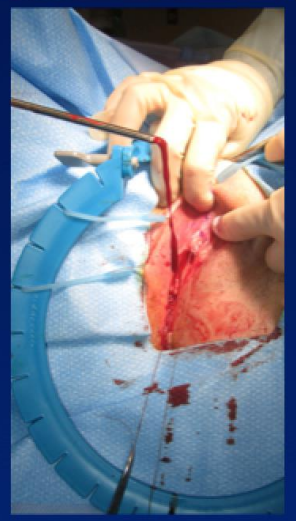

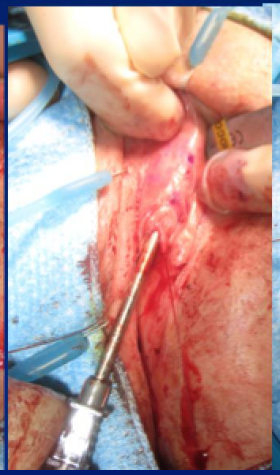

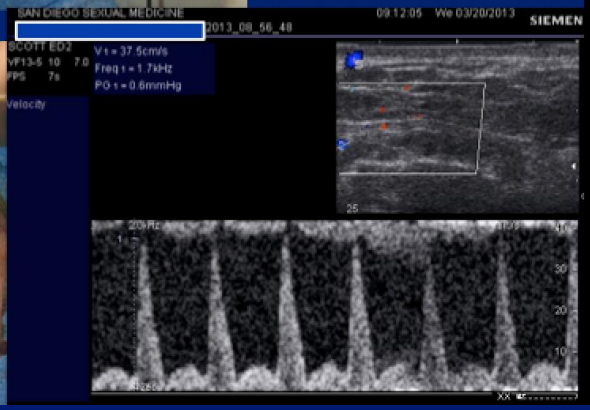

Anatomy

G-spot
Clitoris Glans, Clitoral Corona, Clitoral Frenula
Corpora Spongiosa (Vestibular Bulbs)
Clitoris Shaft, Clitoris Crus
Female Prostate, Peri-urethral Tissue
Cervix
Vulva
Vestibule
Vagina
Urethral Meatus/Urethral Glans
Sacral and Lumbar Spinal Cord

Anatomy – Female Prostate

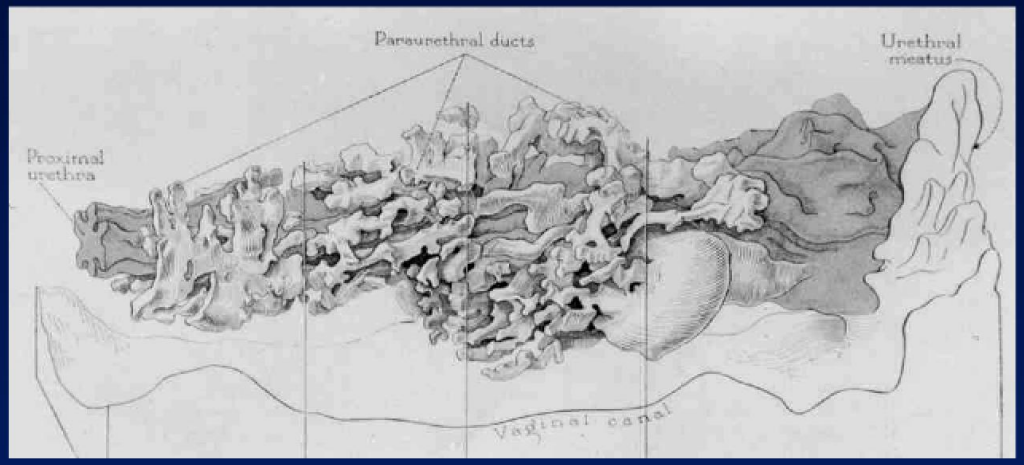

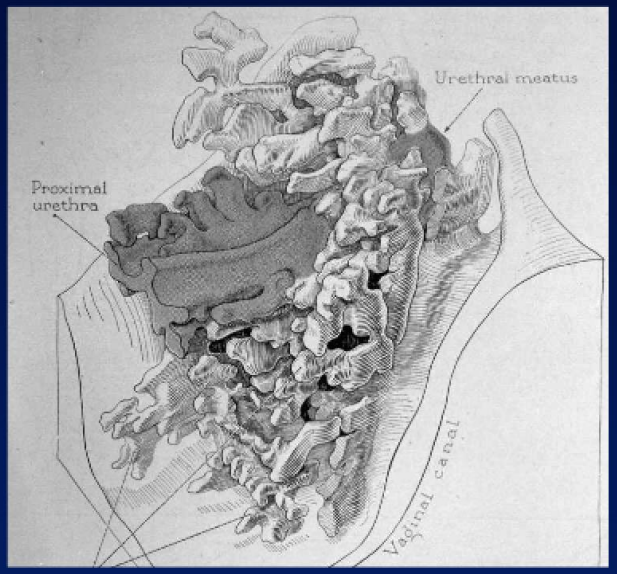

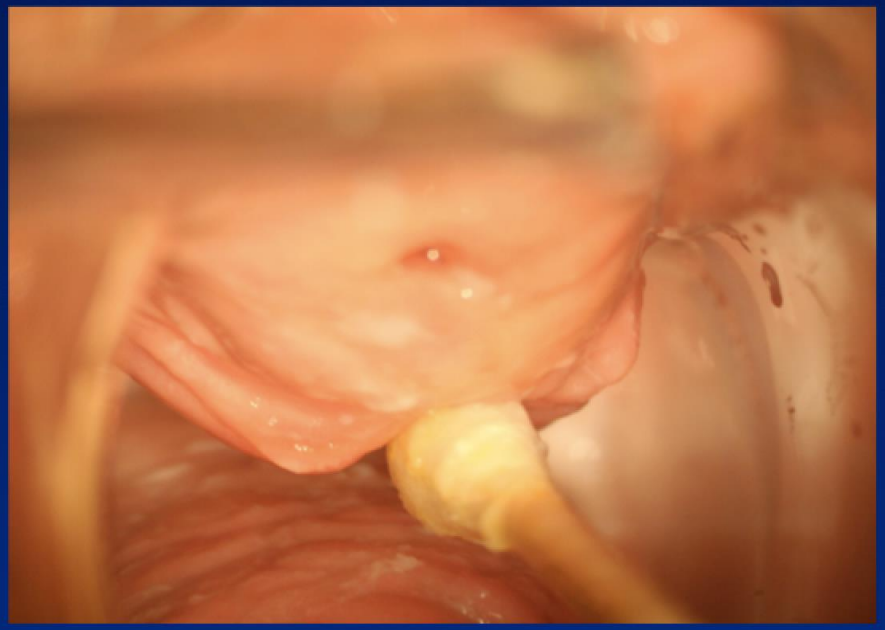



Buisson O, Foldes P, Jannini E, Mimoun S. Coitus as revealed by ultrasound in one volunteer couple. J Sex Med. 2010 Aug;7(8):2750-4.
Foldes P, Buisson O. The clitoral complex: a dynamic sonographic study. J Sex Med. 2009 May;6(5):1223-31.
Wimpissinger F, Tscherney R, Stackl W. Magnetic resonance imaging of female prostate pathology. J Sex Med. 2009 Jun;6(6):1704-11.
Wimpissinger F, Stifter K, Grin W, Stackl W. The female prostate revisited: perineal ultrasound and biochemical studies of female ejaculate. J Sex Med. 2007 Sep;4(5):1388-93;

Anatomy – Female Prostate

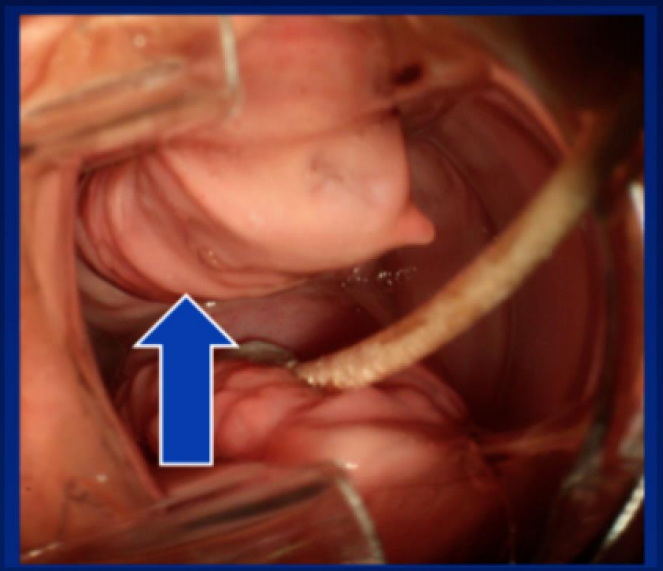

Dietrich W, Susani M, Stifter L, and Haitel A. The human female prostate—immunohistochemical study with prostate-specific antigen, prostate-specific alkaline phosphatase, and androgen receptor and 3-D remodeling. J Sex Med 2011;8:2816–2821

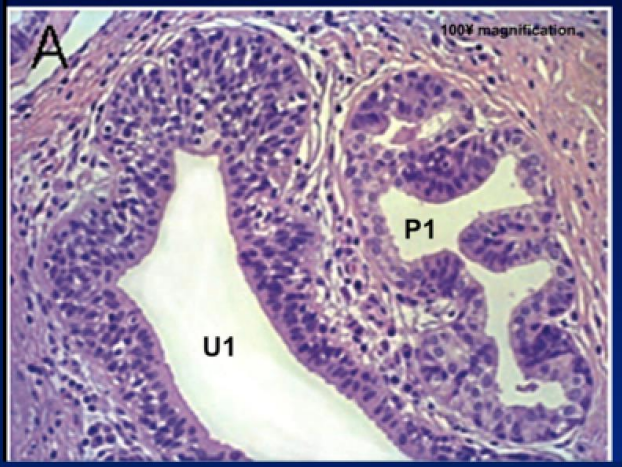

U1 = urethra

P1 = peri-urethral gland

A) Hematoxylin-eosin staining of urethra and peri-urethral glandular structure suspected to be female prostate

Dietrich W, Susani M, Stifter L, and Haitel A. The human female prostate—immunohistochemical study with prostate-specific antigen, prostate-specific alkaline phosphatase, and androgen receptor and 3-D remodeling. J Sex Med 2011;8:2816–2821

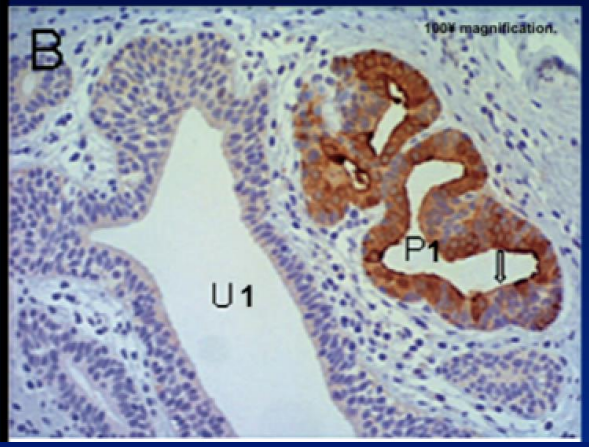

U1 = urethra

P1 = peri-urethral gland

B) Polyclonal prostate-specific antigen (PSA) staining (brown color)

Light arrow indicates islet of urothelium with weak PSA expression

Dietrich W, Susani M, Stifter L, and Haitel A. The human female prostate—immunohistochemical study with prostate-specific antigen, prostate-specific alkaline phosphatase, and androgen receptor and 3-D remodeling. J Sex Med 2011;8:2816–2821

U1 = urethra

P1 = peri-urethral gland

C) monoclonal PSA staining (brown color), thick arrow indicates strong apical cytoplasmic accumulation of PSA, light arrow indicates islet of urothelium with weak PSA expression

Female Prostate

In women with stress incontinence, surgical placement of a sub-urethral sling will directly injure anterior vaginal wall, peri-urethral female prostatic tissue.

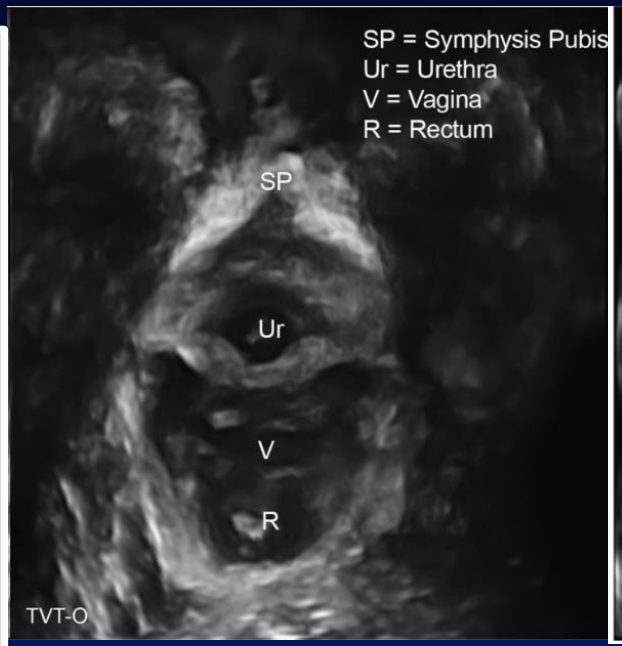

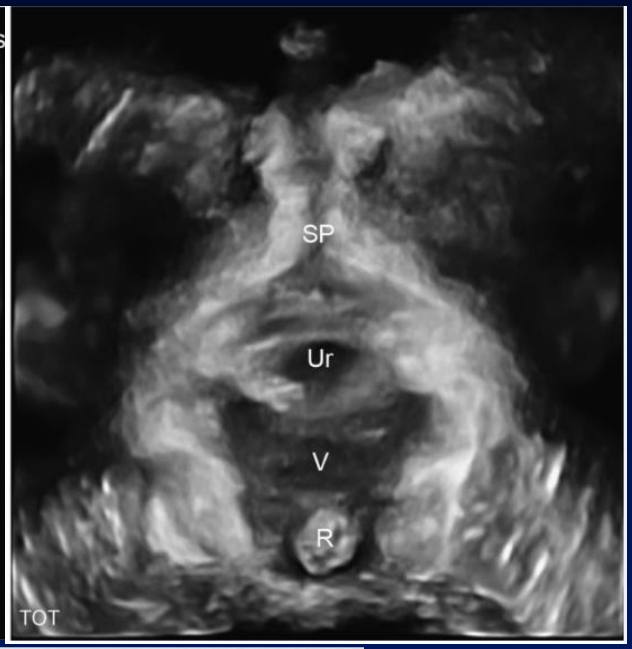

Tunitsky-Bitton, Elena MD et al "Ultrasound Evaluation of Midurethral Sling Position and Correlation to Physical Examination and Patient Symptoms". *Female Pelvic Medicine and Reconstructive Surgery* 2015; 00: 1-6

MRI image (axial) without gel opacification of vagina

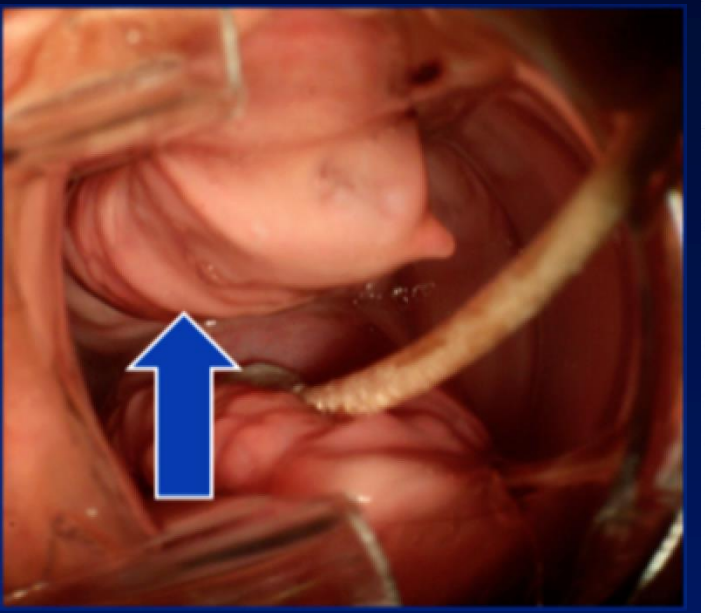

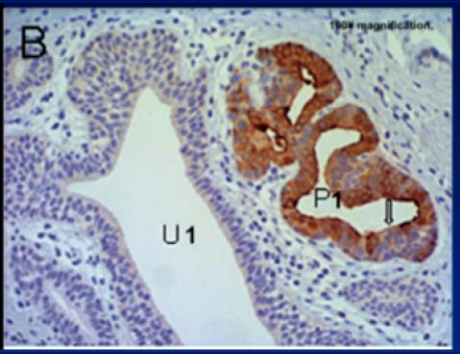

U1 = urethra

P1 = peri-urethral gland

B) Polyclonal prostate-specific antigen (PSA) staining (brown color)

Light arrow indicates islet of urothelium with weak PSA expression

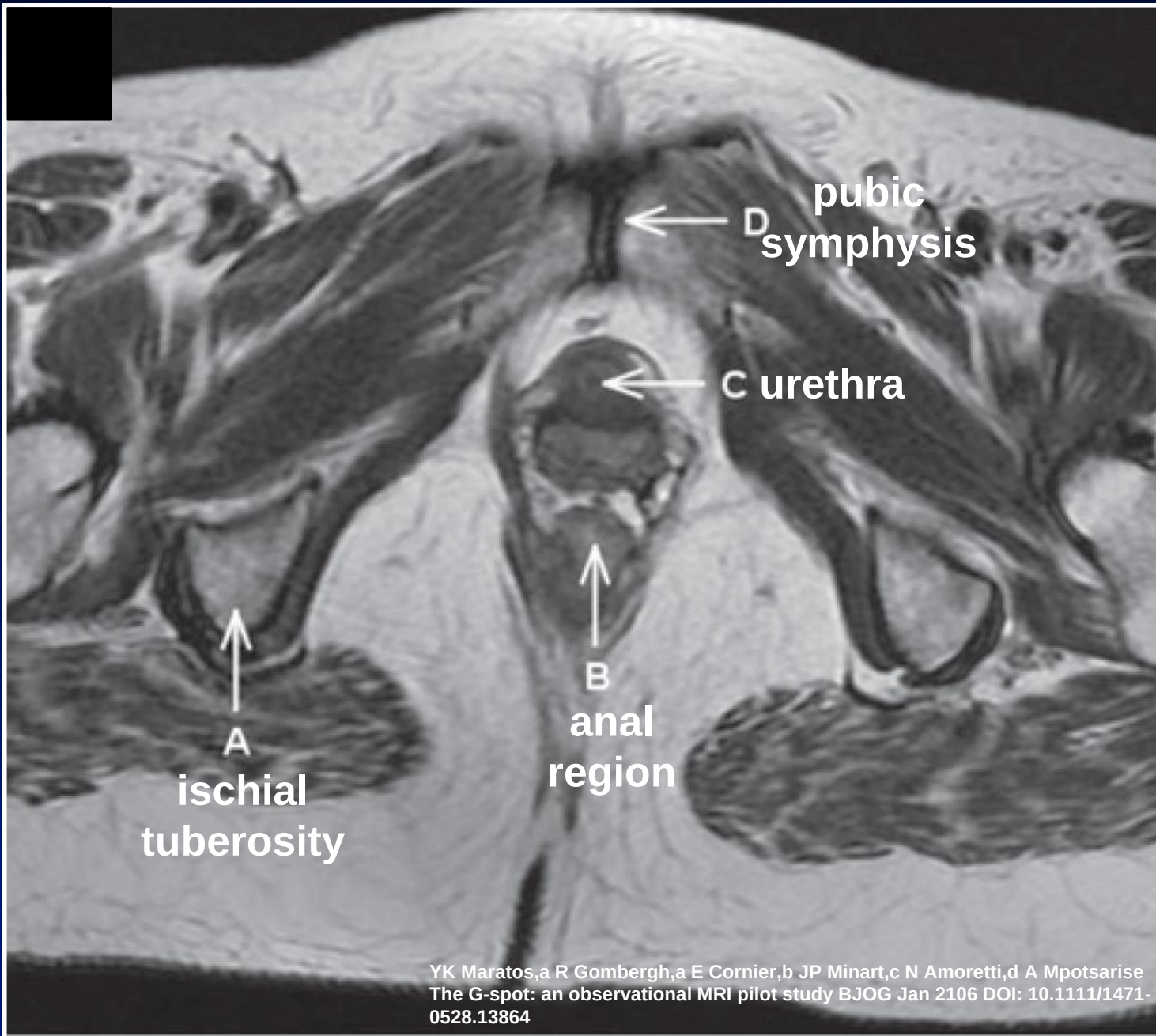

YK Maratos,a R Gombergh,a E Cornier,b JP Minart,c N Amoretti,d A Mpotsarise
The G-spot: an observational MRI pilot study BJOG Jan 2106 DOI: 10.1111/1471-0528.13864

MRI image (axial) WITH gel opacification of vagina

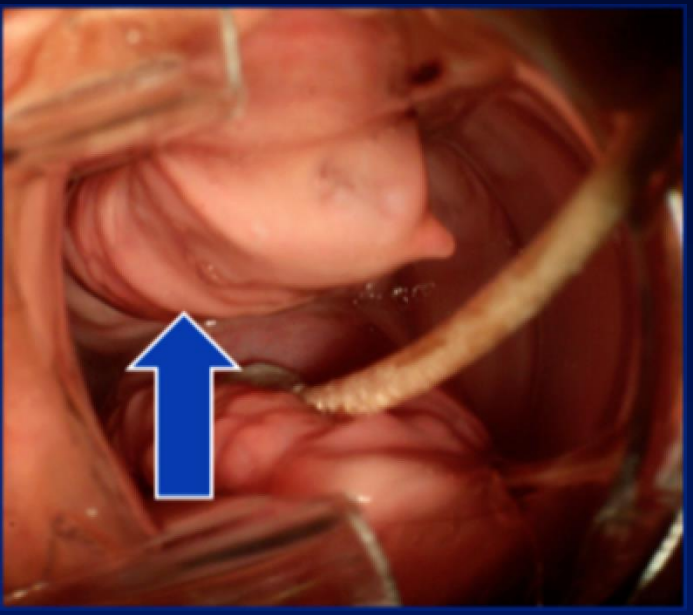

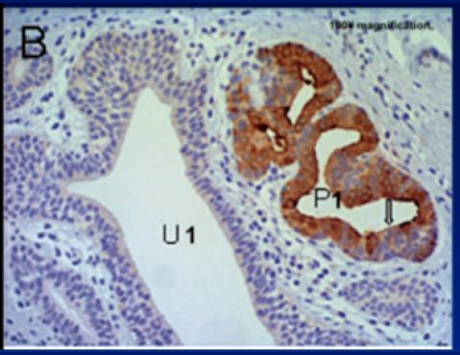

U1 = urethra

P1 = peri-urethral gland

B) Polyclonal prostate-specific antigen (PSA) staining (brown color)

Light arrow indicates islet of urothelium with weak PSA expression

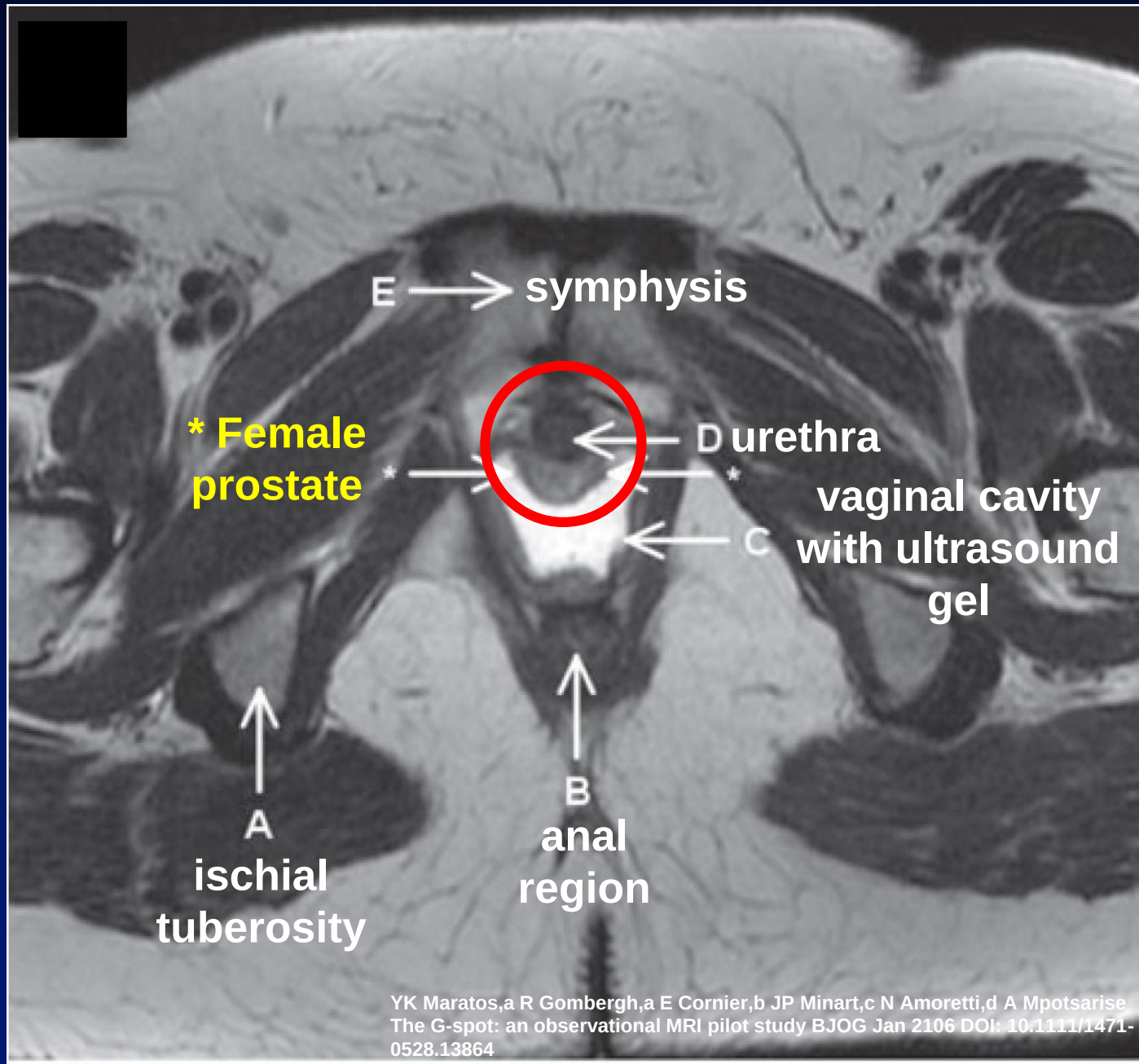

YK Maratos,a R Gombergh,a E Cornier,b JP Minart,c N Amoretti,d A Mpotsarise
The G-spot: an observational MRI pilot study BJOG Jan 2106 DOI: 10.1111/1471-0528.13864

TVT/TOT Surgery – Through Female Prostate

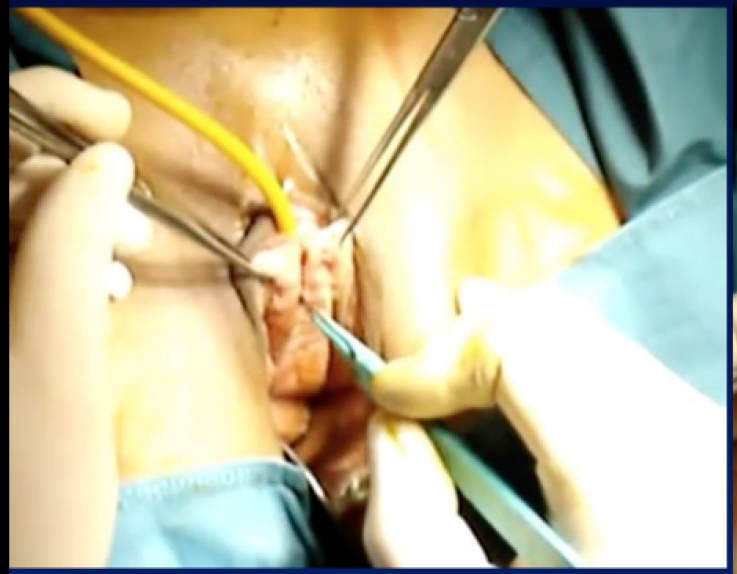

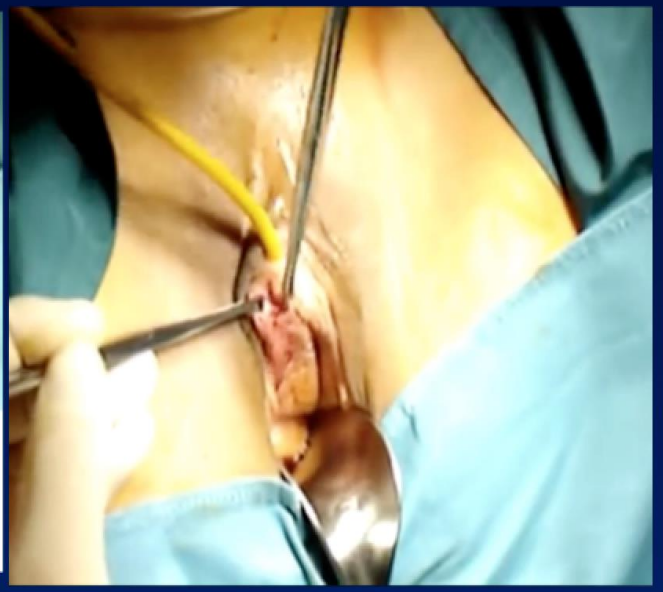

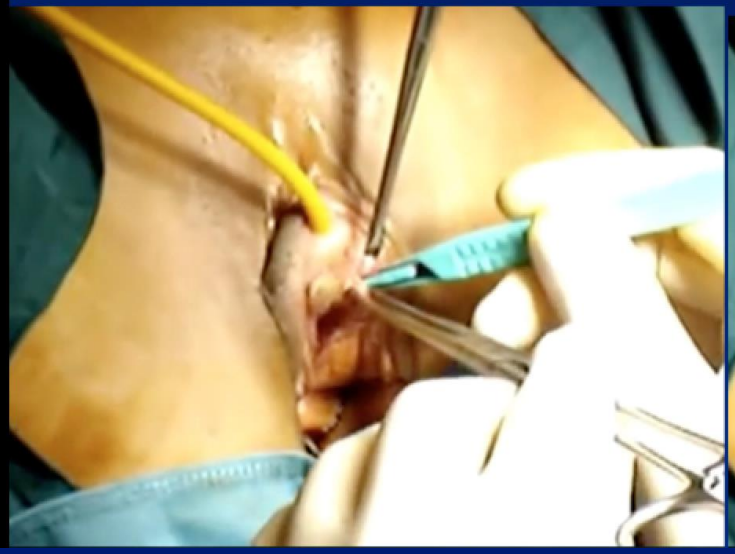

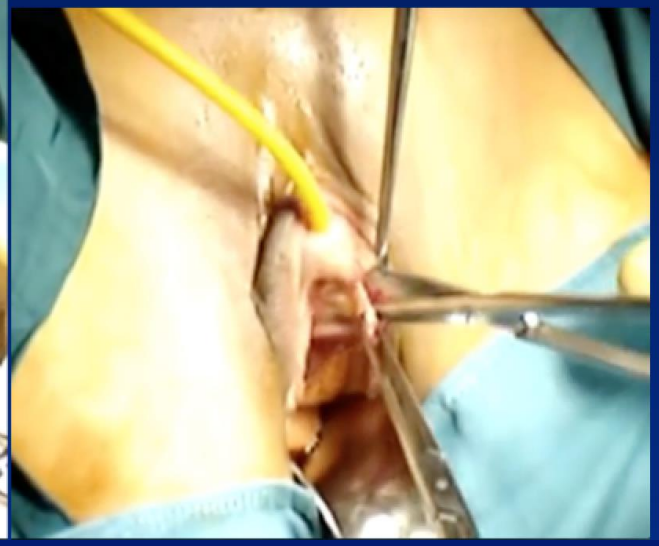

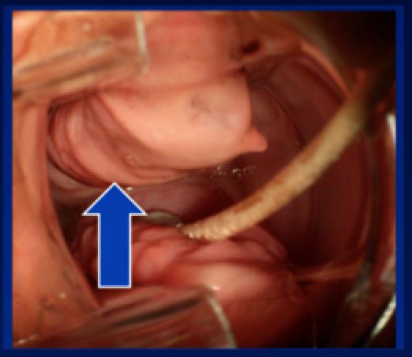

Dietrich W, Susani M, Stifter L, and Haitel A. The human female prostate—immunohistochemical study with prostate-specific antigen, prostate-specific alkaline phosphatase, and androgen receptor and 3-D remodeling. J Sex Med 2011;8:2816–2821

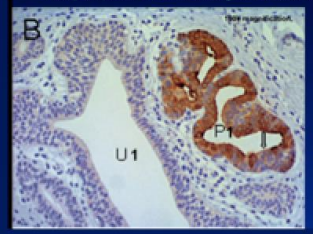

U1 = urethra

P1 = peri-urethral gland

B) Polyclonal prostate-specific antigen (PSA) staining (brown color)

Light arrow indicates islet of urethelium with weak PSA expression

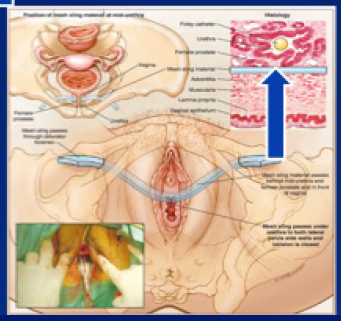

TVT/TOT Surgery – Through Female Prostate

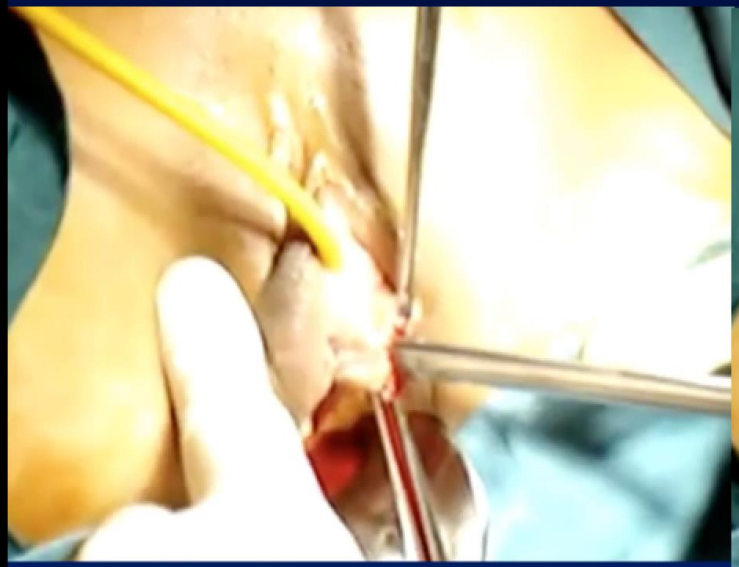

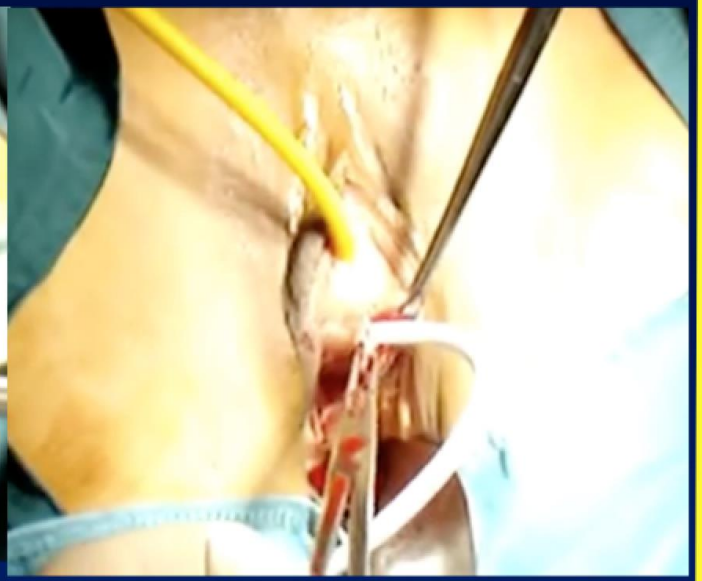

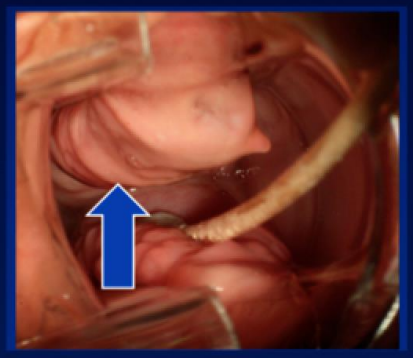

Dietrich W, Susani M, Stifter L, and Haitel A. The human female prostate—immunohistochemical study with prostate-specific antigen, prostate-specific alkaline phosphatase, and androgen receptor and 3-D remodeling. J Sex Med 2011;8:2816–2821

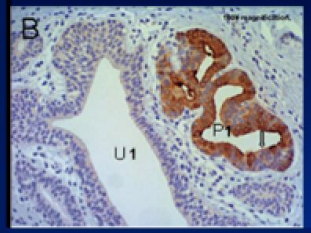

U1 = urethra

P1 = peri-urethral gland

B) Polyclonal prostate-specific antigen (PSA) staining (brown color)

Light arrow indicates islet of urethelium with weak PSA expression

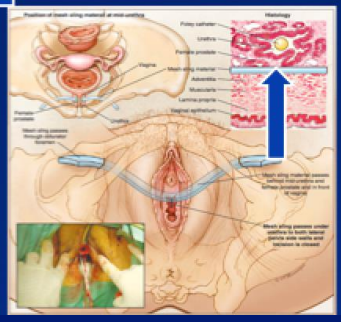

SUB-URETHRAL SLING SURGERY FOR STRESS INCONTINENCE MAY RESULT IN ORGASMIC DYSFUNCTION THROUGH DIRECT INJURY TO ANTERIOR VAGINAL WALL, PERI-URETHRAL FEMALE PROSTATIC TISSUE

There was a large discrepancy noted in orgasm satisfaction versus overall sexual satisfaction following sub-urethral sling placement.

It is hypothesized that women who were pre-operatively experiencing vaginal orgasm are at risk of developing orgasmic dysfunction secondary to direct sub-urethral sling injury to anterior wall, peri-urethral female prostatic tissue.

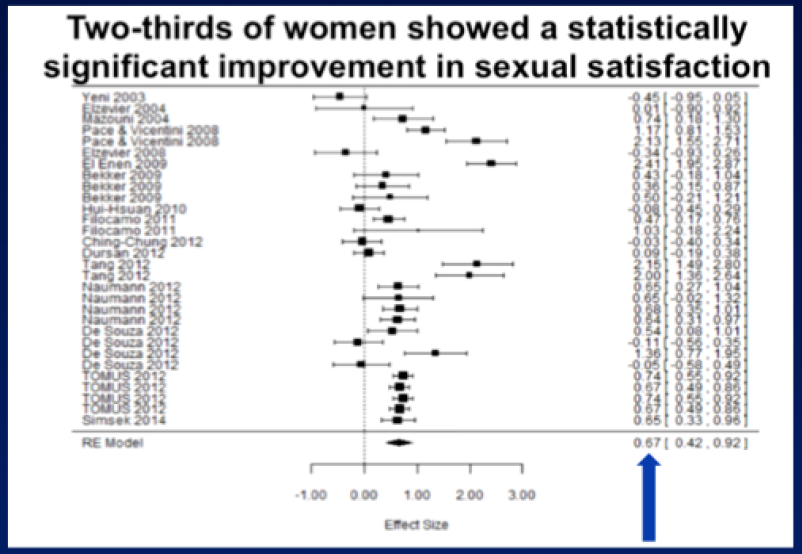

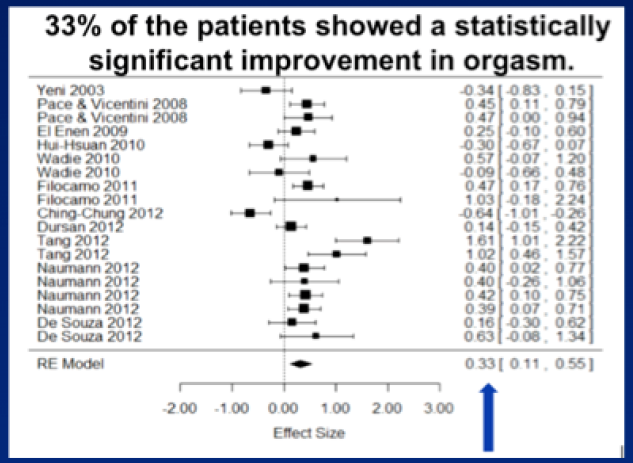

27% of women experienced worsening of orgasm satisfaction

Patient Testimonials

AA – I always had clitoral and vaginal nerve sensation and was able to achieve an orgasm easily. Cervical stimulation is pleasurable. My husband was able to manipulate his fingers where he could actually "milk" the gland that produced the fluid that I release when I "squirt." The fluid was ejected but I felt no sensation of an orgasm.
The stimulation to the gland is pleasurable but I'm still unable to "get over the hill."

Anatomy

G-spot
Clitoris Glans, Clitoral Corona, Clitoral Frenula
Corpora Spongiosa (Vestibular Bulbs)
Clitoris Shaft, Clitoris Crus
Female Prostate, Peri-urethral Tissue
Cervix
Vulva
Vestibule
Vagina
Urethral Meatus/Urethral Glans
Sacral and Lumbar Spinal Cord

Sexual Function of the Cervix

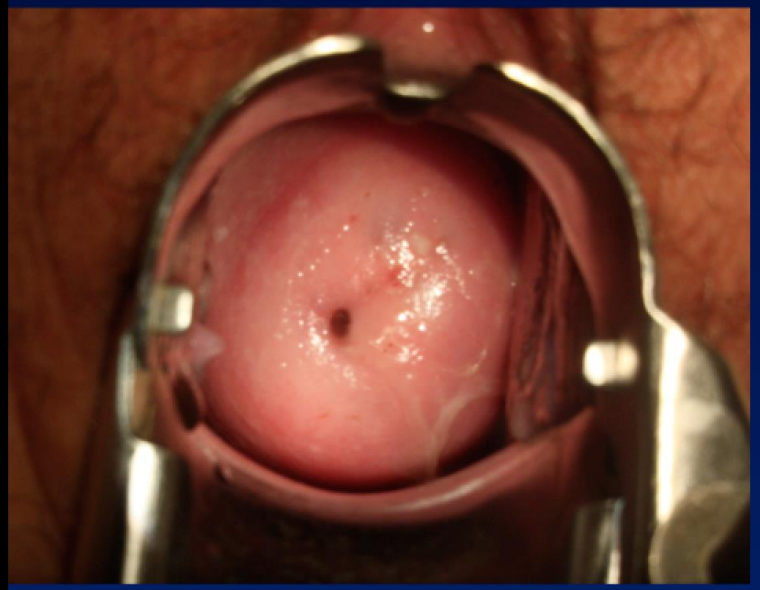

Courtesy Dr I Goldstein

External and Internal Orgasm

External – Clitoral

Internal – Female Prostate

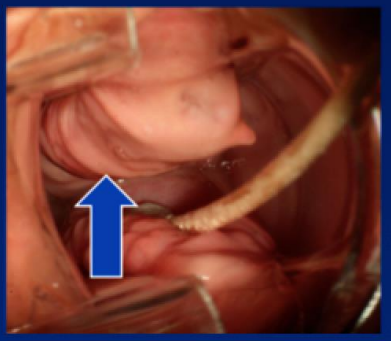

Internal – Cervix and Uterus

Sexual Function of the Cervix

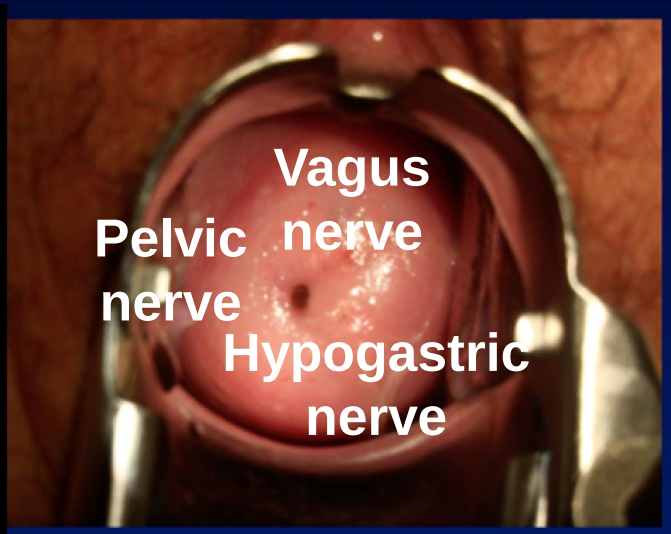

The human cervix is triply innervated by sensory nerves. This is a unique and significant innervation pattern

pelvic nerve – parasympathetic S2, S3, S4
hypogastric nerve – sympathetic T10 – L2
vagus nerve – cranial nerve 10

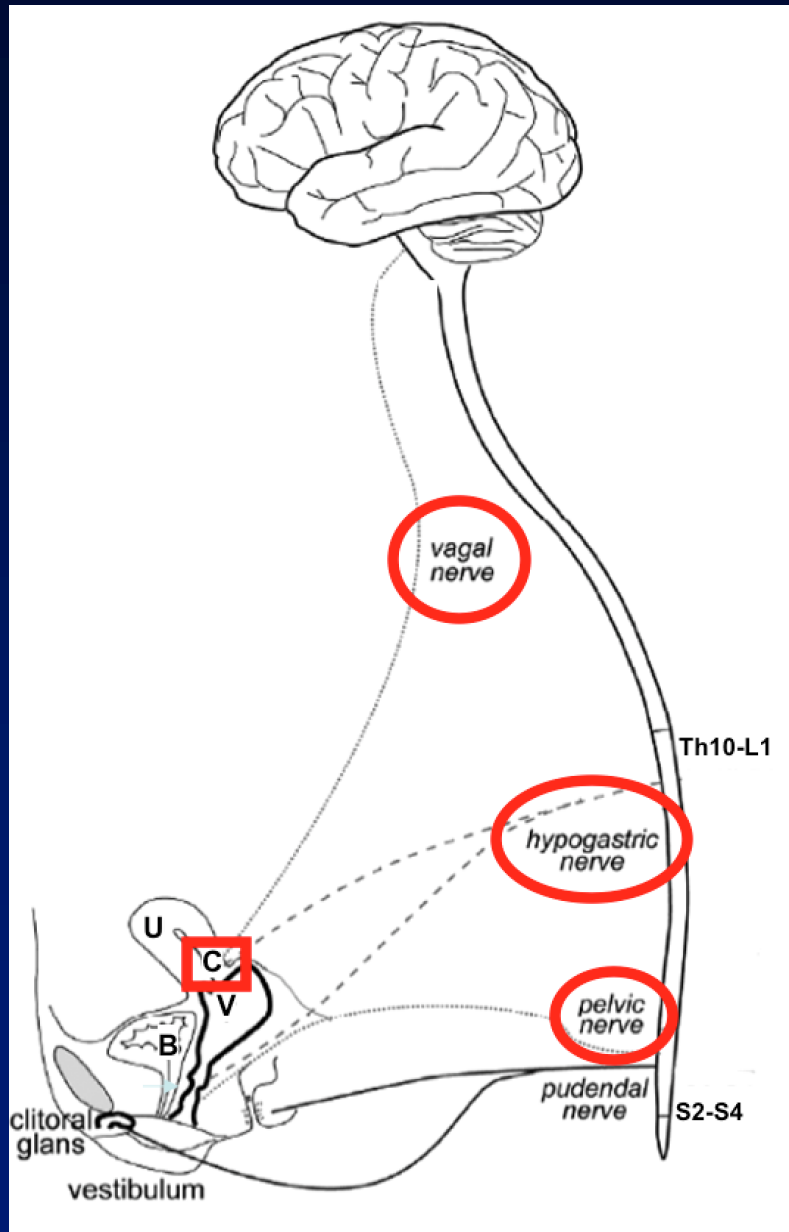

Is it really that surprising that the removal of a significant portion of the cervix (LEEP/cone biopsy) can result in female sexual dysfunction

Cutler et al (2000) reported: **35% of 128 women stated that cervical stimulation contributed to their orgasm function**

Kilkku et al (1983) reported **a lesser incidence of orgasms in women who underwent total hysterectomy** (removal of both the cervix and the uterus) VERSUS women who underwent subtotal hysterectomy (removal of just the uterus)

Komisaruk et al (2006) reported: during sexual intercourse **cervical stimulation was qualitatively different** (a "shower of stars") VERSUS vaginal (female prostate/anterior vaginal wall) or clitoral stimulation.

Is it really that surprising that the removal of a significant portion of the cervix (LEEP/cone biopsy) can result in female sexual dysfunction

Komisaruk et al (2011) using functional MRI of the brain, presented evidence that **self-stimulation of the cervix activated the genital sensory cortex** (paracentral lobule) overlapping with the regions activated by self-stimulation of the vagina or the clitoris, providing evidence **that cervical sensory activity can rise to the level of awareness just as can vaginal or clitoral sensory activity.**

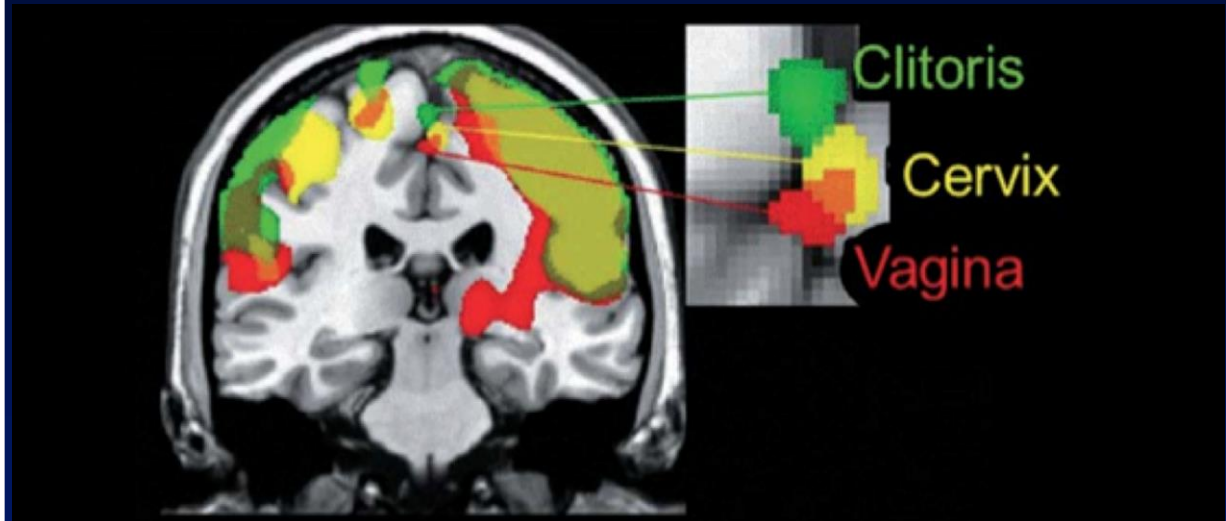

Stimulation of the clitoris, vagina, and cervix activate different regions of the brain, including somatosensory cortex, limbic structures, and hypothalamus.

Cervical Movement During Orgasm

Individual elevations of the cervix are observed that result from individual mechanical uterine contractions during orgasm

These are likely produced by hormonal effects - circulating **oxytocin** - released at orgasm

Oxytocin secretion can result from **sensory stimulation via the pudendal, pelvic, hypogastric, and/or vagus nerves**

The cervical elevations during orgasm and uterine contraction are NOT LIKELY the result of efferent motor neural activity to the cervix

LEEP – Loop Electrosurgical Excision Procedure – Injures Nerves to Cervix

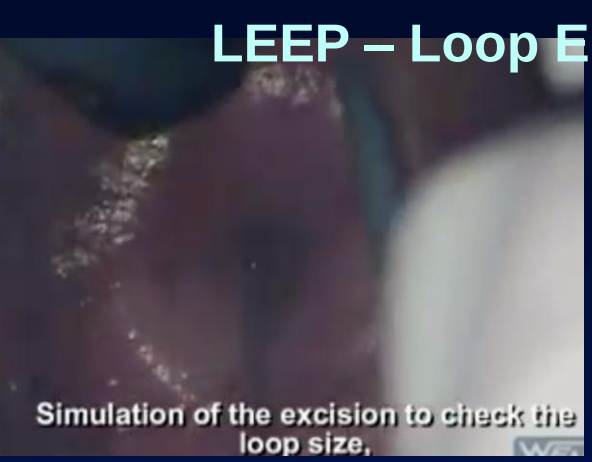

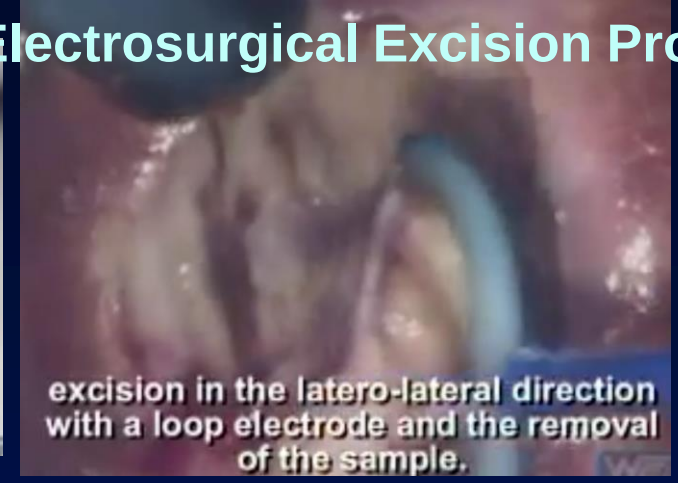

LEEP – Loop Electrosurgical Excision Procedure – Injures Nerves to Cervix

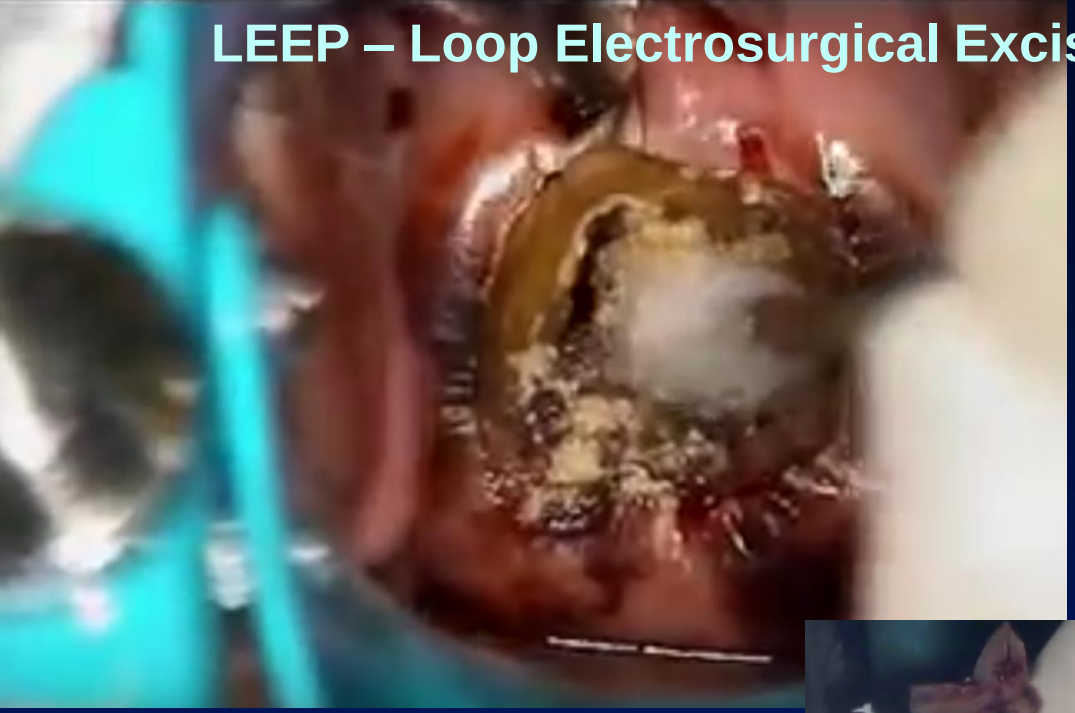

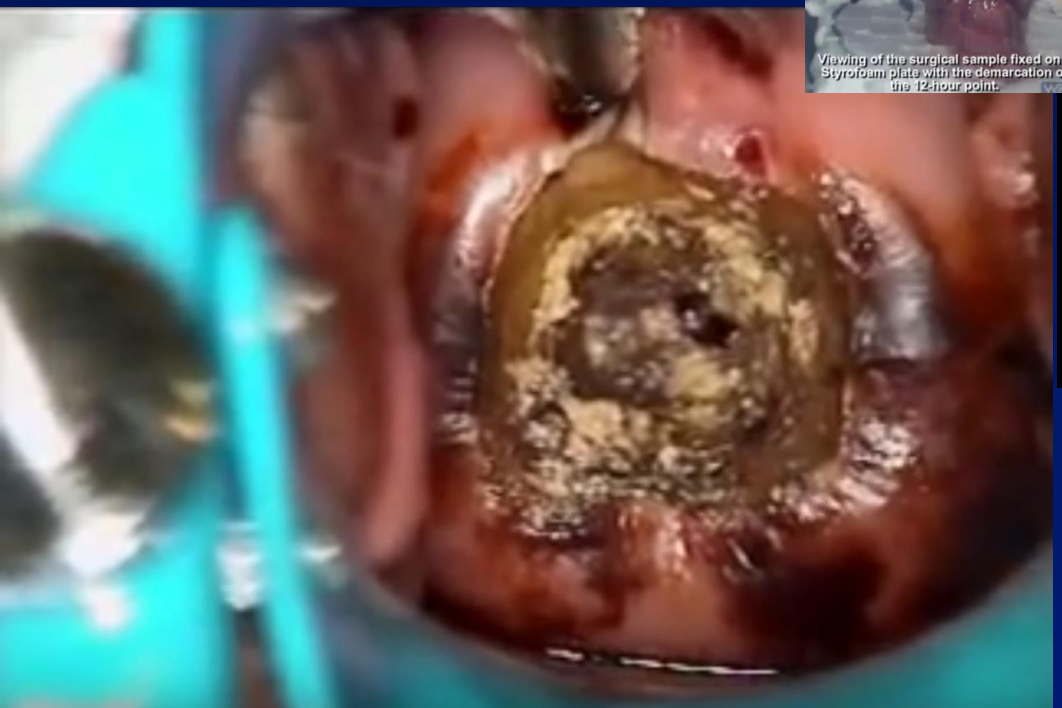

Patient Testimonials

AD is a 38-year old woman who reports that she had a cervical loop electrosurgical excision procedure (LEEP) procedure in 2010. Ashley reported that prior to the LEEP procedure she had excellent satisfying orgasms. However, after the LEEP procedure, something went "drastrically wrong" with her body. Ashley reports lack of sensation in her genitals. Ashley reports that she has no sexual urges and very poor orgasm. This has been very distressing.

Loop Electrosurgical Excision Procedure (LEEP)
One patient's graphic self-depiction

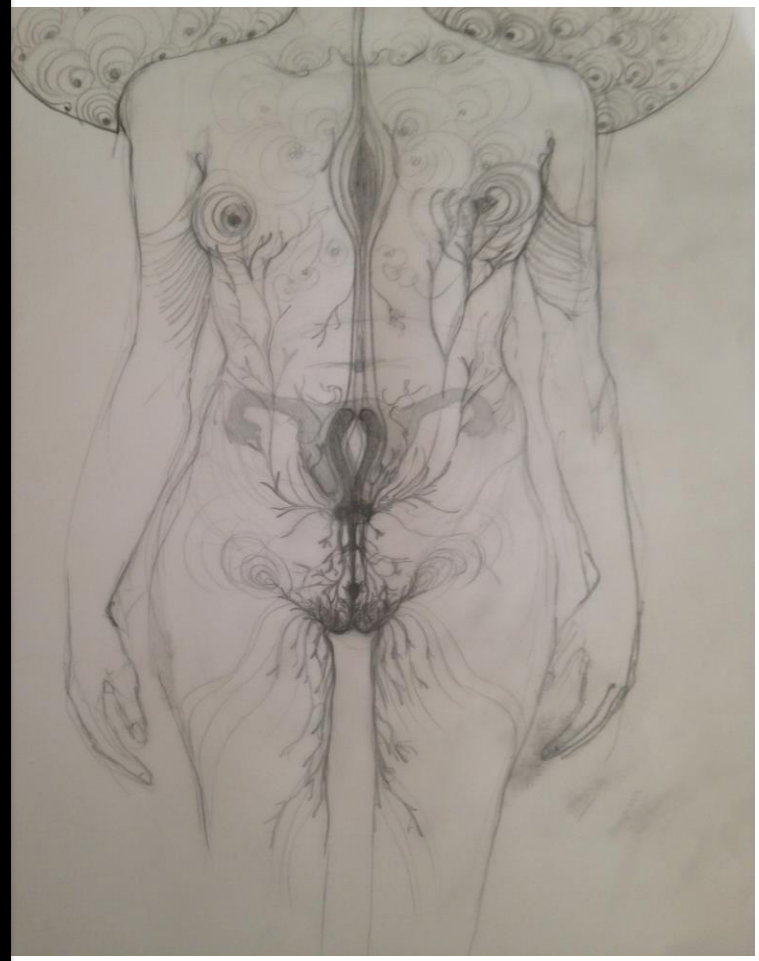

Pre LEEP:
"Full sexual response including mental engagement"

Current post LEEP:
"Sexual response only at clitoral region"

Patient Testimonials

SH is a 32 year old woman with sexual dysfunction immediately following a LEEP procedure in March 2013. SH states that her sex life has been ruined since her procedure. Stefanie states that prior to her LEEP procedure she had normal orgasmic function. Stefanie states she was married in 2011. Stefanie states that before her procedure she had internal orgasms and a high sex drive and was having sexual activity 5 times per week. Stefanie states that in the year after her procedure she only had sexual intercourse twice. Stefanie cannot have internal orgasm since the procedure. As a result she has lost her interest in sex and performs sex without the pleasure of having sex. Stefanie states she and her husband have decided to get pregnant. Stefanie states that sex is now mechanical and there is no pleasure or satiety.

Anatomy

G-spot
Clitoris Glans, Clitoral Corona, Clitoral Frenula
Corpora Spongiosa (Vestibular Bulbs)
Clitoris Shaft, Clitoris Crus
Female Prostate, Peri-urethral Tissue
Cervix
Vulva
Vestibule
Vagina
Urethral Meatus/Urethral Glans
Sacral and Lumbar Spinal Cord

Innervation –vestibule/vulva

Somatic nerves via branches of the pudendal nerve – the vestibule and the vulva have a high density of somatic nerve fibers

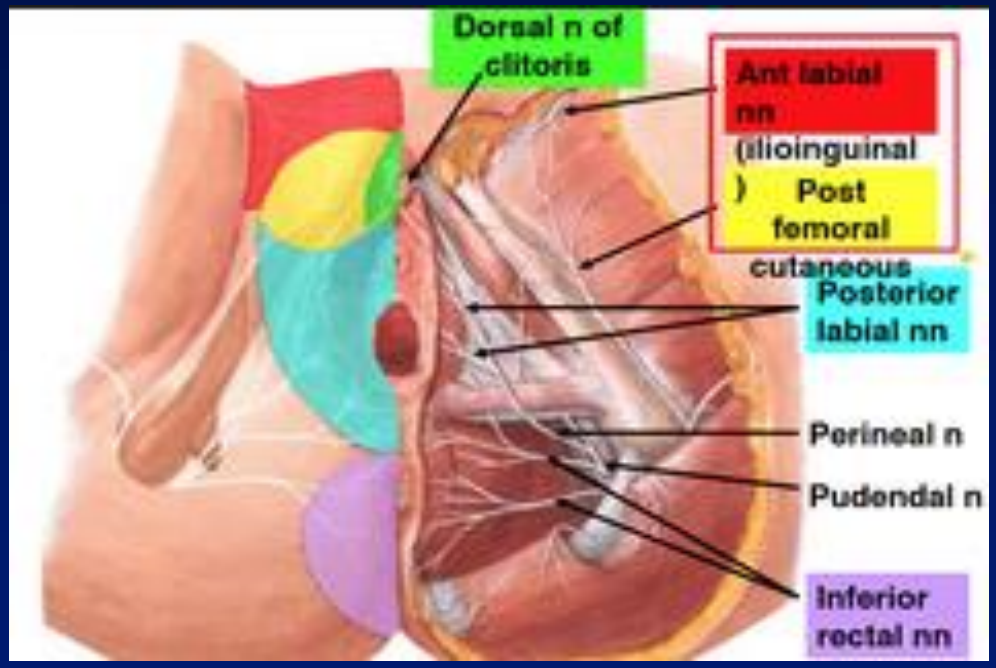

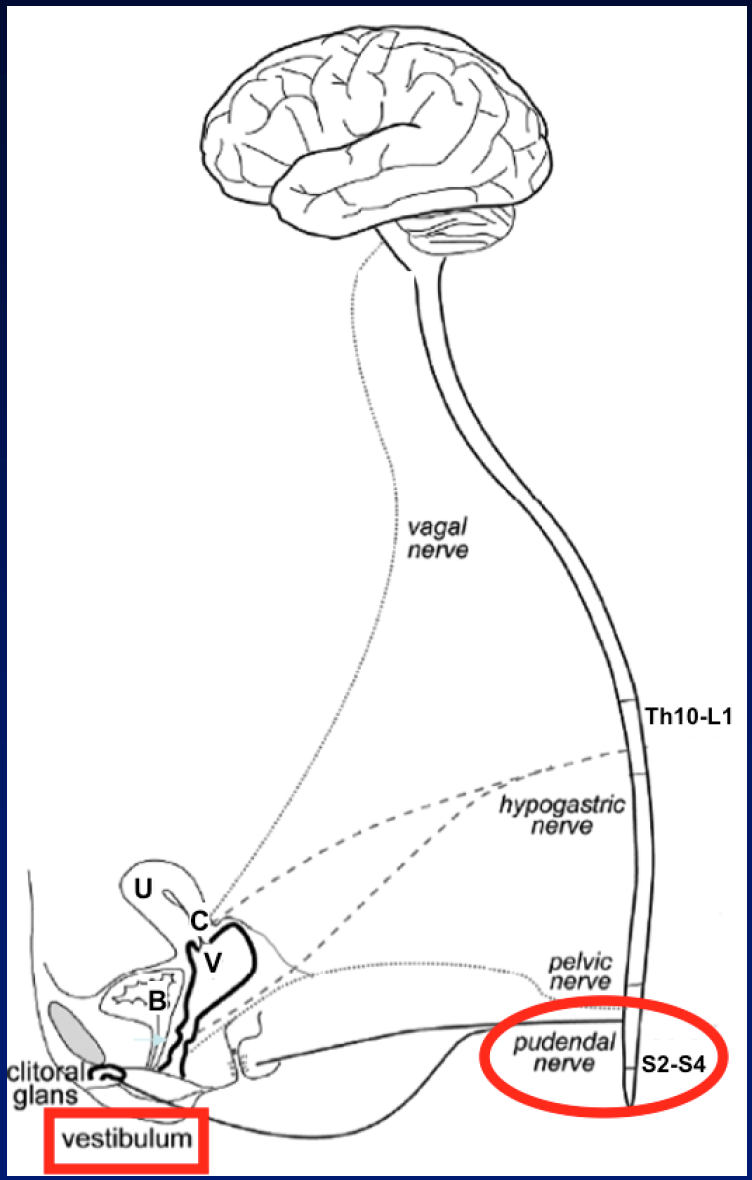

Nappi R, Salonia A, Traish AM, van Lunsen RHW, Vardi Y, Kodiglu K, and Goldstein I. Clinical Biologic Pathophysiologies of Women's Sexual Dysfunction. J Sex Med 2005 Jan 2(1): 4-25.

Iatrogenic Sexual Dysfunction - Labioplasty

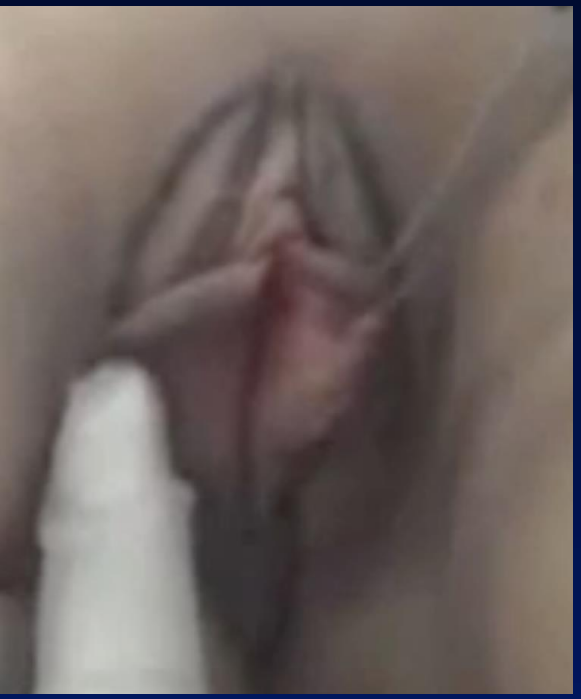
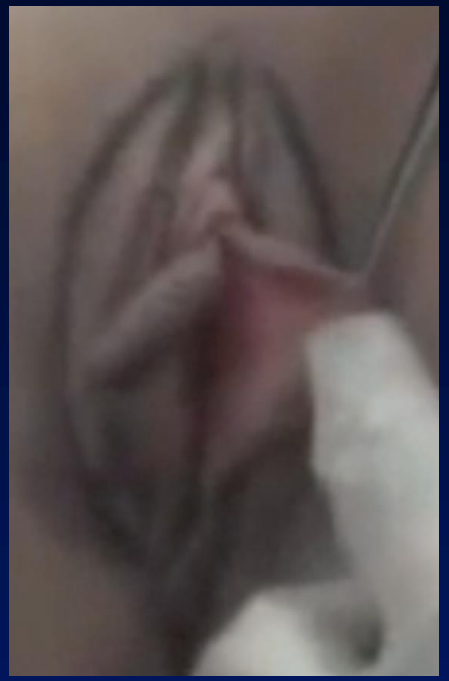
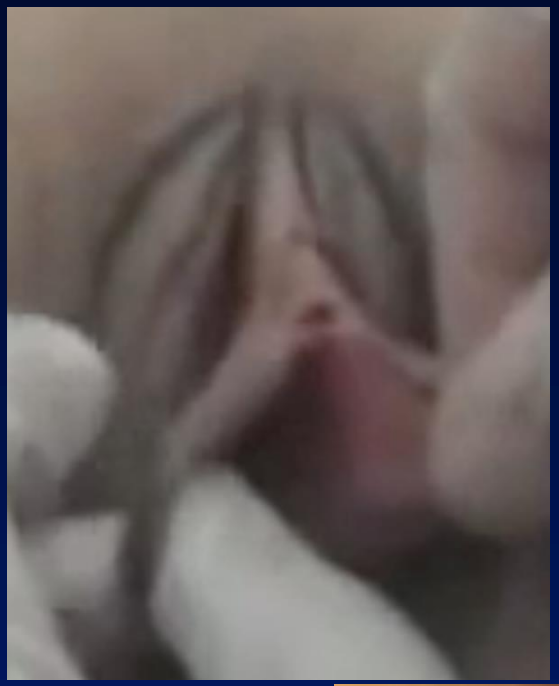



Low Estrogen State

Resorption of Labia Minora

Robust Estrogen State

Labia Minora Normally Meet at Posterior Fourchette

Bicyclist's vulva: observational study

Luc Baeyens, Elke Vermeersch, Pierre Bourgeois

BMJ 2002;325:138–9

Six women, aged 21-38 years, had a unilateral chronic swelling, lymphedema of labium majora (five on the right side, one on the left) after years of bicycling (average 462.5 km/week) - more severe after more intense and longer training

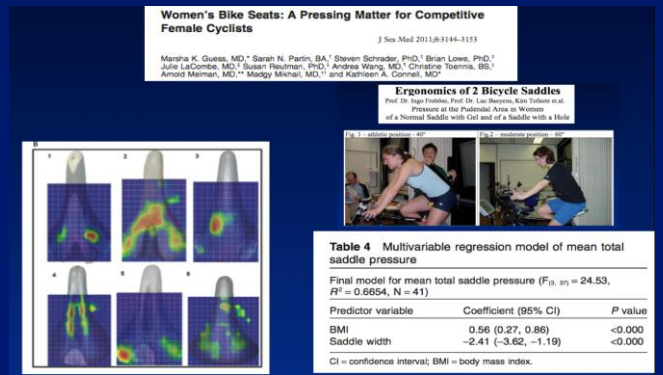

Women's Bike Seats: A Pressing Matter for Competitive Female Cyclists

J Sex Med 2011;8:3144–3153

Marsha K. Guess, MD,* Sarah N. Partin, BA,† Steven Schrader, PhD,† Brian Lowe, PhD,† Julie LaCombe, MD,† Susan Reutman, PhD,† Andrea Wang, MD,† Christine Toennis, BS,† Arnold Melman, MD,** Madgy Mikhail, MD,†† and Kathleen A. Connell, MD‡

Ergonomics of 2 Bicycle Saddles

Prof. Dr. Ingo Froböse, Prof. Dr. Luc Baeyens, Kim Tofaute et al.

Pressure at the Pudendal Area in Women of a Normal Saddle with Gel and of a Saddle with a Hole

Table 4 Multivariable regression model of mean total saddle pressure

Final model for mean total saddle pressure ($F_{(3,\ 37)} = 24.53$, $R^2 = 0.6654$, N = 41)

Predictor variable	Coefficient (95% CI)	*P* value
BMI	0.56 (0.27, 0.86)	<0.000
Saddle width	−2.41 (−3.62, −1.19)	<0.000

CI = confidence interval; BMI = body mass index.

Anatomy

G-spot
Clitoris Glans, Clitoral Corona, Clitoral Frenula
Corpora Spongiosa (Vestibular Bulbs)
Clitoris Shaft, Clitoris Crus
Female Prostate, Peri-urethral Tissue
Cervix
Vulva
Vestibule
Vagina
Urethral Meatus/Urethral Glans
Sacral and Lumbar Spinal Cord

VULVODYNIA – ANATOMY OF VULVA, VESTIBULE , VAGINA

Embryology:

Mesoderm (vagina)

Endoderm (vestibule)

Ectoderm (vulva)

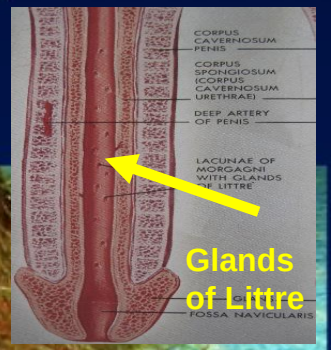

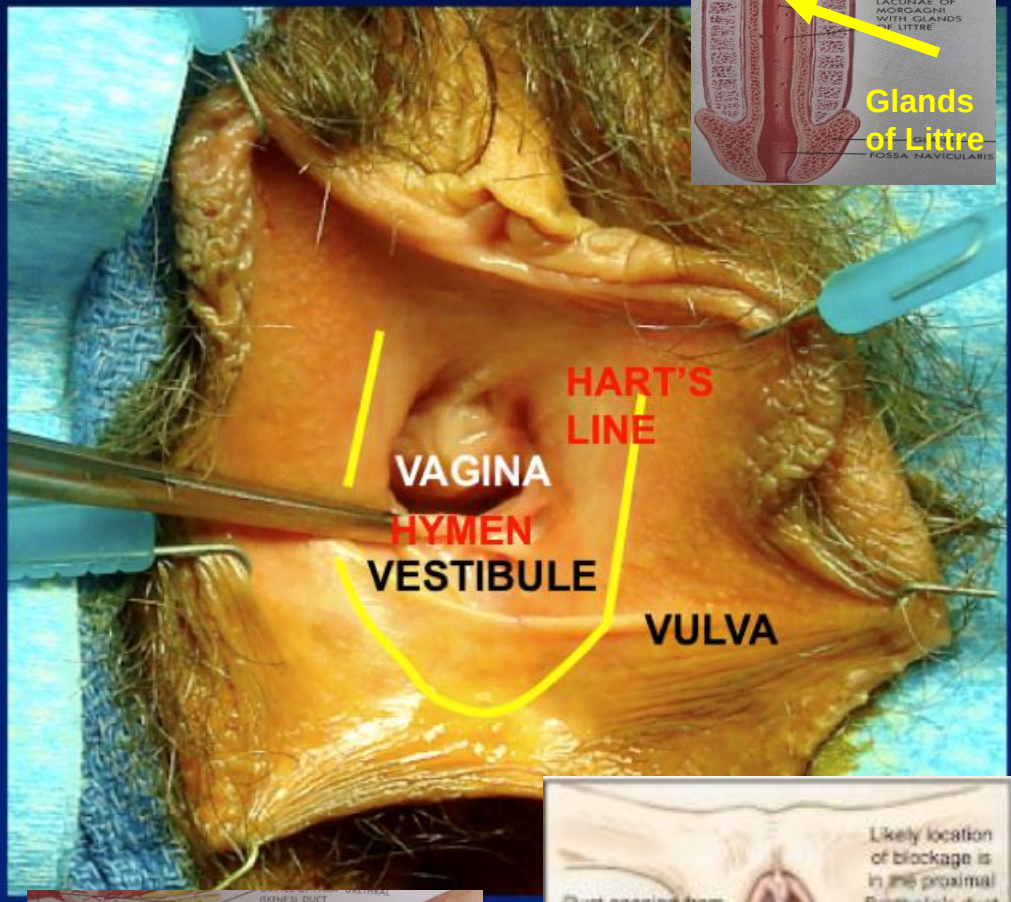

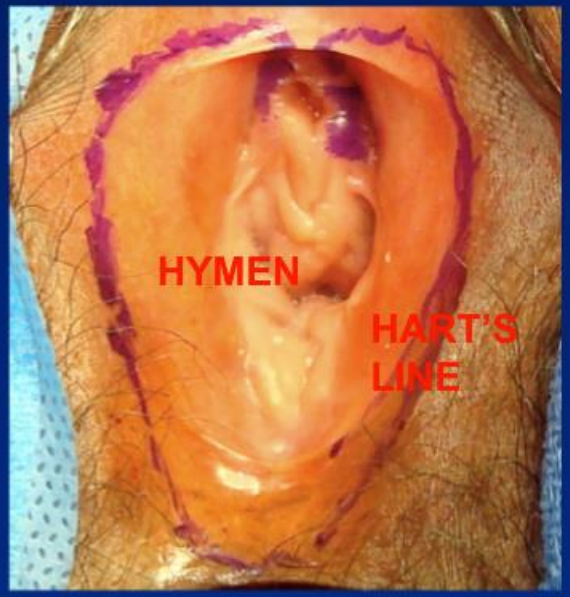

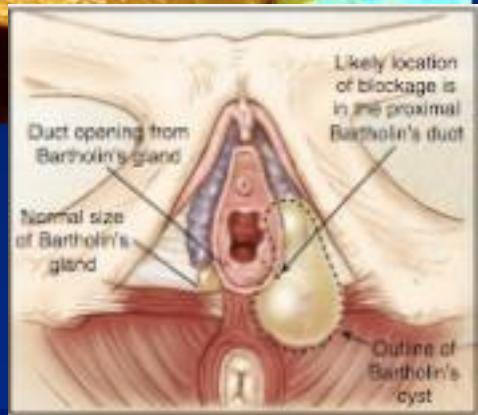

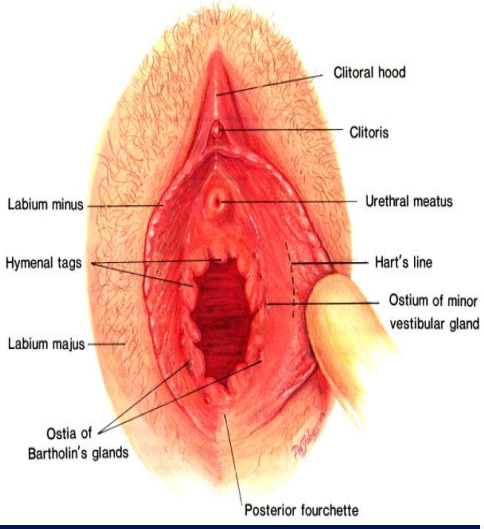
Clitoral hood
Clitoris
Labium minus
Urethral meatus
Hymenal tags
Hart's line
Ostium of minor vestibular gland
Labium majus
Ostia of Bartholin's glands
Posterior fourchette

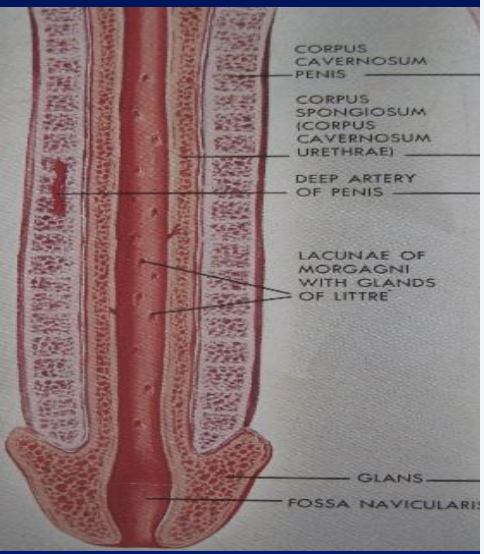
CORPUS CAVERNOSUM PENIS
CORPUS SPONGIOSUM (CORPUS CAVERNOSUM URETHRAE)
DEEP ARTERY OF PENIS
LACUNAE OF MORGAGNI WITH GLANDS OF LITTRE
GLANS
FOSSA NAVICULARIS

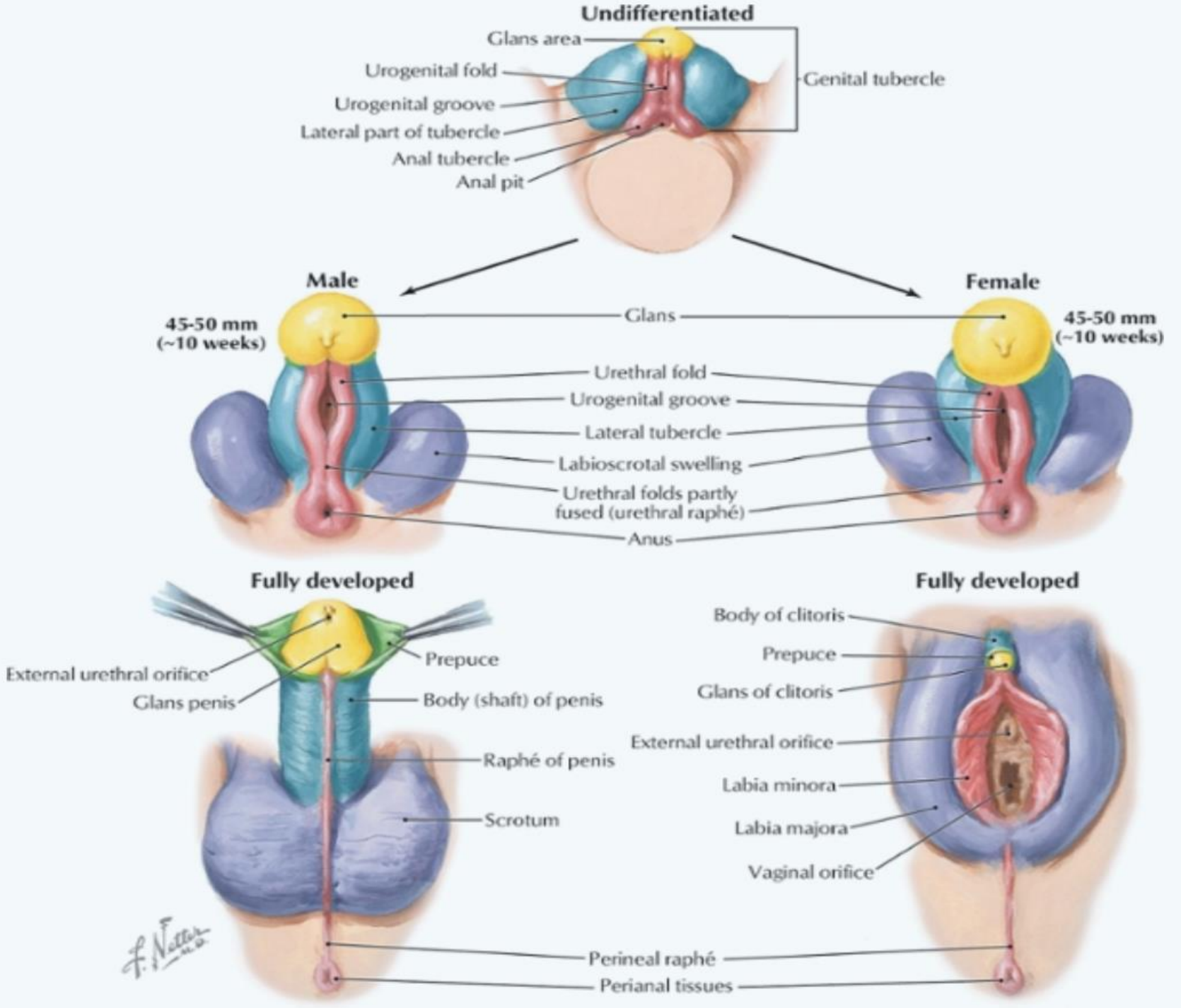
Undifferentiated
Glans area
Urogenital fold
Urogenital groove
Lateral part of tubercle
Anal tubercle
Anal pit
Genital tubercle
Male
Female
45-50 mm (~10 weeks)
Glans
45-50 mm (~10 weeks)
Urethral fold
Urogenital groove
Lateral tubercle
Labioscrotal swelling
Urethral folds partly fused (urethral raphé)
Anus
Fully developed
External urethral orifice
Glans penis
Prepuce
Body (shaft) of penis
Raphé of penis
Scrotum
Fully developed
Body of clitoris
Prepuce
Glans of clitoris
External urethral orifice
Labia minora
Labia majora
Vaginal orifice
Perineal raphé
Perianal tissues

VESTIBULE

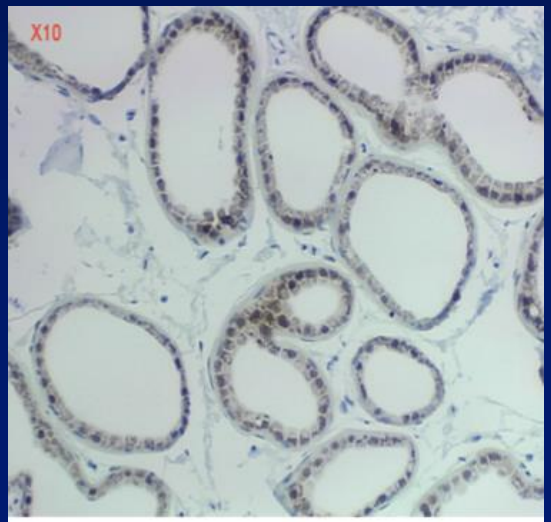

Vestibular glands –Positive cellular nuclei staining with anti-androgen receptor

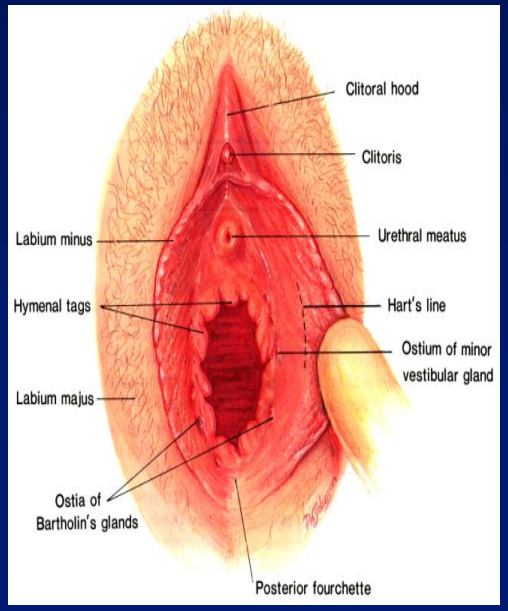

- Lateral border is Hart's line
- Medial border is the hymen and urethra
- Ostia of the Bartholin's, Skene's and minor vestibular glands
- Derived from the primitive urogenital sinus
- Different innervation from the vagina
- **Rich in AR and ER**

Nappi R, Salonia A, Traish AM, van Lunsen RHW, Vardi Y, Kodiglu K, and Goldstein I. Clinical Biologic Pathophysiologies of Women's Sexual Dysfunction. J Sex Med 2005 Jan 2(1): 4-25.

clitoral hood
clitoral glans
labia minora
vaginal opening
labia majora
perineum

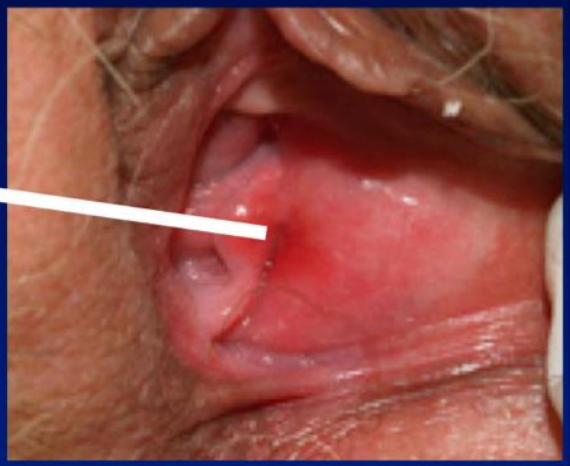

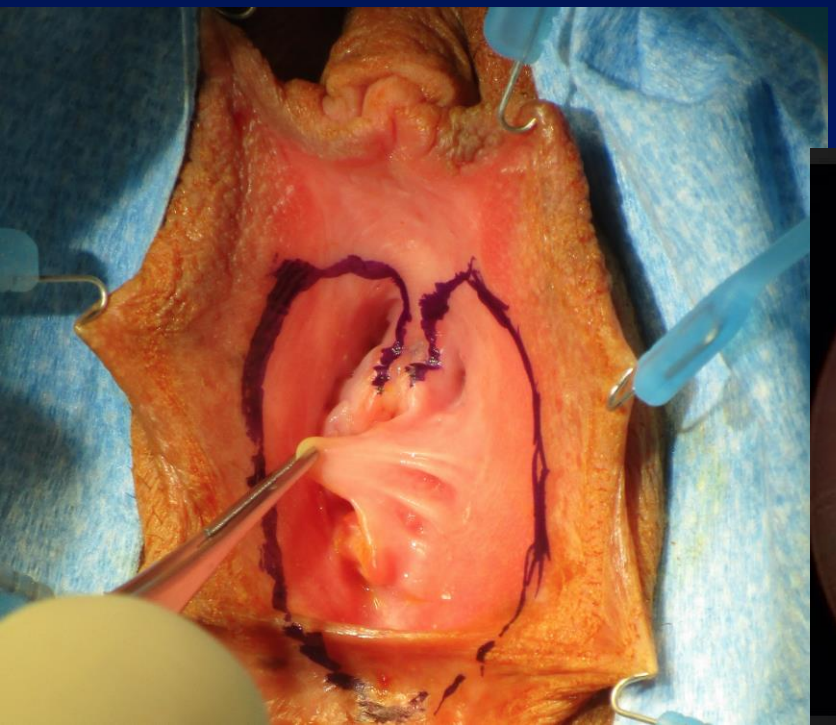

Genito-urinary Atrophy:

pH >5.0

Rugosity – ↓ vaginal epithelium

Color - ↑ pallor / friability

Elasticity - introital stenosis

Urethral meatus/glan - patulous / telescoped

Vestibule - concavity, involution

Fourchette - ↑ erythema

Baseline

Estrogen Avoidance – EA – 3 years

Anatomy

G-spot
Clitoris Glans, Clitoral Corona, Clitoral Frenula
Corpora Spongiosa (Vestibular Bulbs)
Clitoris Shaft, Clitoris Crus
Female Prostate, Peri-urethral Tissue
Cervix
Vulva
Vestibule
Vagina
Urethral Meatus/Urethral Glans
Sacral and Lumbar Spinal Cord

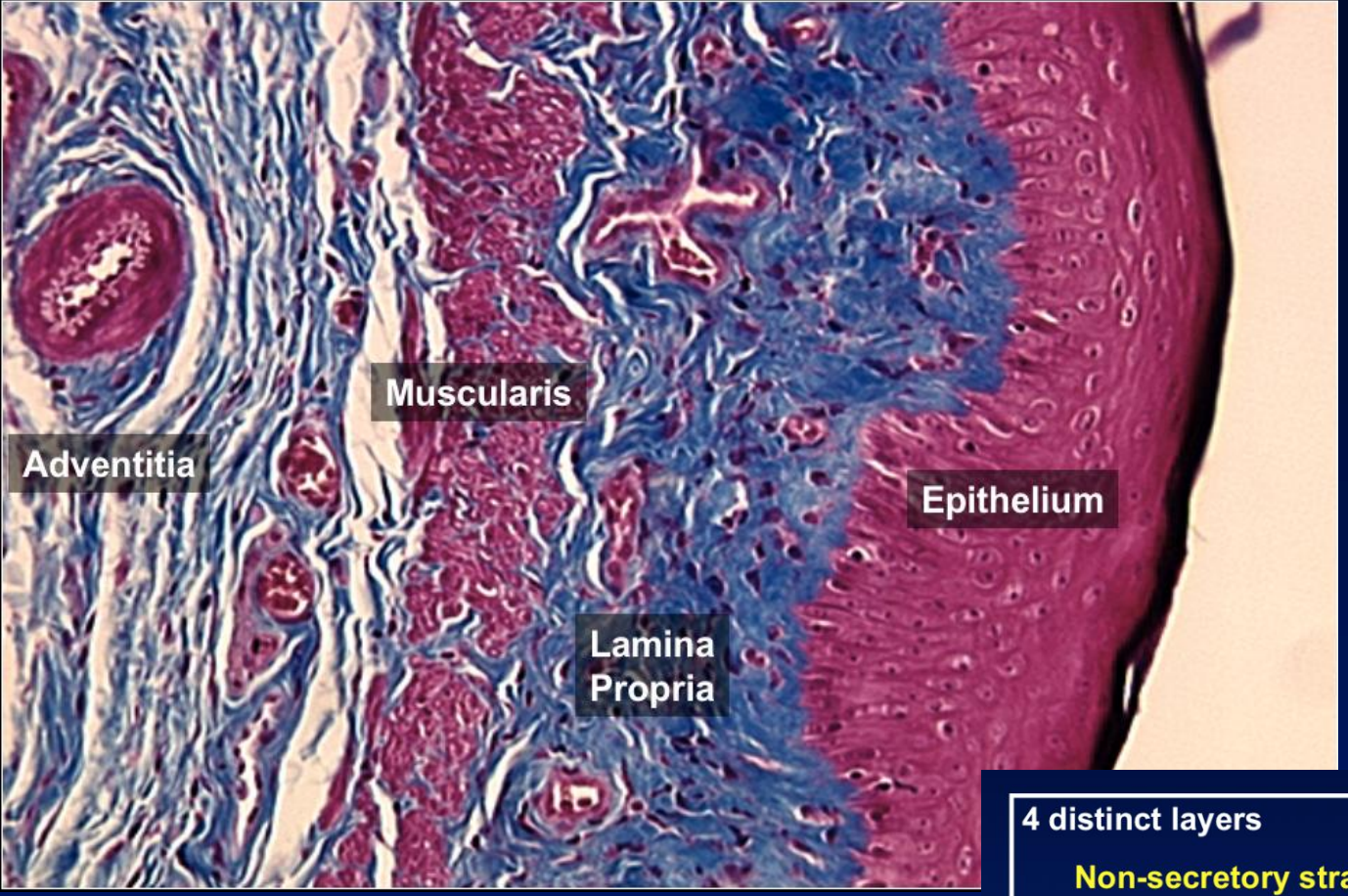

4 distinct layers

- Non-secretory stratified squamous epithelium
- Lamina propria or tunica, made of collagen and elastin, containing a rich supply of vascular and lymphatic channels
- Layer of smooth muscle running in both circular and longitudinal directions
- Areolar connective tissue and vascular plexus

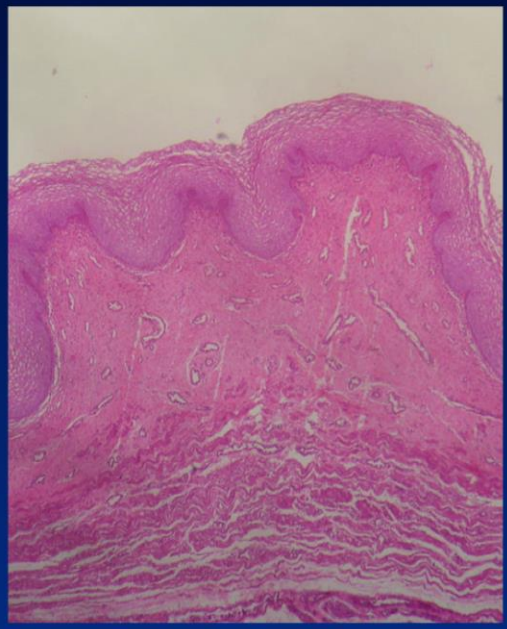

Normal Vaginal Structure in Healthy Reproductive Age Women

- Length of vagina varies between 4.1 cm (1.6 in) - 9.5 cm (3.7 in)
- Surface contact varies from 10.4 cm (4.1 in) - 16.5 mm (6.5 in)
- **Hormonal status impacts vaginal structure and surrounding areas**
- May be affected by surgical manipulations

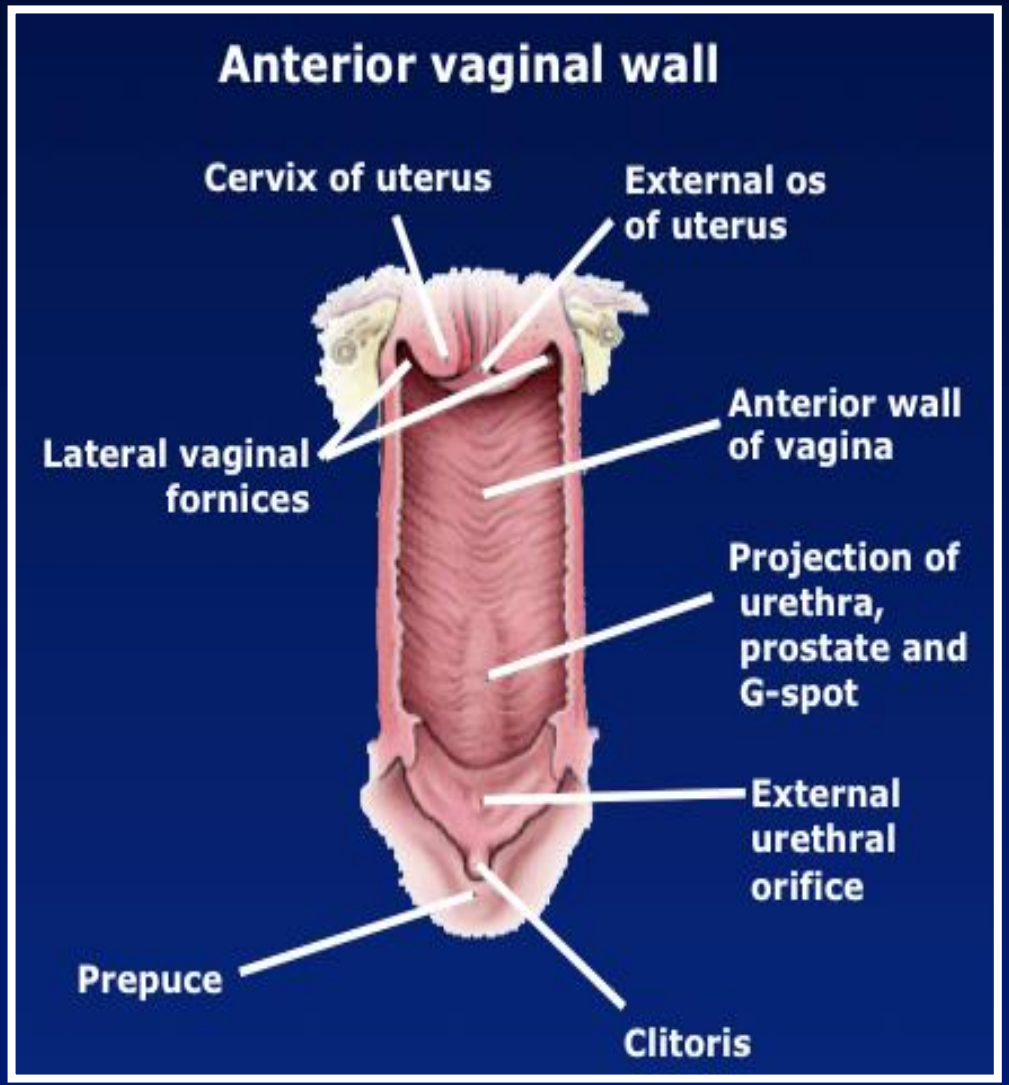

Diagnostic Testing of Female Sexual Dysfunction

Innervation - vagina

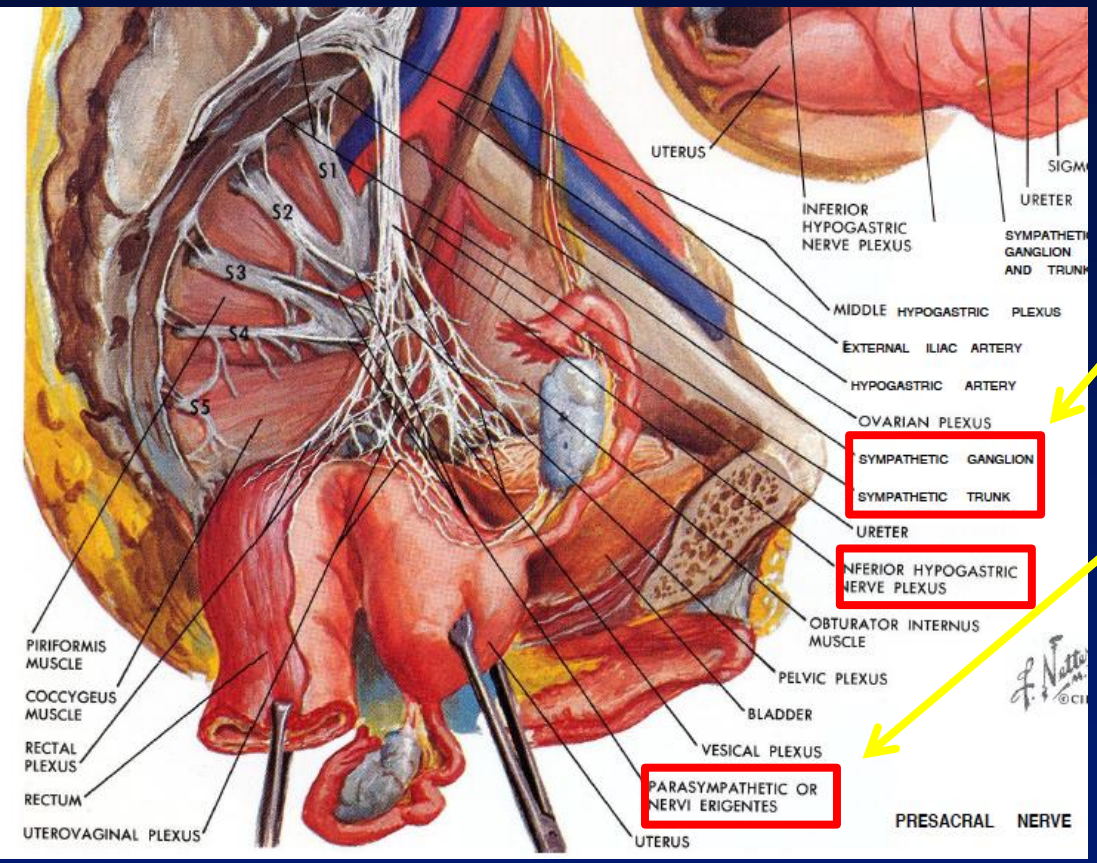

- From the uterovaginal plexus, a subdivision of the inferior hypogastric (pelvic) plexus
- Sympathetic, parasympathetic, and visceral afferents to and from the vagina pass through this plexus
- Sympathetic innervation from lower lumbar spinal cord segments via lumbar splanchnic nerves and intermediate plexuses
- Parasympathetic innervation from pelvic splanchnic nerves (S2,3,4 spinal cord levels) via pelvic plexus
- Afferent fibers with pain information (somatic) ascend through plexuses to lumber splanchnic nerves to reach upper lumber/lower thoracic spinal cord segments - **the vagina has relatively few somatic nerve fibers**

Nappi R, Salonia A, Traish AM, van Lunsen RHW, Vardi Y, Kodiglu K, and Goldstein I. Clinical Biologic Pathophysiologies of Women's Sexual Dysfunction. J Sex Med 2005 Jan 2(1): 4-25.

Differential Effects of Estradiol on Vaginal Structural Integrity

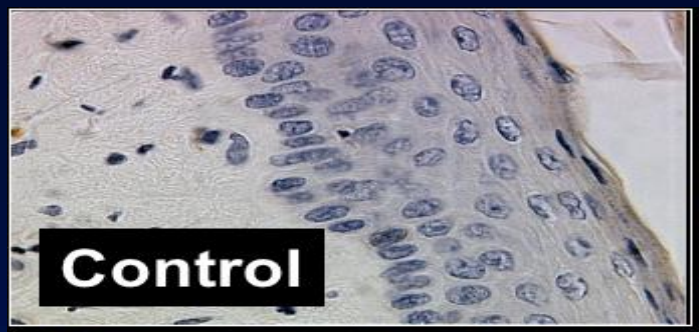

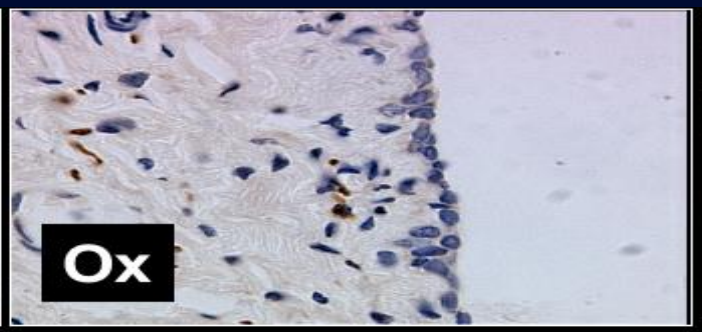

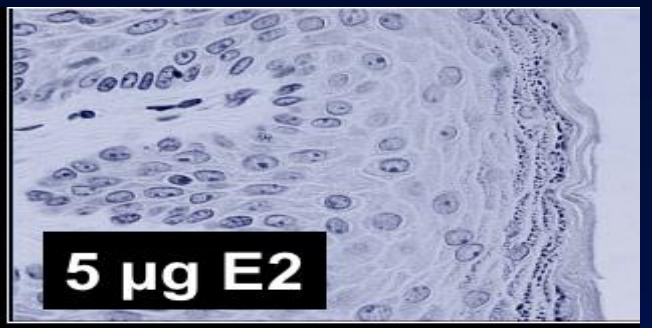

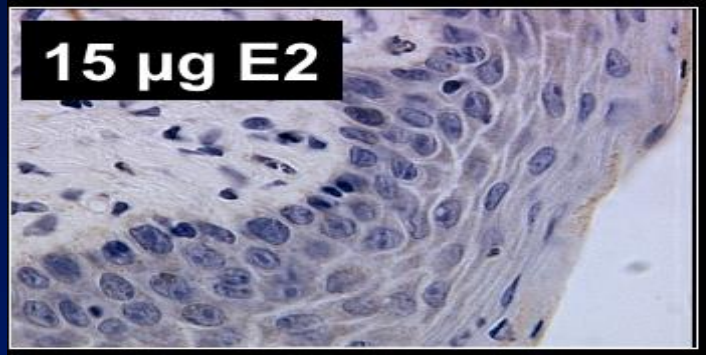

Photographed at 400X
Gill's hematoxylin stain
Stereological Measurement:
Point Counting Grid

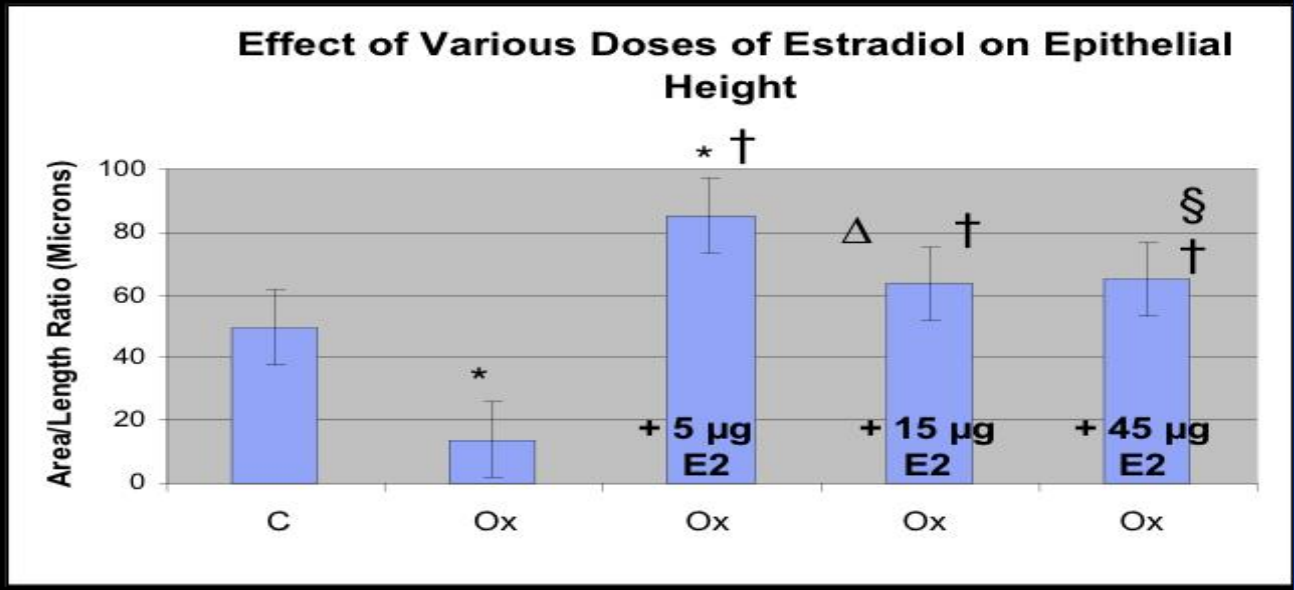

* P<0.001 vs Control

Δ p<0.01 versus 5µgE2

† p<0.001 versus Ox

§ p<0.05 versus 5µgE2

Monica A. Pessina, Richard F. Hoyt, Jr., Irwin Goldstein, and Abdulmaged M. TraishEndocrinology 147(1):61-

Differential Effects of Estradiol on Vaginal Structural Integrity

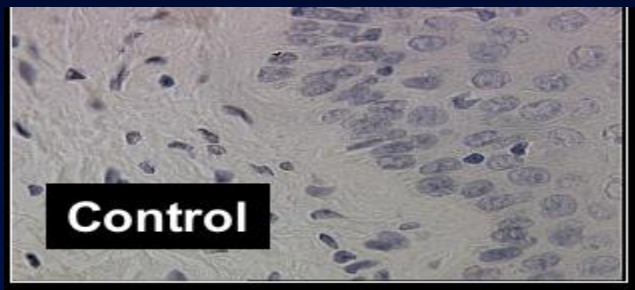

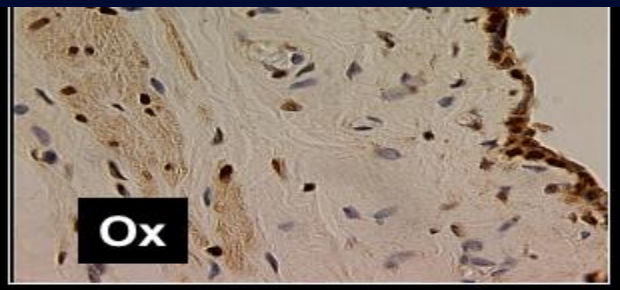

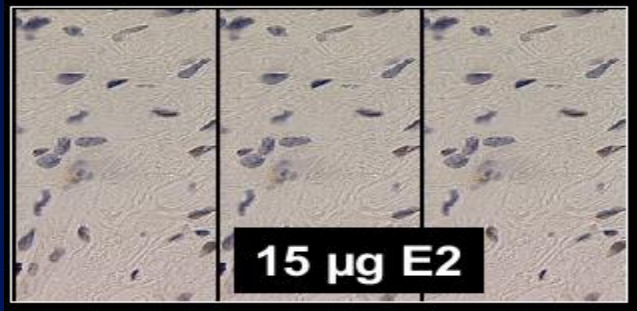

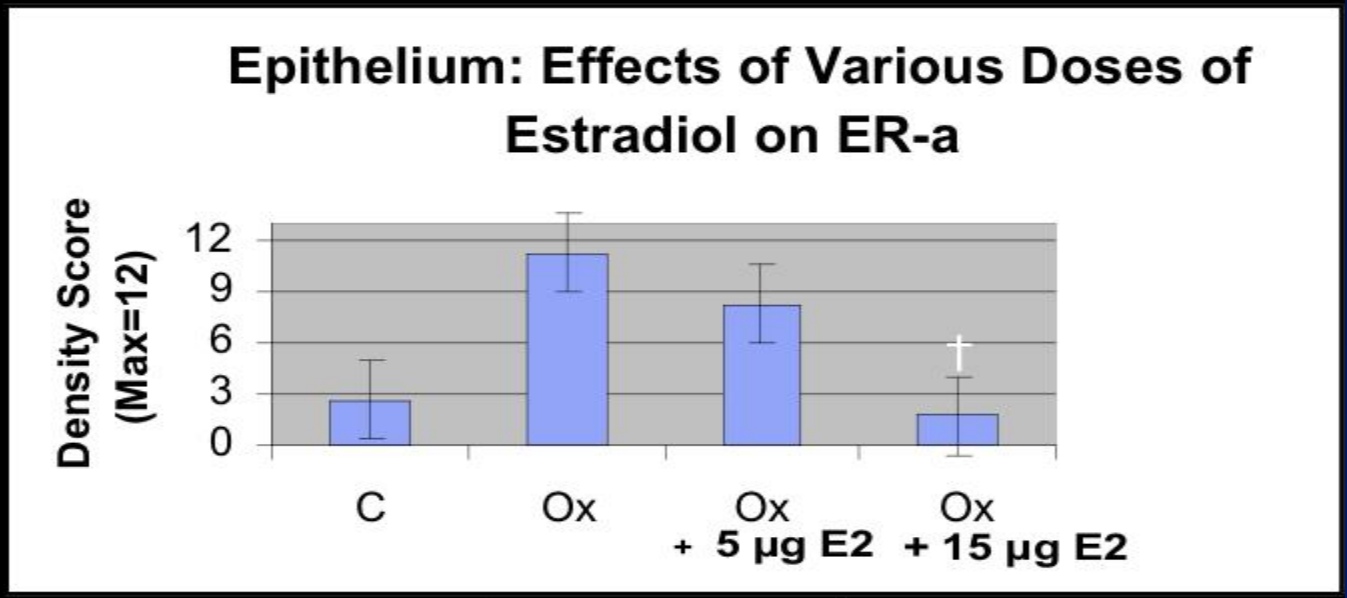

* P<0.01 vs Control

† p<0.01 versus Ox

Slides immunostained for ER-alpha using ABC method with DAB. Slides photographed at 400X

Effects of estradiol on the proportion of ER-αimmunoreactive cells in the epithelium

Monica A. Pessina, Richard F. Hoyt, Jr., Irwin Goldstein, and Abdulmaged M. TraishEndocrinology 147(1):61-

Vaginal Smear and Wet Mount Examination – Estrogen Milieu

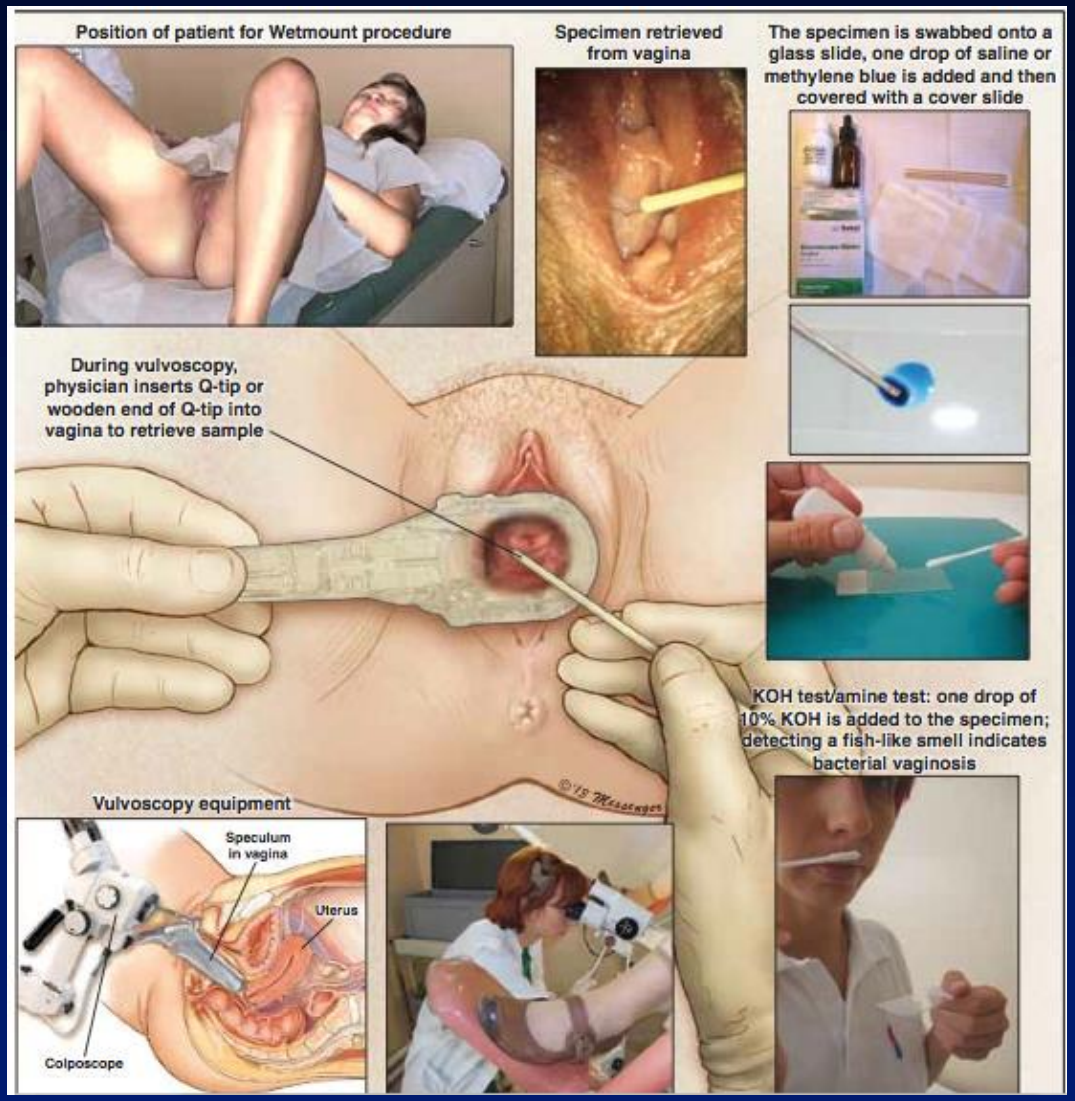

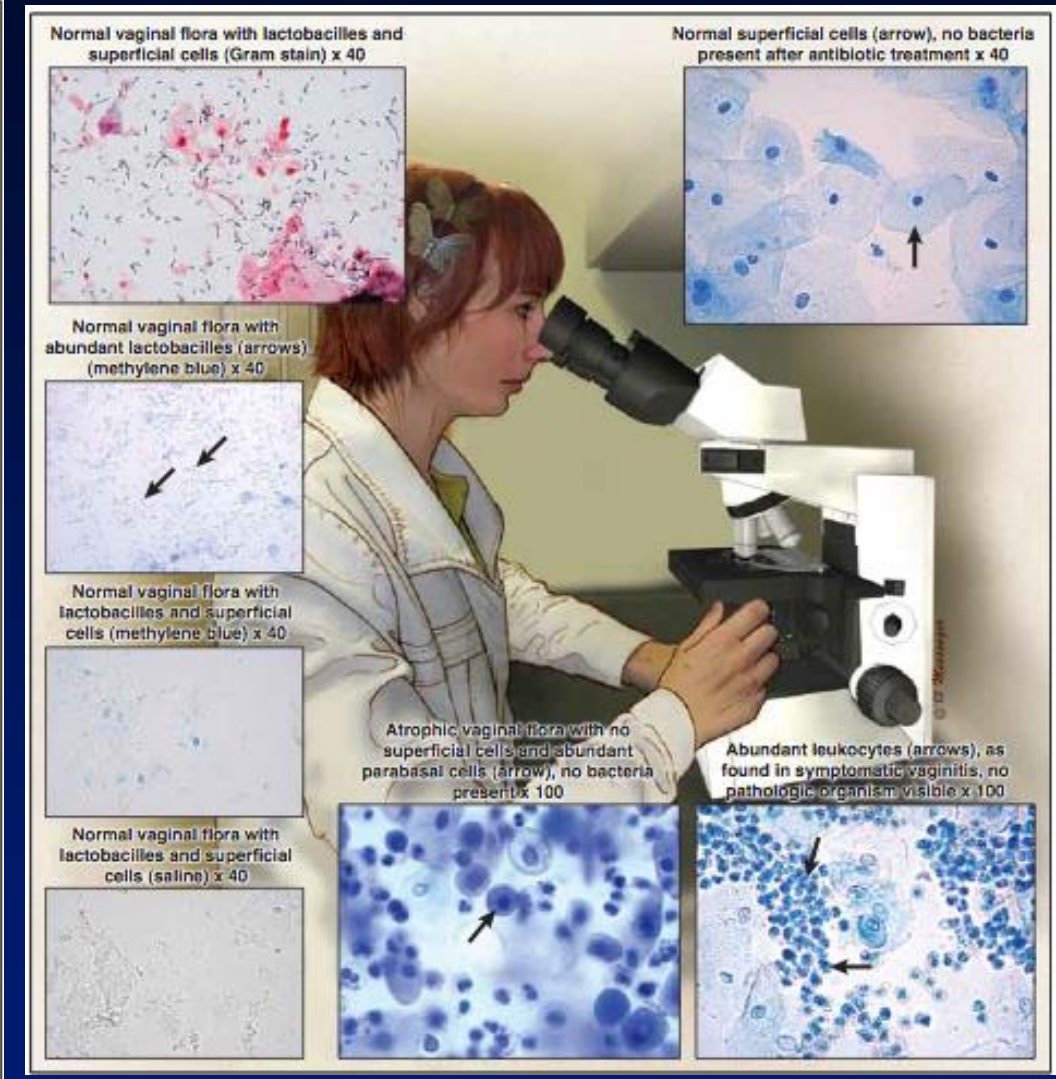

Wet Mount - Surgical Techniques J Sex Med 2013

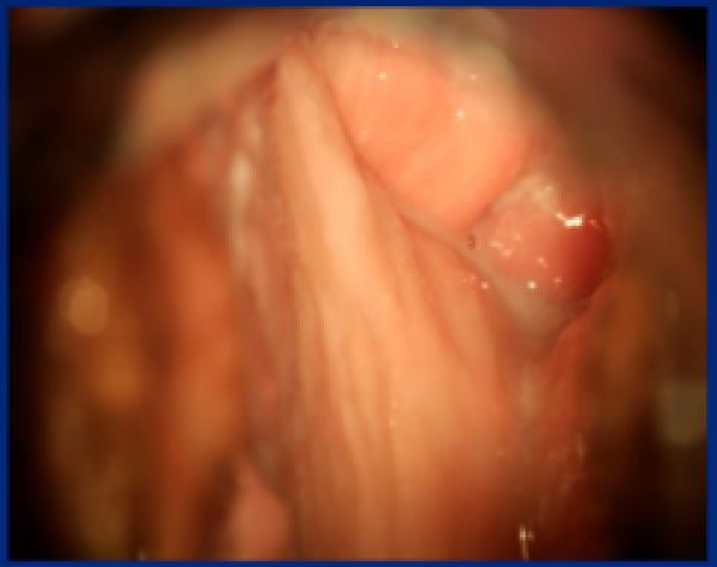

Reduced vaginal rugae, pH >5

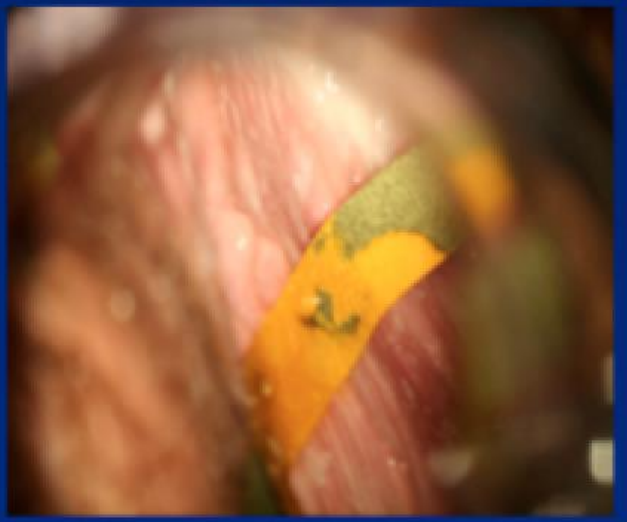

Robust vaginal rugae, pH 4

Anatomy	Normal (0)	Mild (1)	Moderate (2)	Severe (3)
Labia majora, minora	Normal for parity, coital activity and anatomic variation	Mild loss of labia	Moderate loss of labia, (especially inferior aspect of labia minora)	Severe loss of labia (labia minora mostly resorbed)
Clitoris	Normal glans and hood	Mild decrease in size	Moderate decrease in size	Severe decrease in size; phimosis or obliteration of clitoris
Urethra	Normal size and position	Mild urethral prominence	Moderate urethral prominence	Severe urethral prominence; urethra large relative to introitus
Introitus	Normal for parity, coital activity and anatomic variation	Mild decrease in size of introitus	Moderate decrease in size of introitus (moderate stenosis, narrowing)	Severe decrease in size of introitus (severe stenosis, narrowing; possible fibrotic band)
Vagina	Normal caliber and depth for parity, coital activity, and anatomic variation	Mild decrease in width and depth	Moderate decrease in width and depth	Severe decrease in width and depth
Tissue Characteristics				
Rugae & Elasticity	Normal (rugae present, nml elasticity)	Mildly decreased rugae and elasticity	Moderately decreased rugae and elasticity	No rugae or elasticity (fibrotic)
Lubrication	Normal moisture and secretions	Mildly decreased moisture and secretions	Moderate dryness	Severe dryness
Tissue integrity	Intact epithelium (no friability or petechiae)	Mild friability (bleeding and/or petechiae with vigorous contact)	Moderate friability (bleeding and/or petechiae with moderate contact)	Severe friability, (bleeding and/or petechiae with minimal contact)
Color	Normal	Mild pallor	Moderate pallor	Severe pallor

Anatomy

G-spot
Clitoris Glans, Clitoral Corona, Clitoral Frenula
Corpora Spongiosa (Vestibular Bulbs)
Clitoris Shaft, Clitoris Crus
Female Prostate, Peri-urethral Tissue
Cervix
Vulva
Vestibule
Vagina
Urethral Meatus/Urethral Glans
Sacral and Lumbar Spinal Cord

Urethral Meatus, Urethral Glans

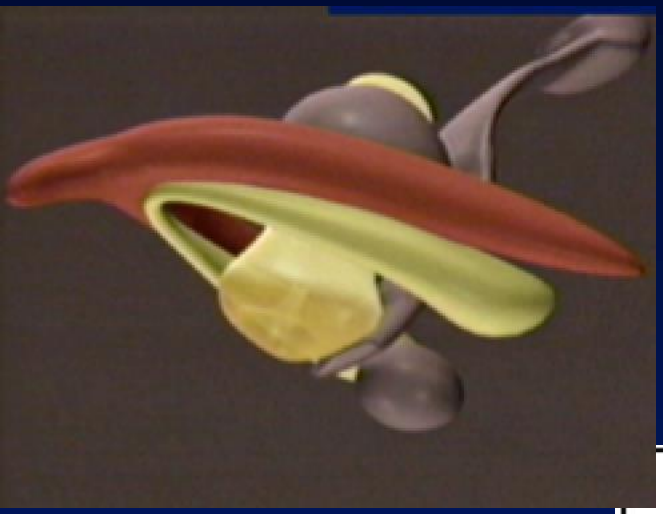

	Ejaculate analysis	urine analysis
PSA	213 ng/ml	0.8 ng/ml
Creatinine	33.0 mg/dl	178.0 mg/dl
PAP	329 U/l	42 U/l
PSAP	271 U/l	37/U/l
Creatinine	30.5 mg/dl	223,7 mg/dl

US - 3 cm long excretory duct between urethra and anterior vaginal wall which ended at the level of the urethral meatus.

Endoscopy - blind ending after 3 cm

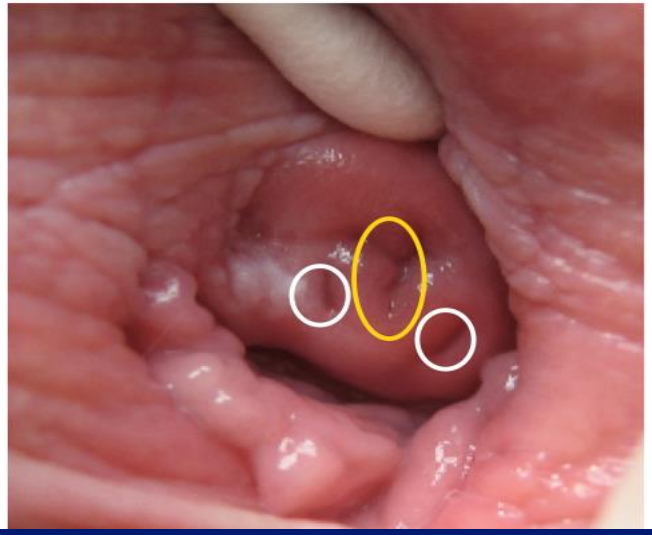

Peri-urethral Glans (Meatus) Pathology

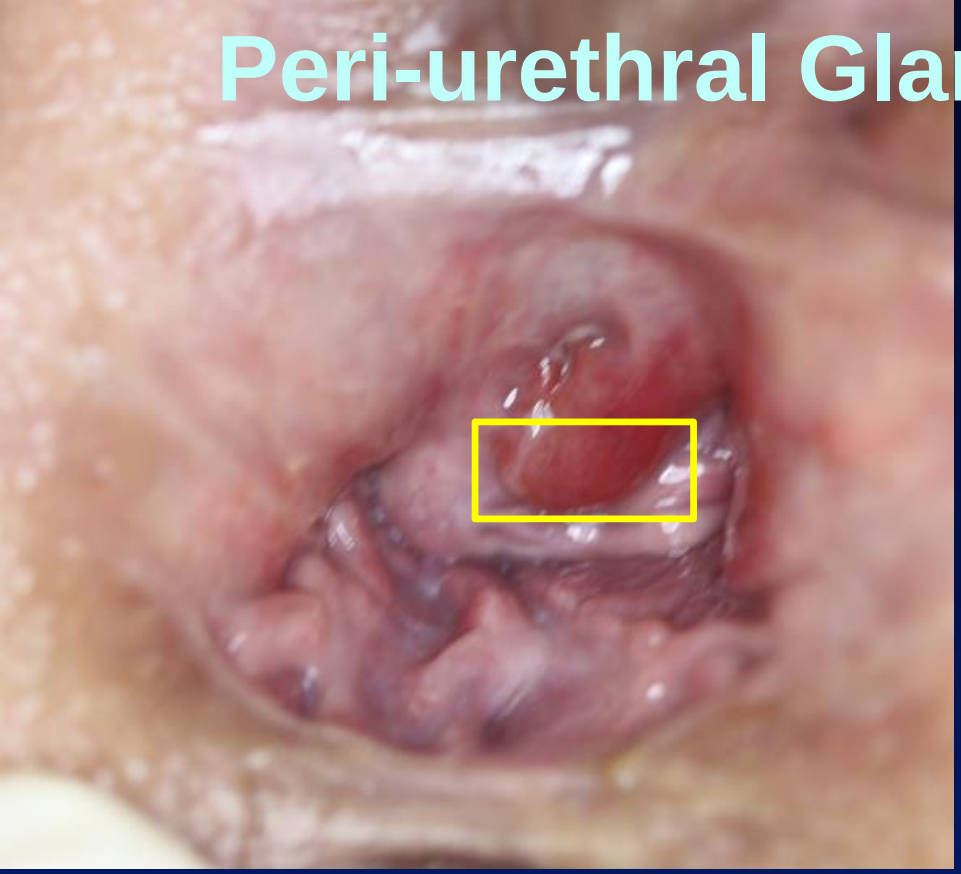

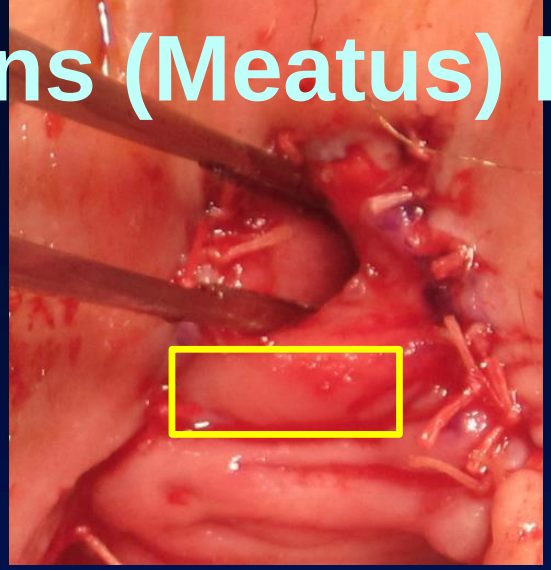

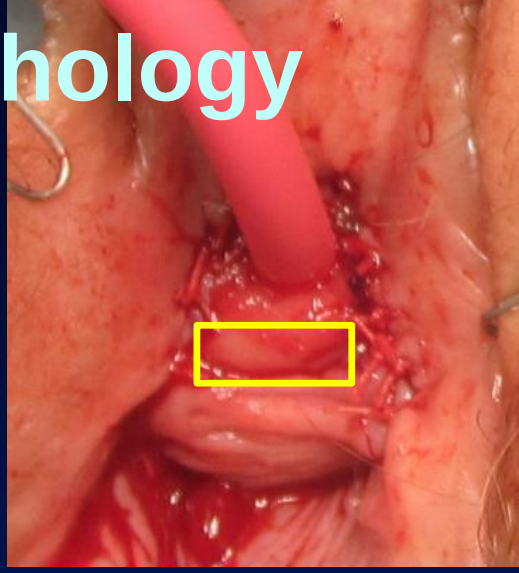

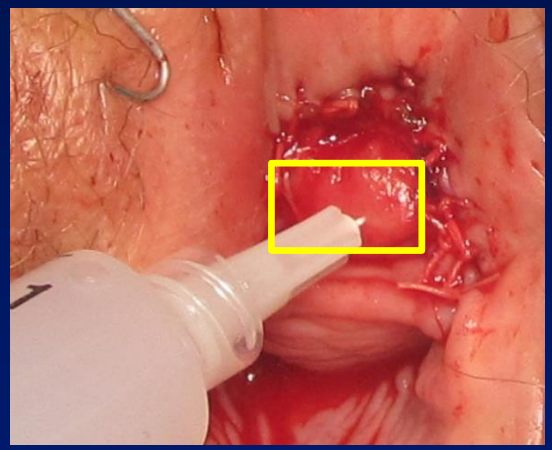

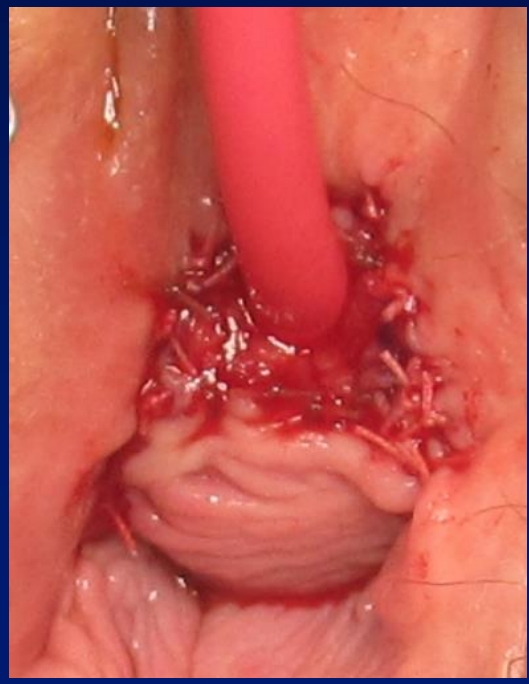

Urethral caruncle

Peri-urethral Glans (Meatus) Pathology

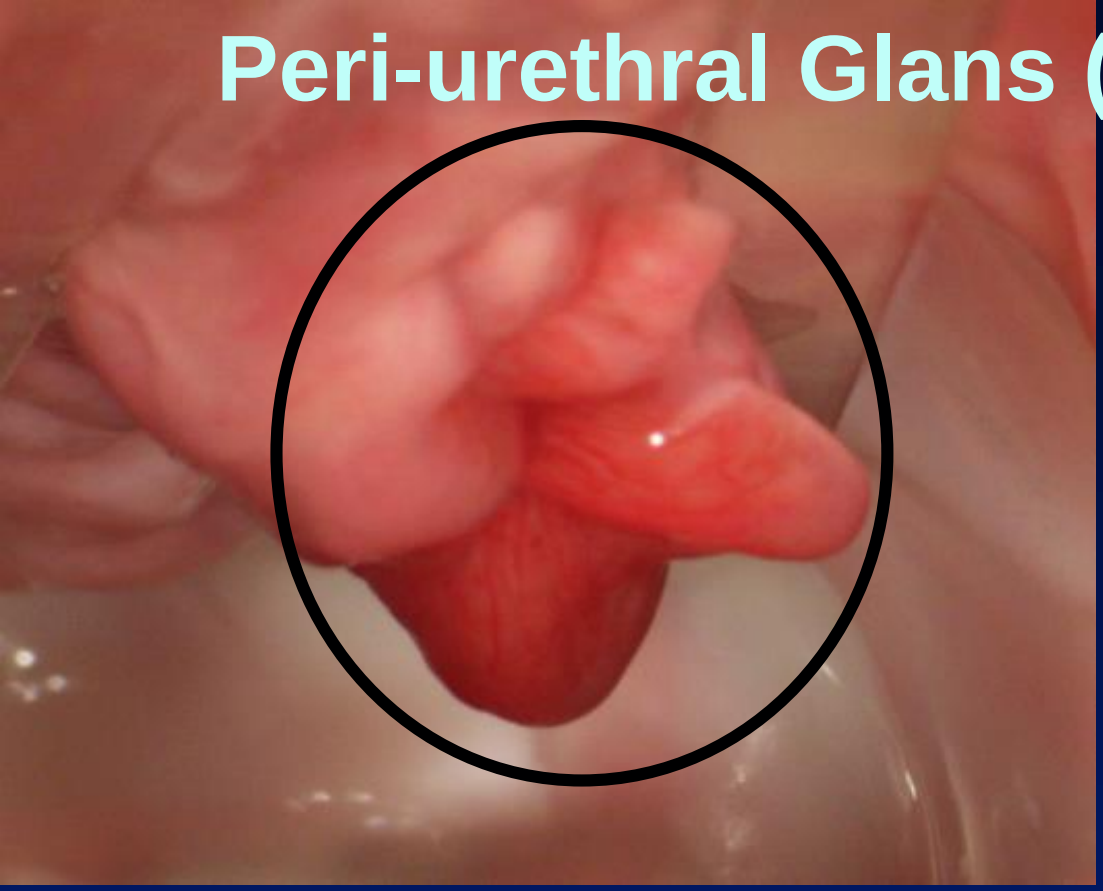

Norrmal Peri-urethral Glans (Meatus)

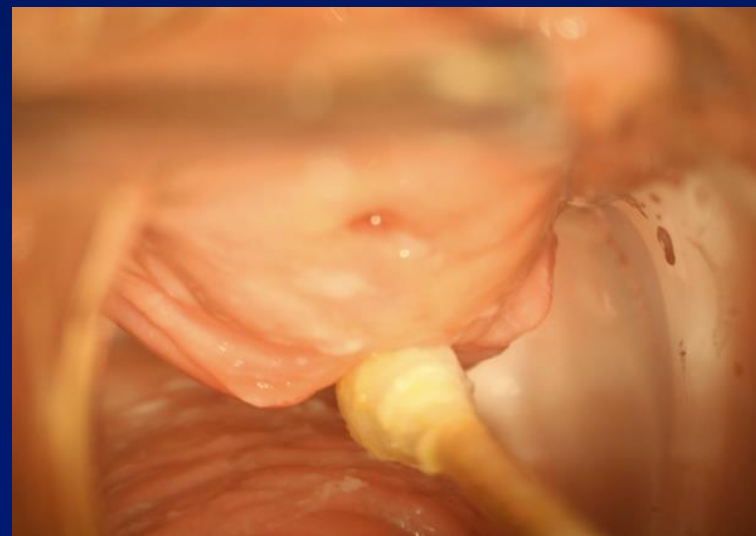

Anatomy

G-spot
Clitoris Glans, Clitoral Corona, Clitoral Frenula
Corpora Spongiosa (Vestibular Bulbs)
Clitoris Shaft, Clitoris Crus
Female Prostate, Peri-urethral Tissue
Cervix
Vulva
Vestibule
Vagina
Urethral Meatus/Urethral Glans
Sacral and Lumbar Spinal Cord

Tarlov Cyst

Ser: 7/Img: 14
Loc: 7.7 mm
602 /1204
S
FFS
DC
GE M
A
P
AI
R
L
288 x 192/1.5 NEX
TR 5548/TE 98/Flip Angle 90
Thk 4 mm Spc 5 mm/FOV 28 cm
12:10:43
14/26 SAG T2 TF

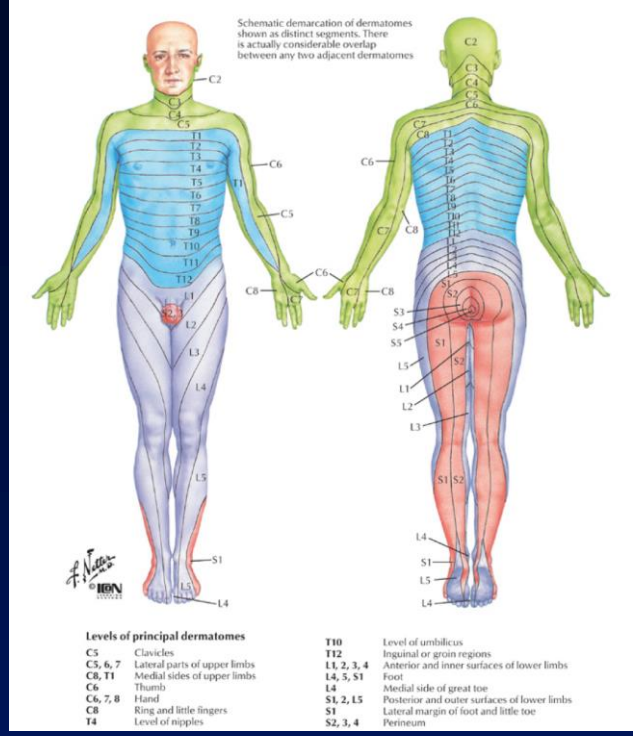
Schematic demarcation of dermatomes shown as distinct segments. There is actually considerable overlap between any two adjacent dermatomes
Levels of principal dermatomes
C5 Clavicles
C5, 6, 7 Lateral parts of upper limbs
C8, T1 Medial sides of upper limbs
C6 Thumb
C6, 7, 8 Hand
C8 Ring and little fingers
T4 Level of nipples
T10 Level of umbilicus
T12 Inguinal or groin regions
L1, 2, 3, 4 Anterior and inner surfaces of lower limbs
L4, 5, S1 Foot
L4 Medial side of great toe
S1, 2, L5 Posterior and outer surfaces of lower limbs
S1 Lateral margin of foot and little toe
S2, 3, 4 Perineum

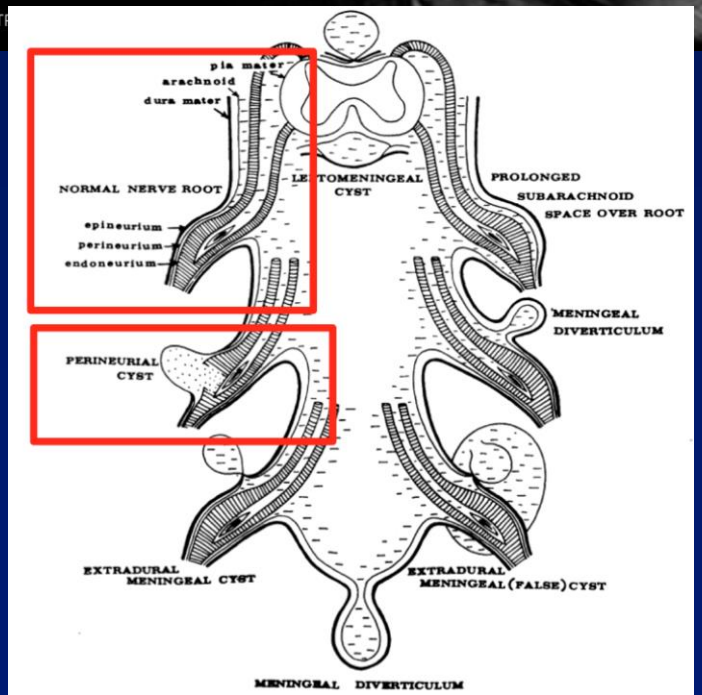
pia mater
arachnoid
dura mater
NORMAL NERVE ROOT
LEPTOMENINGEAL CYST
PROLONGED SUBARACHNOID SPACE OVER ROOT
epineurium
perineurium
endoneurium
MENINGEAL DIVERTICULUM
PERINEURIAL CYST
EXTRADURAL MENINGEAL CYST
EXTRADURAL MENINGEAL (FALSE) CYST
MENINGEAL DIVERTICULUM

Ser: 6/Img: 9
Loc: -60.0 mm
534 /1069
SA
FFS
DO
GE M
R
L
288 x 192/1.5 NEX
TR 6325/TE 100.2/Flip Angle 90
Thk 3 mm Spc 4 mm/FOV 26 cm
12:06:26
9/29 COR T2 FSAT OBL TR=6325 TE=100.232
S
A
P
Compressed 6:1
1.6x

Tarlov cysts

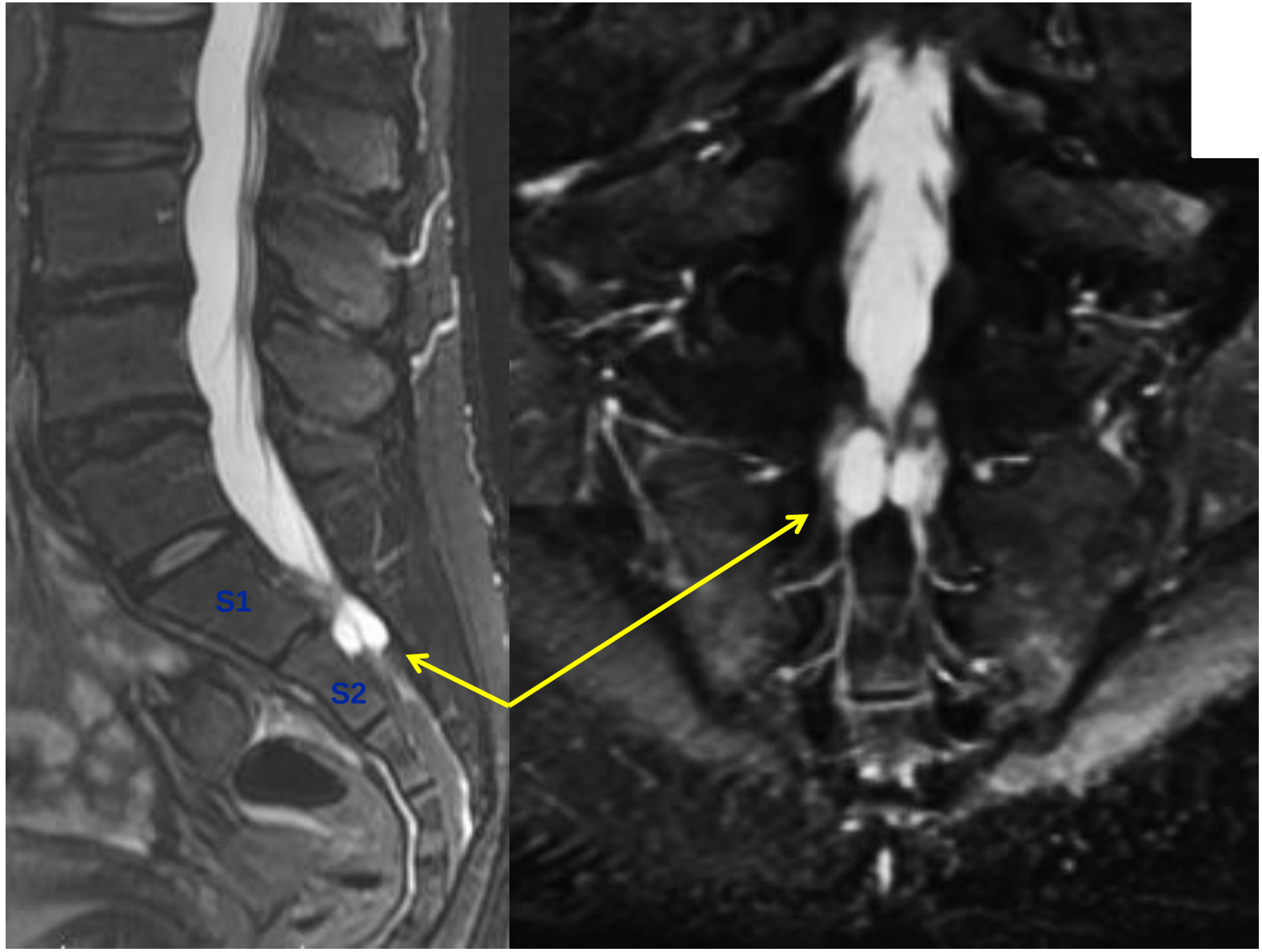

Sagittal

Frontal

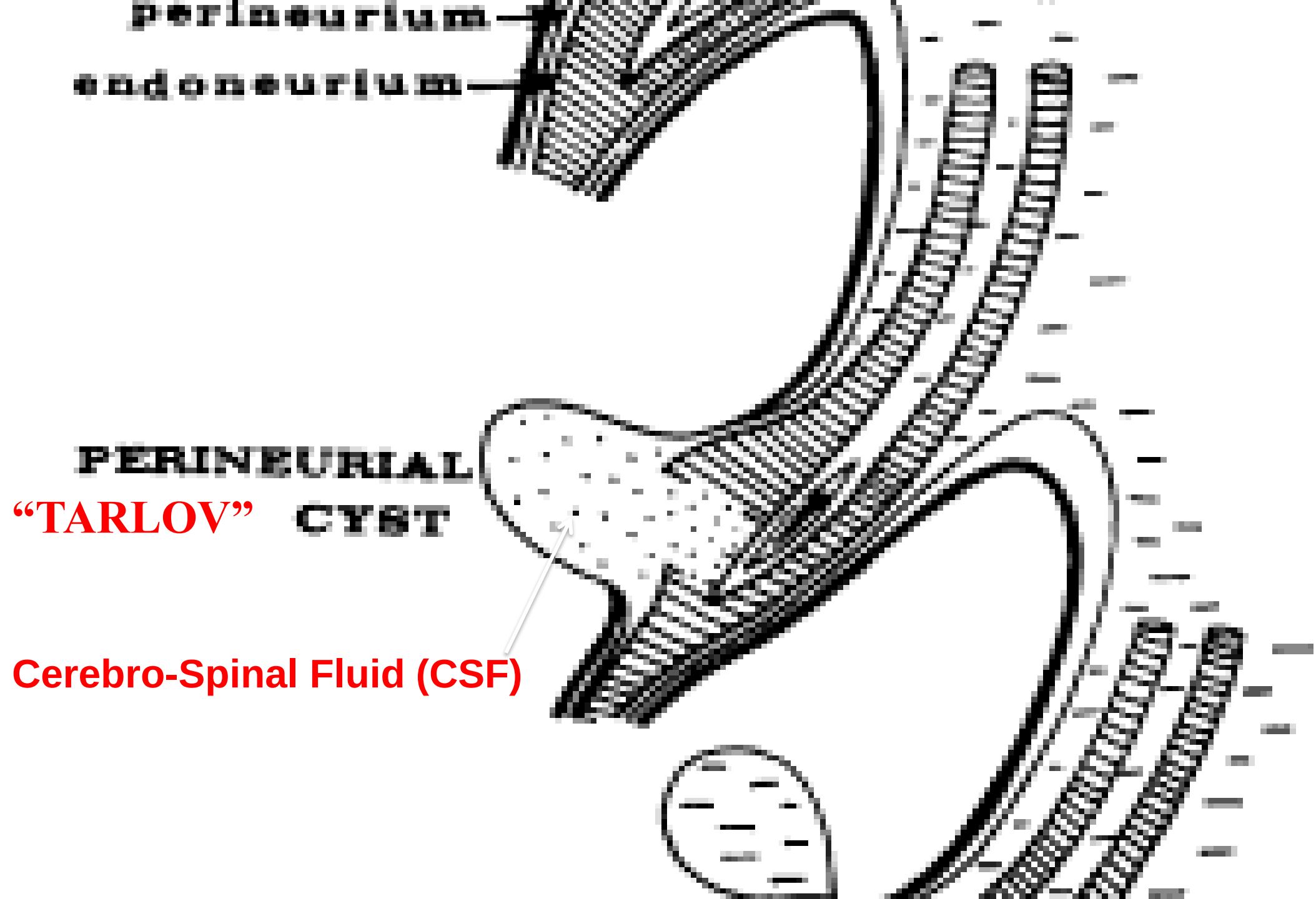
perineurium
endoneurium
PERINEURIAL
"TARLOV" CYST
Cerebro-Spinal Fluid (CSF)

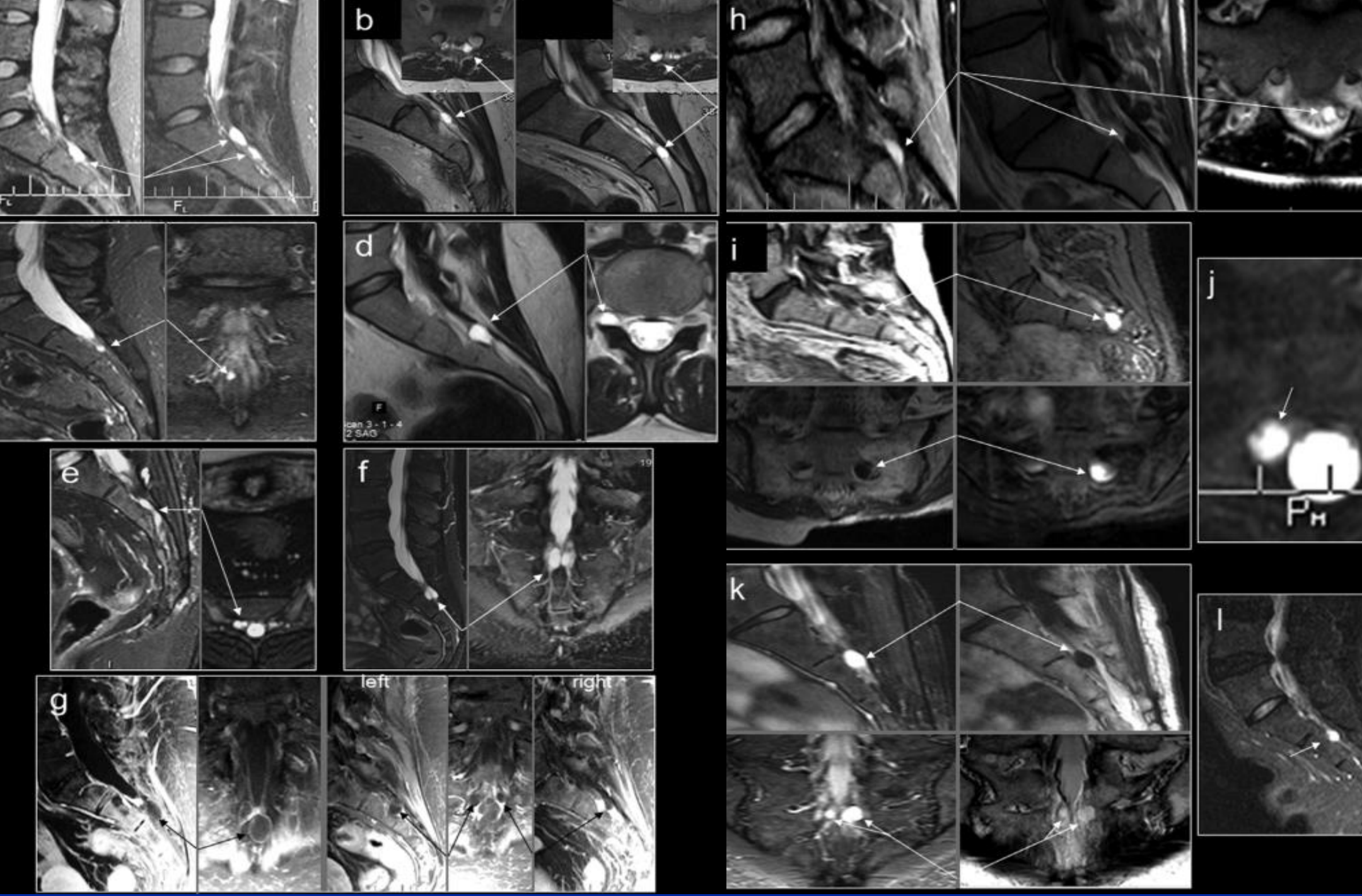
b
d
h
i
j
e
f
g
k
l
left
right

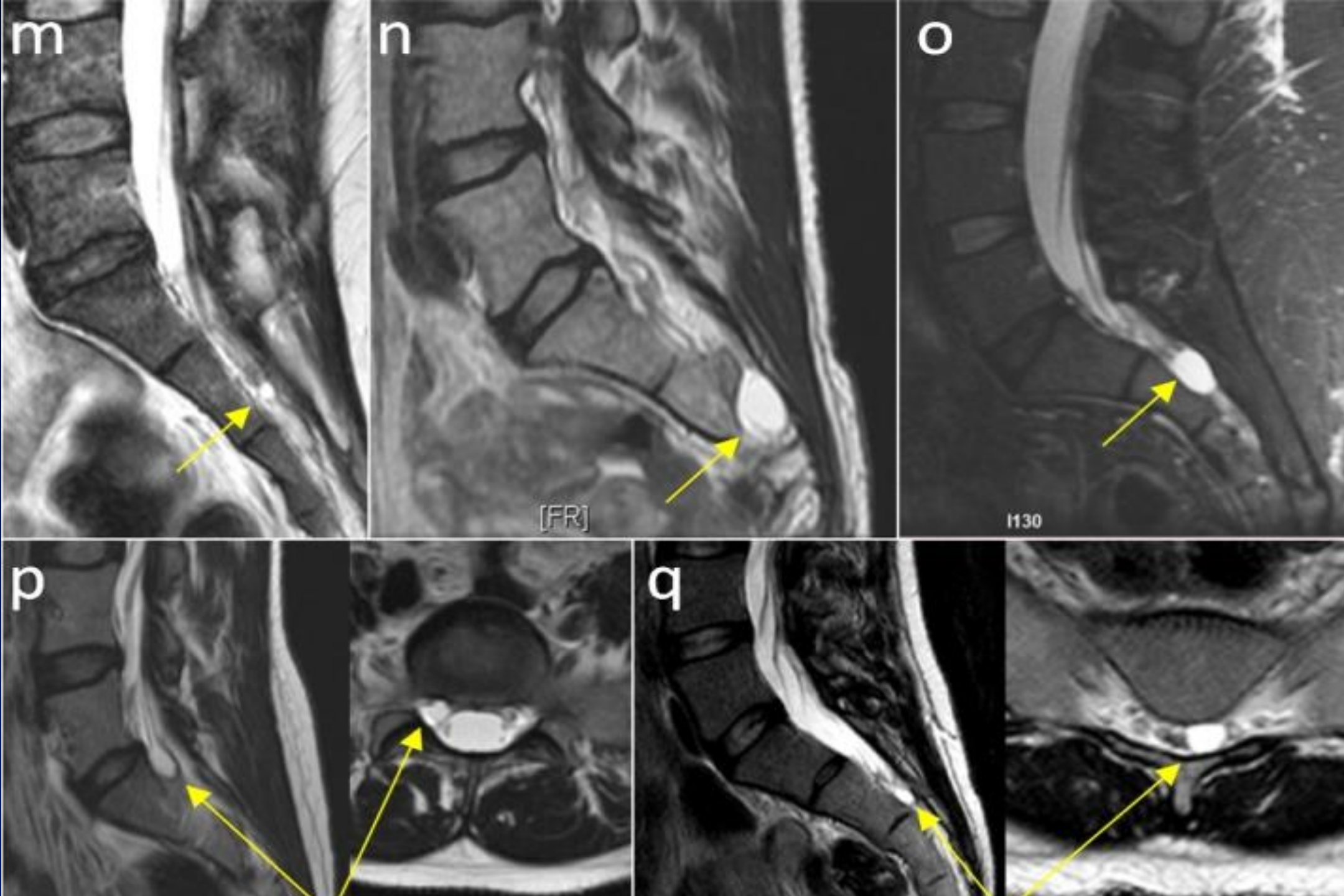
m
n
o
[FR]
I130
p
q

Diagnostic Testing

Endocrine

Neurologic

Vascular

9 Blood Tests: Testosterone, SHBG, Dihydrotestosterone, Estradiol, Progesterone, LH, FSH, TSH, prolactin

Total testosterone, SHBG, *calculated free testosterone (ng/dl)*	→	Use free testosterone calculator (0.6 - 0.8)
DHT (ng/dl)	→	Suspicious in lower tertile
Peri/post-menopausal Estradiol (pg/ml)	→	Aim for 35 - 50 pg/ml
Peri/post-menopausal Progesterone (ng/ml)	→	Aim for 1 ng/ml
LH/FSH (mIU/ml)	→	Range established
TSH (mIU/L)	→	Suspicious > 3.0
Prolactin (ng/ml)	→	Range established

Diagnostic Testing of Female Sexual Dysfunction

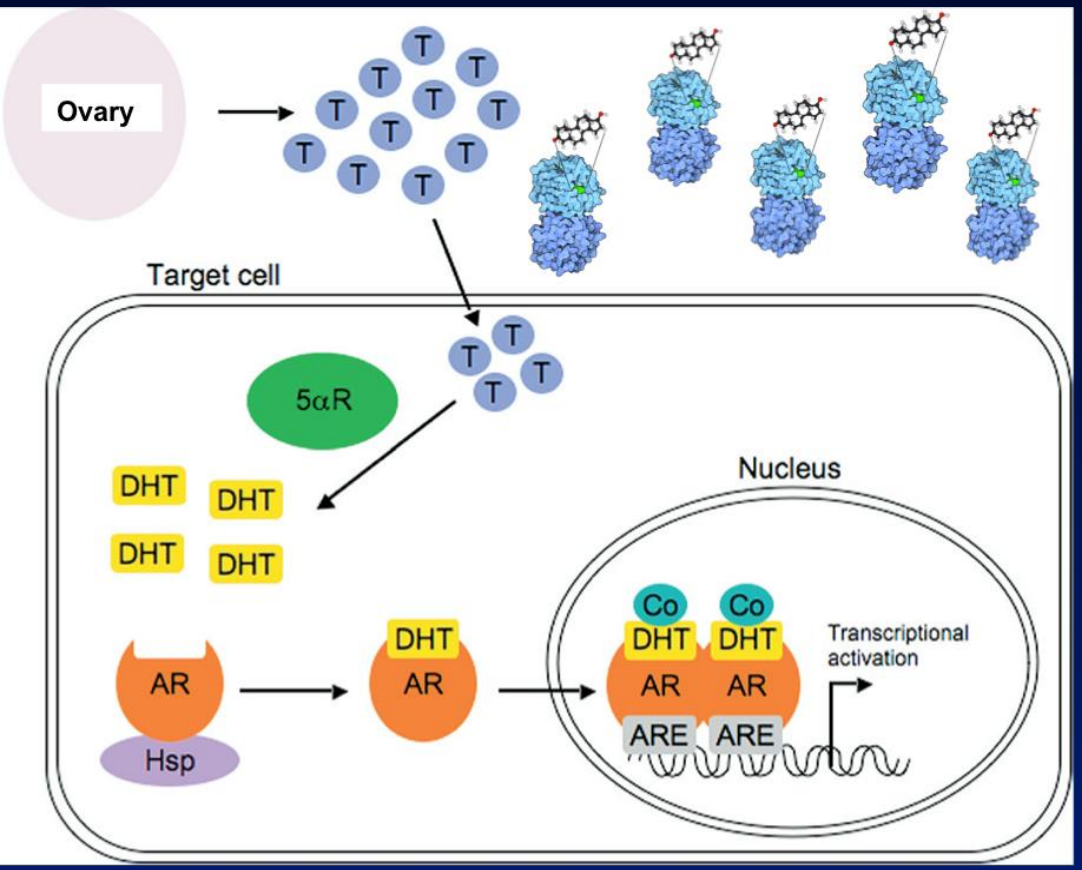

SHBG = 25 nmol/L

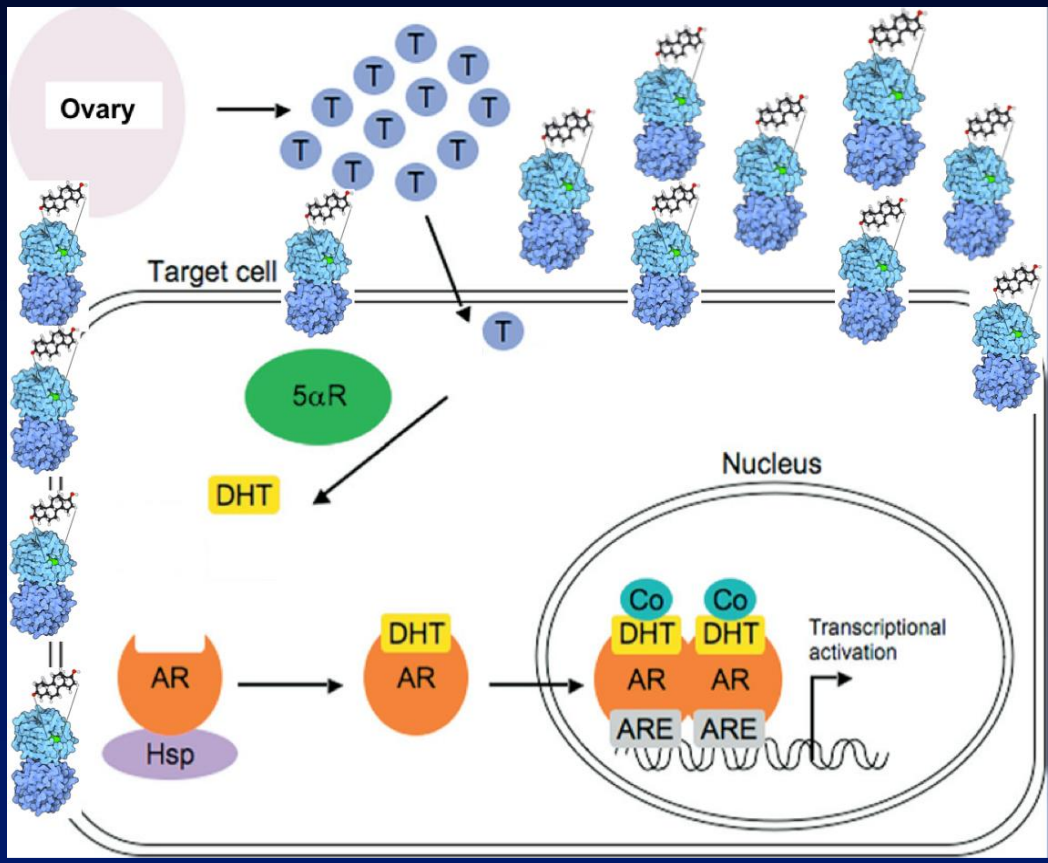

SHBG = 168 nmol/L

Free & Bioavailable Testosterone calculator

These calculated parameters more accurately reflect the level of bioactive testosterone than does the sole measurement of total serum testosterone. Testosterone and dihydrotestosterone (DHT) circulate in plasma unbound (free approximately 2 - 3%) ,bound to specific plasma proteins (sex hormone-binding globulin SHBG) and weakly bound to nonspecific proteins such as albumin. The SHBG-bound fraction is biologically inactive because of the high binding affinity of SHBG for testosterone. Free testosterone measures the free fraction, bioavailable testosterone includes free plus weakly bound to albumin.

Albumin	4.3	g/dL
SHBG		nmol/L
Testosterone		ng/dL

Calculate

Explanation and examples

Free Testosterone	
Bioavailable Testosterone	

Disclaimer: Results from this calculator should NOT be solely relied upon in making (or refraining from making) any decision in any case/ circumstances without the prior consultation of experts or professional persons. No responsability whatsoever is assumed for its correctness or suitability for any given purpose.

WARNING! The calculated free and bioavailable testosterone are reliable in most clinical situations, but should not be relied upon in situations with potential massive interference by steroids binding to SHBG; e.g. in women during pregnancy, in men during treatment inducing high levels of DHT (e.g. transdermal DHT, oral testosterone) or mesterolon

This calculator was developed at the Hormonology department, University Hospital of Ghent, Belgium. If you have suggestions to improve this calculator, or for further questions or help contact us Dr. Tom Fiers or Prof. Dr. J.M. Kaufman

Calculated free testosterone calculator: http://www.issam.ch/freetesto.htm

For women with suspected androgen deficiency

Free & Bioavailable Testosterone calculator

For women with suspected androgen deficiency

These calculated parameters more accurately reflect the level of bioactive testosterone than does the sole measurement of total serum testosterone. Testosterone and dihydrotestosterone (DHT) circulate in plasma unbound (free approximately 2 - 3%) ,bound to specific plasma proteins (sex hormone-binding globulin SHBG) and weakly bound to nonspecific proteins such as albumin. The SHBG-bound fraction is biologically inactive because of the high binding affinity of SHBG for testosterone. Free testosterone measures the free fraction, bioavailable testosterone includes free plus weakly bound to albumin.

Albumin	4.3	g/dL
SHBG	25	nmol/L
Testosterone	40	ng/dL

Calculate

Explanation and examples

Free Testosterone	0.838 ng/dL = 2.1 %
Bioavailable Testosterone	19.7 ng/dL = 49.1 %

Normal calculated free testosterone is 0.6 - 0.8 ng/dl

Disclaimer: Results from this calculator should NOT be solely relied upon in making (or refraining from making) any decision in any case/ circumstances without the prior consultation of experts or professional persons. No responsability whatsoever is assumed for its correctness or suitability for any given purpose.

WARNING! The calculated free and bioavailable testosterone are reliable in most clinical situations, but should not be relied upon in situations with potential massive interference by steroids binding to SHBG; e.g. in women during pregnancy, in men during treatment inducing high levels of DHT (e.g. transdermal DHT, oral testosterone) or mesterolon

Calculated free testosterone calculator: http://www.issam.ch/freetesto.htm

For women with suspected androgen deficiency

Free & Bioavailable Testosterone calculator

For women with suspected androgen deficiency

These calculated parameters more accurately reflect the level of bioactive testosterone than does the sole measurement of total serum testosterone. Testosterone and dihydrotestosterone (DHT) circulate in plasma unbound (free approximately 2 - 3%) ,bound to specific plasma proteins (sex hormone-binding globulin SHBG) and weakly bound to nonspecific proteins such as albumin. The SHBG-bound fraction is biologically inactive because of the high binding affinity of SHBG for testosterone. Free testosterone measures the free fraction, bioavailable testosterone includes free plus weakly bound to albumin.

Albumin	4.3	g/dL
SHBG	168	nmol/L
Testosterone	40	ng/dL

Calculate

Explanation and examples

Free Testosterone	0.21 ng/dL = 0.526 %
Bioavailable Testosterone	4.93 ng/dL = 12.3 %

Normal calculated free testosterone is 0.6 - 0.8 ng/dl

Disclaimer: Results from this calculator should NOT be solely relied upon in making (or refraining from making) any decision in any case/ circumstances without the prior consultation of experts or professional persons. No responsability whatsoever is assumed for its correctness or suitability for any given purpose.

WARNING! The calculated free and bioavailable testosterone are reliable in most clinical situations, but should not be relied upon in situations with potential massive interference by steroids binding to SHBG; e.g. in women during pregnancy, in men during treatment inducing high levels of DHT (e.g. transdermal DHT, oral testosterone) or mesterolon

Calculated free testosterone calculator: http://www.issam.ch/freetesto.htm

FIG. 2. Correlation of various methods for measuring free T

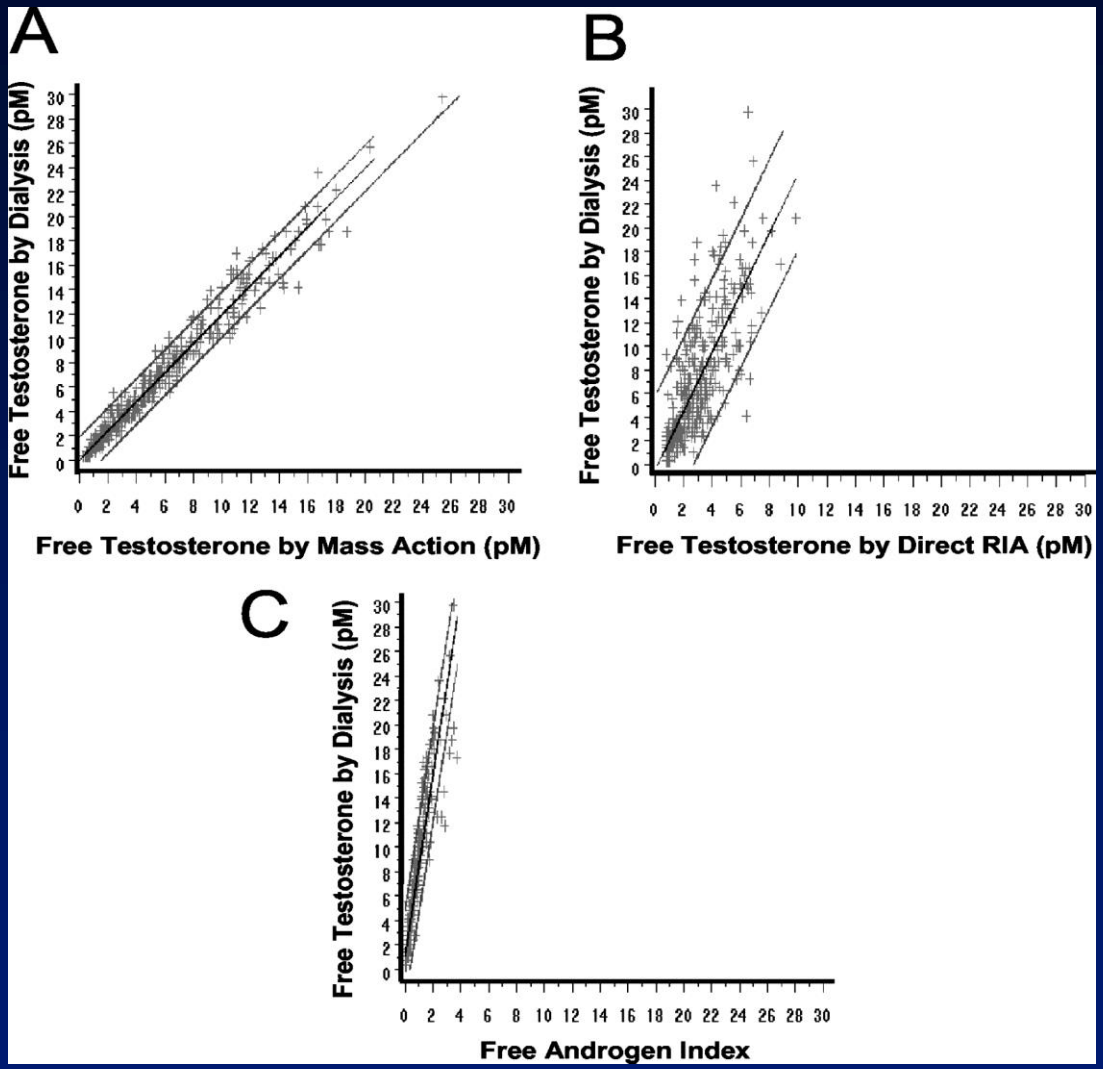

Miller, K. K. et al. J Clin Endocrinol Metab 2004;89:525-533

THE JOURNAL OF CLINICAL ENDOCRINOLOGY & METABOLISM

Copyright ©2004 The Endocrine Society

Int J Impot Res. 2004 Apr;16(2):112-20.

Serum androgen levels in healthy premenopausal women with and without sexual dysfunction: Part A. Serum androgen levels in women aged 20-49 years with no complaints of sexual dysfunction.

Guay A, Munarriz R, Jacobson J, Talakoub L, Traish A, Quirk F, Goldstein I, Spark R.

Center for Sexual Function, Lahey Clinic Northshore, One Essex Center Drive, Peabody, MA 01960, USA. andre.t.guay@lahey.org

Abstract

Androgen insufficiency is a recognized cause of sexual dysfunction in men and women. Age-related decrements in adrenal and gonadal androgen levels also occur naturally in both sexes. At present, it is unclear if a woman's low serum androgen level is a reflection of the expected normal age-related decline or indicative of an underlying androgen-deficient state. We studied premenopausal women with no complaints of sexual dysfunction to help define a normal female androgen profile. In all, 60 healthy, normally menstruating women, ages 20-49 y, were studied. The Abbreviated Sexual Function Questionnaire was administered along with a detailed interview. Radioimmunoassay measurements of morning serum testosterone (T), free testosterone (fT), dehydroepiandrosterone-sulfate (DHEAS), sex hormone-binding globulin (SHBG), and free androgen index (FAI) were measured during days 8-15 of the menstrual cycle. In women 20-49 y old without complaints of sexual dysfunction, serum androgen levels exhibit a progressive stepwise decline. Comparing values obtained in women age 20-29 y to those obtained in women 40-49 y, specific hormone decrements were DHEAS 195.6-140.4 microg/dl, serum T 51.5-33.7 ng/dl, fT 1.51-1.03 pg/ml. SHBG did not change significantly in women in this age group. The FAI reflected the age-related decrease in female androgen levels. The framework for the development of a female androgen profile in women with no complaints of sexual dysfunction has been established, and an age-related decrease in testosterone and its adrenal precursor, DHEAS, has been demonstrated. The FAI mirrors these decreases and its usefulness in clinical practice is confirmed. A precipitous decline in all androgens occurs after the decade of the 20s, yet SHBG does not show a significant change throughout the premenopausal years.

Hormonal Levels In Healthy Premenopausal Women

Age	20-29 (n=17)	30-39 (n=23)	40-49 (n=20)
DHEAS ug/dL	176.9-214.3	139.0-170.8	124.7-156.1
SHBG nmol/L	43.6-58.6	44.6-52.4	47.0-58.4
Total T ng/dL	45.5-57.5	27.6-39.8	27.0-38.6
Free Androgen Index (FAI)	3.72-4.96	2.04-2.96	1.98-2.94
Calculated Free T picomol/L	21.5-27.2	13.4-19.5	12.4-17.8
Calculated Free T ng/dl	0.6 - 0.8	0.4 - 0.6	0.4 - 0.6

Int J Impot Res. 2004 Apr;16(2):112-20.

Serum androgen levels in healthy premenopausal women with and without sexual dysfunction: Part A. Serum androgen levels in women aged 20-49 years with no complaints of sexual dysfunction.

Guay A, Munarriz R, Jacobson J, Talakoub L, Traish A, Quirk F, Goldstein I, Spark R.

Why measure dihydrotestosterone

Testosterone 45 ng/dl (5 – 74)
SHBG 36 nmol/L (18 – 102)
cfT = 0.769 (0.6 – 0.8) ng/dl

DHT = 22 (4-26)

Upper tertile - Testosterone
Normal - SHBG
Upper Tertile - cFT

Upper tertile – DHT* - if endocrinologic FSD – downstream AR concern

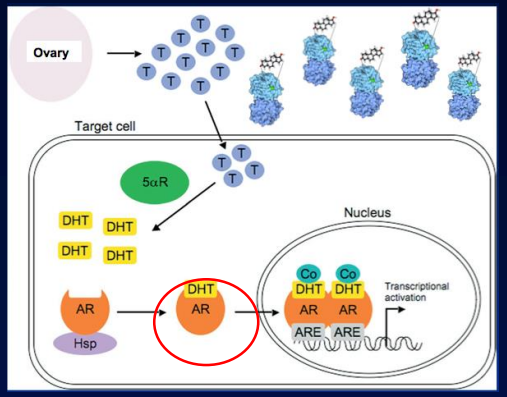

Testosterone 4 ng/dl (5 – 74)
SHBG 212 nmol/L (18 – 102)
cfT = 0.017 (0.6 – 0.8) ng/dl

DHT = 3 (4-26)

Low - Testosterone
Elevated - SHBG
Very Low - cFT

Low DHT

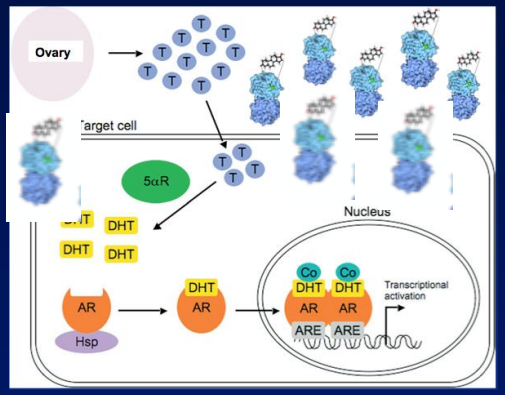

Testosterone 52 ng/dl (5 – 74)
SHBG 45 nmol/L (18 – 102)
cfT = 0.773 (0.6 – 0.8) ng/dl

DHT = 6 (4-26)

Upper tertile - Testosterone
Normal - SHBG
Upper tertile - cFT

Lower tertile DHT - if endocrinologic FSD – 5 alpha reductase deficiency/inactivity

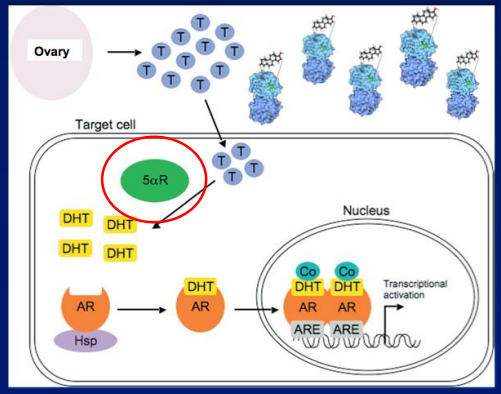

Upper tertile DHT * = associated with scalp hair loss, facial hair and acne

Courtesy Dr. I. Goldstein

Who is at risk for hormonally mediated vestibulodynia?

Figure 3. long alleles

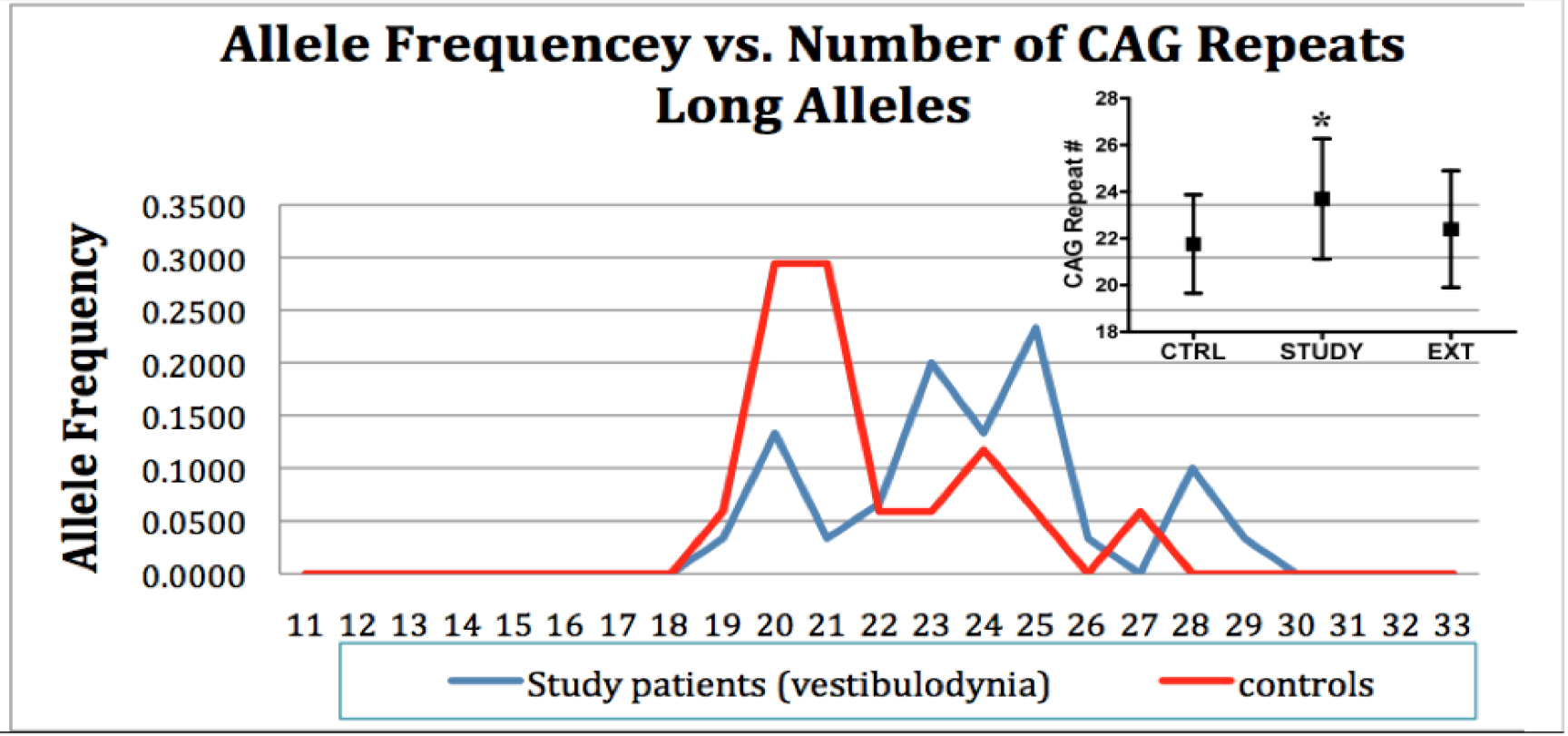

Diagnostic Testing of Female Sexual Dysfunction

Int J Impot Res. 2004 Apr;16(2):112-20.

Serum androgen levels in healthy premenopausal women with and without sexual dysfunction: Part A. Serum androgen levels in women aged 20-49 years with no complaints of sexual dysfunction.

Guay A, Munarriz R, Jacobson J, Talakoub L, Traish A, Quirk F, Goldstein I, Spark R.

Center for Sexual Function, Lahey Clinic Northshore, One Essex Center Drive, Peabody, MA 01960, USA. andre.t.guay@lahey.org

Abstract

Androgen insufficiency is a recognized cause of sexual dysfunction in men and women. Age-related decrements in adrenal and gonadal androgen levels also occur naturally in both sexes. At present, it is unclear if a woman's low serum androgen level is a reflection of the expected normal age-related decline or indicative of an underlying androgen-deficient state. We studied premenopausal women with no complaints of sexual dysfunction to help define a normal female androgen profile. In all, 60 healthy, normally menstruating women, ages 20-49 y, were studied. The Abbreviated Sexual Function Questionnaire was administered along with a detailed interview. Radioimmunoassay measurements of morning serum testosterone (T), free testosterone (fT), dehydroepiandrosterone-sulfate (DHEAS), sex hormone-binding globulin (SHBG), and free androgen index (FAI) were measured during days 8-15 of the menstrual cycle. In women 20-49 y old without complaints of sexual dysfunction, serum androgen levels exhibit a progressive stepwise decline. Comparing values obtained in women age 20-29 y to those obtained in women 40-49 y, specific hormone decrements were DHEAS 195.6-140.4 microg/dl, serum T 51.5-33.7 ng/dl, fT 1.51-1.03 pg/ml. SHBG did not change significantly in women in this age group. The FAI reflected the age-related decrease in female androgen levels. The framework for the development of a female androgen profile in women with no complaints of sexual dysfunction has been established, and an age-related decrease in testosterone and its adrenal precursor, DHEAS, has been demonstrated. The FAI mirrors these decreases and its usefulness in clinical practice is confirmed. A precipitous decline in all androgens occurs after the decade of the 20s, yet SHBG does not show a significant change throughout the premenopausal years.

Hormonal Levels In Healthy Premenopausal Women

Age	20-29 (n=17)	30-39 (n=23)	40-49 (n=20)
DHEAS ug/dL	176.9-214.3	139.0-170.8	124.7-156.1
SHBG nmol/L	43.6-58.6	44.6-52.4	47.0-58.4
Total T ng/dL	45.5-57.5	27.6-39.8	27.0-38.6
Free Androgen Index (FAI)	3.72-4.96	2.04-2.96	1.98-2.94
Calculated Free T picomol/L	21.5-27.2	13.4-19.5	12.4-17.8
Calculated Free T ng/dl	0.6 - 0.8	0.4 - 0.6	0.4 - 0.6

Int J Impot Res. 2004 Apr;16(2):112-20.

Serum androgen levels in healthy premenopausal women with and without sexual dysfunction: Part A. Serum androgen levels in women aged 20-49 years with no complaints of sexual dysfunction.

Guay A, Munarriz R, Jacobson J, Talakoub L, Traish A, Quirk F, Goldstein I, Spark R.

9 Blood Tests: Testosterone, SHBG, Dihydrotestosterone, Estradiol, Progesterone, LH, FSH, TSH, prolactin

Total testosterone, SHBG, *calculated free testosterone (ng/dl)*	→	Use free testosterone calculator (0.6 - 0.8)
DHT (ng/dl)	→	Suspicious in lower tertile
Peri/post-menopausal Estradiol (pg/ml)	→	Aim for 35 - 50 pg/ml
Peri/post-menopausal Progesterone (ng/ml)	→	Aim for 1 ng/ml
LH/FSH (mIU/ml)	→	Range established
TSH (mIU/L)	→	Suspicious > 3.0
Prolactin (ng/ml)	→	Range established

Diagnostic Testing of Female Sexual Dysfunction

What are the estradiol blood test values thoughout the life cycle?

Estradiol, progesterone, LH and FSH changes every 28 days

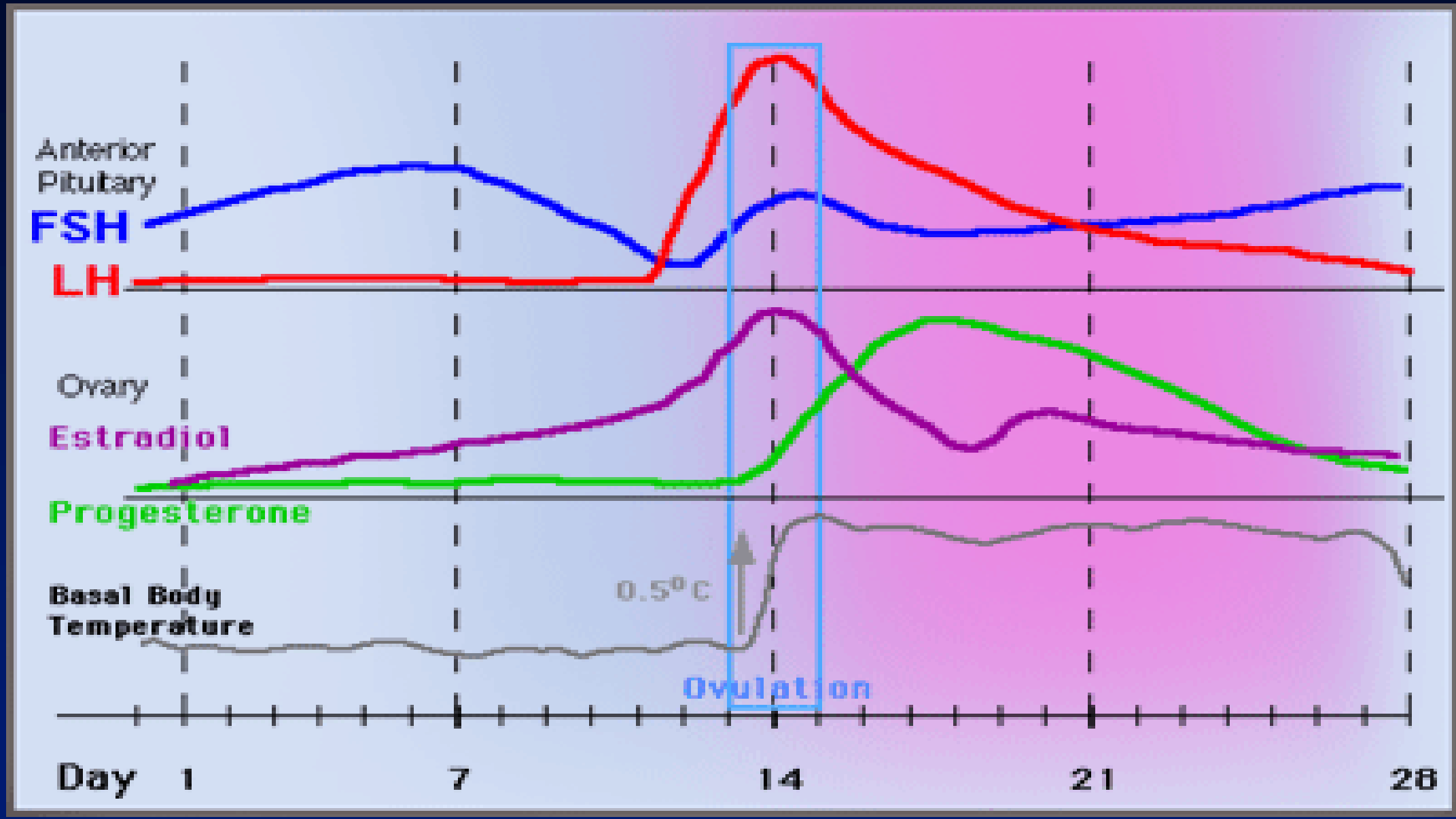

The Role of Drugs in Treating Female Sexual Dysfunction

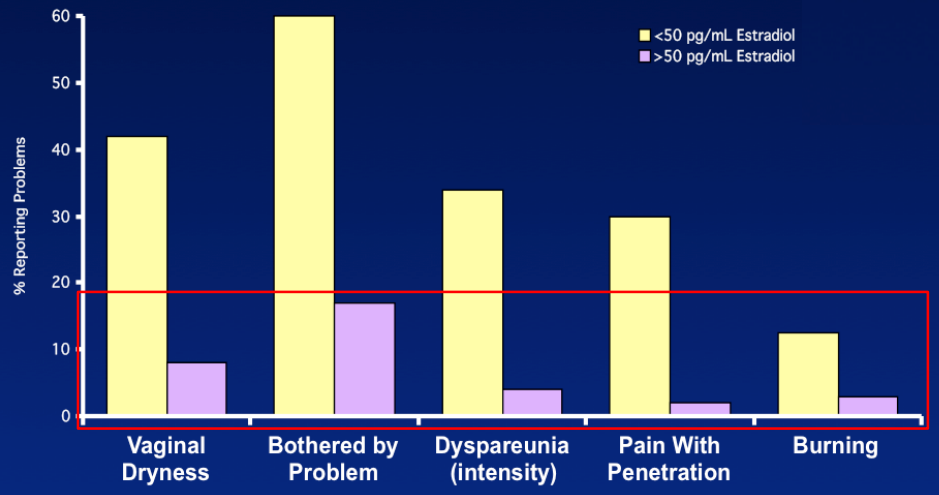

n = 93; significance not reported.
Sarrel PM. *J Womens Health Gend Based Med.* 2000;9:S25-S32.
Adapted from Sarrel PM. *Obstet Gynecol.* 1990;75:26S-30S.

Goal of estradiol replacement during menopause ~ 35 – 50 pg/dl

Goal of progesterone during menopause ~ 1 ng/ml

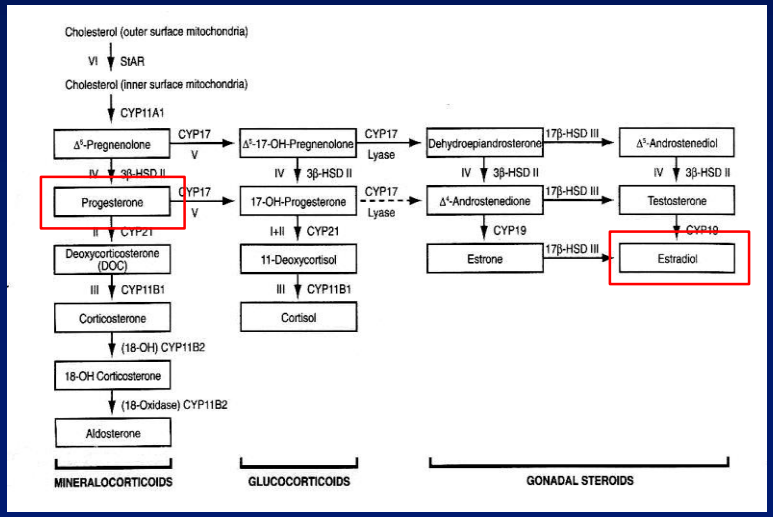

Endogenous estrogen, testosterone and progesterone levels in relation to breast cancer risk☆

Susan E. Hankinson [a,b,*], A. Heather Eliassen [a,b]

Table 1
Circulating levels of estradiol and risk of breast cancer: prospective studies in postmenopausal and premenopausal women

Study		Cases/controls	RR (95% CI) by category of circulating hormone levels[a] 1	2	3	4	5
Postmenopausal women							
EHBCCG[b], 2002		663/1765	1.0	1.4 (1.0–2.0)	1.2 (0.9–1.7)	1.8 (1.3–2.4)	2.0 (1.5–2.7)
Zeleniuch-Jacquotte, 2004[c]		297/563	1.0	1.6 (1.0–2.7)	1.2 (0.7–1.9)	1.7 (1.0–2.8)	2.5 (1.5–4.2)
Kaaks, 2005		677/1309	1.0	1.1 (0.8–1.5)	1.4 (1.0–2.0)	1.7 (1.2–2.4)	2.3 (1.6–3.2)
Missmer, 2004[d]		322/643	1.0	1.3 (0.9–1.9)	1.1 (0.7–1.7)	2.1 (1.5–3.2)	
Manjer, 2003		173/438	1.0	1.7 (0.7–1.7)			
Premenopausal women							
Kaaks, 2005		285/555	1.0	1.0 (0.6–1.5)	1.0 (0.7–1.6)	1.0 (0.7–1.5)	
Eliassen, 2006	Follicular	185/368	1.0	2.0 (1.1–3.6)	1.7 (1.0–3.2)	2.1 (1.1–4.1)	
	Luteal	175/349	1.0	1.2 (0.7–2.3)	1.8 (1.0–3.3)	1.0 (0.5–1.9)	

[a] Hormone data presented in quartiles or quintiles depending on the study, with the exception of estradiol in Manjer et al., where women in approximately the top 20% of estradiol levels were compared to women in the bottom 80% of levels.
[b] Endogenous Hormones and Breast Cancer Collaborative Group.
[c] Extension of study included in EHBCCG analysis; 168 new cases and 316 new controls included here.
[d] Extension of study included in EHBCCG analysis; 167 new cases and 333 new controls included here.

Journal of Steroid Biochemistry & Molecular Biology 106 (2007) 24–30

Progesterone in Menopause

Goal of estradiol replacement during menopause ~ 35 – 50 pg/dl

Goal of progesterone during menopause ~ 1 ng/ml

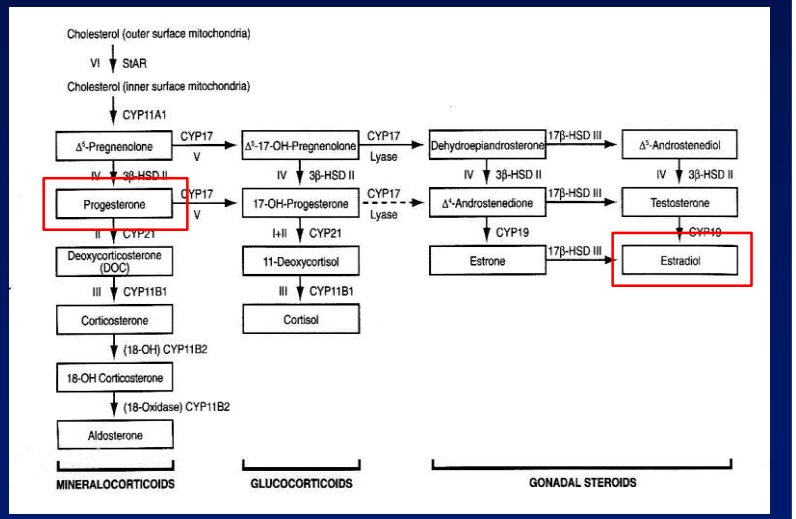

Progesterone has multiple non-reproductive functions in the central nervous system to regulate cognition, mood, inflammation, mitochondrial function, neurogenesis and regeneration, myelination and recovery from traumatic brain injury.

The non-reproductive functions of PRs have far-reaching implications for hormone therapy to maintain neurological health and function throughout menopausal aging.

Brinton RD, Thompson RF, Foy MR, Baudry M, Wang J, Finch CE, Morgan TE, Pike CJ, Mack WJ, Stanczyk FZ, Nilsen J. Progesterone receptors: form and function in brain. Front Neuroendocrinol. 2008 May;29(2):313-39.

Estradiol, progesterone, LH, FSH values in peri-menopause or menopause

Baseline	Post Rx
Estradiol 4 ng/dl (<30 pg/ml) Progesterone <0.2 (<1 ng/ml) LH 55 mIU/ml FSH 47 mIU/ml	Estradiol 48 ng/dl (<30 pg/ml) Progesterone 0.91 (<1 ng/ml) LH 45.5 mIU/ml FSH 38.7 mIU/ml

54 yo menopausal - low sexual interest, sexual pain

Pre Rx- Low estradiol, low progesterone, elevated LH/FSH

Rx - estradiol treatment with goal 35-50 pg/ml
Rx - progesterone treatment with goal ~ 1 ng/ml
LH/FSH in elevated state

	Baseline	10 days	20 days
Estradiol	112 ng/dl,	21 ng/dl,	178 ng/dl
Progesterone	0.3 ng/ml,	0.2 ng/ml,	0.3 ng/ml
LH mIU/ml	4.5	8.4	3.2
FSH mIU/m	2.7	6.8	2.1

37 yo woman - hysterectomy – bilateral ovaries spared – muted orgasm, sexual pain

Estradiol is being synthesized, no ovulation

Consider progesterone treatment

	Baseline	10 days	20 days
Estradiol	32 ng/dl,	24 ng/dl,	17 ng/dl
Progesterone	2.2 ng/ml,	6.9 ng/ml,	14.2 ng/ml
LH mIU/ml	1.8,	6.4	2.7
FSH mIU/m	1.3,	7.9	3.6

47 yo woman – night sweats, hot flashes, poor sleep, sad, low sexual interest, poor lubrication, muted orgasm, discomfort during penetration

Estradiol synthesis is very minimal, ovulation still occurs

Consider estradiol treatment

Goldstein I, Alexander JL. Practical aspects in the management of vaginal atrophy and sexual dysfunction in perimenopausal and postmenopausal women. J Sex Med. 2005 Sep;2 Suppl 3:154-65.

Courtesy Dr. I. Goldstein

9 Blood Tests: Testosterone, SHBG, Dihydrotestosterone, Estradiol, Progesterone, LH, FSH, TSH, prolactin

Total testosterone, SHBG, *calculated free testosterone (ng/dl)*	→	Use free testosterone calculator (0.6 - 0.8)
DHT (ng/dl)	→	Suspicious in lower tertile
Peri/post-menopausal Estradiol (pg/ml)	→	Aim for 35 - 50 pg/ml
Peri/post-menopausal Progesterone (ng/ml)	→	Aim for 1 ng/ml
LH/FSH (mIU/ml)	→	Range established
TSH (mIU/L)	→	Suspicious > 3.0
Prolactin (ng/ml)	→	Range established

Thyroid disease associated with FSD

HYPOTHYROIDISM

TSH 9.34

36 yo with delayed and orgasm, cold intolerance, irritability, low sexual interest, fatigue

Consider thyroid replacement

HYPERTHYROIDISM

TSH 0.046

36 yo with early orgasm and does not want to be touched because she is too sensitive

Difficulty focusing

Consider methimazole replacement

Sexual Dysfunction in Women with Clinical Hypothyroidism and Subclinical Hypothyroidism

J Sex Med 2010;7:2583–2590

Gokhan Atis, MD,* Ayhan Dalkilinc, MD,† Yuksel Altuntas, MD,‡ Alev Atis, MD,§ Turhan Caskurlu, MD,† and Erbil Ergenekon, MD*

*Sisli Etfal Training and Research Hospital, Urology, Istanbul, Turkey; †Urology Department, Göztepe Training and Research Hospital, Urology, Istanbul, Turkey; ‡Internal Medicine, Sisli Etfal Training and Research Hospital, Istanbul, Turkey; §Obstetric and Gynecology, Sisli Etfal Training and Research Hospital, Istanbul, Turkey

Table 2 FSFI and BDI questionnaire score

Variables	Control group Group 1	Subclinic hypothyroid with TSH ≤ 10 mU/L Group 2	Subclinic hypothyroid with TSH > 10 mU/L Group 3	Clinic hypothyroid Group 4	*P* value*
Total FSFI	32.31 ± 3.50 Tsh < 1	29.20 ± 3.65	26.03 ± 6.50[b]	23.92 ± 5.81[x]	0.000
Desire	5.16 ± 0.74	4.14 ± 0.80	4.24 ± 0.92[c]	4.01 ± 0.93[y]	0.000
Arousal	5.37 ± 0.80	4.73 ± 0.99	4.06 ± 1.58	3.28 ± 1.30[z,f]	0.000
Lubrication	5.40 ± 0.52	5.25 ± 0.58	4.74 ± 1.14	4.24 ± 0.82[f,g]	0.000
Orgasm	5.46 ± 0.51	4.91 ± 0.95	4.10 ± 1.44[d]	3.95 ± 1.23[w]	0.000
Satisfaction	5.40 ± 0.54	4.51 ± 0.73[a]	4.25 ± 1.09	4.06 ± 0.96[q]	0.000
Pain	5.50 ± 0.56	5.37 ± 1.17	4.62 ± 1.69	4.37 ± 1.14[u,h]	0.000
Beck Depression Inventory	7.82 ± 5.2	6.86 ± 7.04	10.54 ± 6.02	12.8 ± 7.4[v,i]	0.014

Data are presented as mean ± SD, *KRUSKAL WALLIS.
Dunn posthoc test.
[a]$P = 0.006$, when the subclinic hypothyroid with TSH level ≤10 mU/L group compared with the control group.
[b]$P = 0.005$, [c]$P = 0.029$, [d]$P = 0.004$ when the subclinic hypothyroid with TSH level >10 mU/L group compared with the control group.
[x]$P = 0.000$, [y]$P = 0.000$, [z]$P = 0.000$, [f]$P = 0.000$, [w]$P = 0.000$, [q]$P = 0.000$, [u]$P = 0.002$, [v]$P = 0.043$ when the clinic hypothyroid group compared with the control group.
[f]$P = 0.041$, [g]$P = 0.008$, [h]$P = 0.002$, [i]$P = 0.017$ when the clinic hypothyroid group compared with the subclinic hypothyroid with TSH level ≤10 mU/L group.
TSH = thyroid stimulating hormone.

Hyperthyroidism: A Risk Factor for Female Sexual Dysfunction

J Sex Med 2011;8:2327–2333

Gokhan Atis, MD,* Ayhan Dalkilinc, MD,† Yuksel Altuntas, MD,‡ Alev Atis, MD,§ Cenk Gurbuz, MD,* Yilmaz Ofluoglu, MD,† Esra Cil, MD,‡ and Turhan Caskurlu, MD*

*Department of Urology, Goztepe Training and Research Hospital, Istanbul, Turkey; †Department of Urology, Sisli Etfal Training and Research Hospital, Istanbul, Turkey; ‡Department of Endocrinology, Sisli Etfal Training and Research Hospital, Istanbul, Turkey; §Department of Obstetric and Gynecology, Sisli Etfal Training and Research Hospital, Istanbul, Turkey

Table 2 FSFI and BDI questionnaire scores

	Control group	Hyperthyroidic group	*P**
Total FSFI	29 ± 10.4	24.2 ± 9.9	0.0001*
Desire	4.3 ± 2.3	3.8 ± 2.1	0.040*
Arousal	4.7 ± 2.2	3.4 ± 2.3	0.0001*
Lubrication	5.1 ± 1.6	4.3 ± 1.9	0.0001*
Orgasm	5.1 ± 1.5	4 ± 2.2	0.0001*
Satisfaction	4.9 ± 2	4.2 ± 1.9	0.0001*
Pain	5.0 ± 2.6	4.4 ± 2.3	0.007*
BDI	11.9 ± 13.2	18.9 ± 15.4	0.0001*

*Independent samples *t*-test/Mann–Whitney *U*-test *$P \leq 0.05$ level.
BDI = Beck Depression Inventory; FSFI = Female Sexual Function Index.

Prolactin and FSD

Endocrine Aspects of Female Sexual Dysfunction

Journal of Sexual Medicine Vol. 1, No. 1, 2004

Susan R. Davis, MD, PhD,* André T. Guay, MD, FACE,† Jan L. Shifren, MD,‡ and Norman A. Mazer, MD, PhD§

Various endogenous hormones, including estrogen, testosterone, progesterone and prolactin, may influence female sexual function

Hormonal therapy should be individualized and risks/benefits fully discussed, and all treated women should be carefully followed up and monitored for therapeutic side effects

Prolactin 36.3

29 yo with bipolar disorder – on Risperidone atypical neuroleptic – very low sexual interest

Consider psychiatric consultation to change medication

Prolactin 125.4

36 yo with low sexual interest non-responsive to testosterone treatment – topical, IM injections and pellets

Consider MRI with gadolinium and cabergoline

MENOPAUSE MANAGEMENT – FIVE TREATMENTS

Testosterone Therapy

Use FDA-approved testosterone at 10% of male dose

1. Daily transdermal gel - 1/10th tube daily to calf/thigh
   Daily transdermal solution (0.3 ml daily underarm
2. Weekly IM injections - 0.1 ml - 50 mg/ml testosterone enanthate/cypionate - into vastus lateralis muscle – anterolateral mid-thigh; 27 gauge needle; 1 ml syringe
3. 4-6 month subcutaneous testosterone pellet

Estradiol Therapy

Consider FDA-approved biologically identical estradiol

1. Daily oral (↑ SHBG, ↑ VTE, ↑ lipids)
2. Daily transdermal gel, emulsion, spray
3. Twice weekly, weekly transdermal patch
4. Three month vaginal ring
5. Weekly IM injections - 0.1 ml – estradiol valerate 10 mg/ml; 5 ml bottle; vastus lateralis muscle – anterolateral mid-thigh - 27 gauge needle; 1 ml syringe

Progesterone Therapy

Consider FDA-approved biologically identical progesterone

1. Oral micronized progesterone 100 mg q MWF (intact uterus, q MTh hysterectomy)
2. Vaginal progesterone suppository – 6 per month
3. Compound progesterone cream

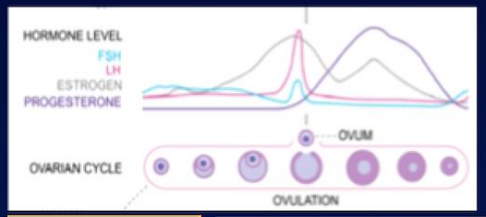

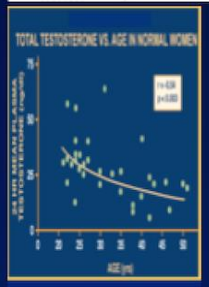



Zumoff et al JCEM 1995

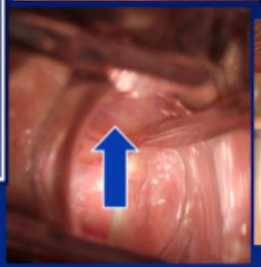

Vestibular Hormonal Therapy

Compound estradiol 0.02%/testosterone 0.1% in hypoallergenic base (methylcellulose); apply pea-sized volume x 2 (right and lft sides; directly onto entire vestibule; QD – BID

Intravaginal Hormonal Therapy

1. Daily compound estradiol 0.02%/testosterone 0.1% in hypoallergenic base (methylcellulose); apply pea-sized volume directly into vagina
2. Daily vaginal estradiol cream – pea-sized amount
3. Daily 10 mg DHEA tablet/1% DHEA suppository
4. Three month vaginal ring

KN - 10-30-14

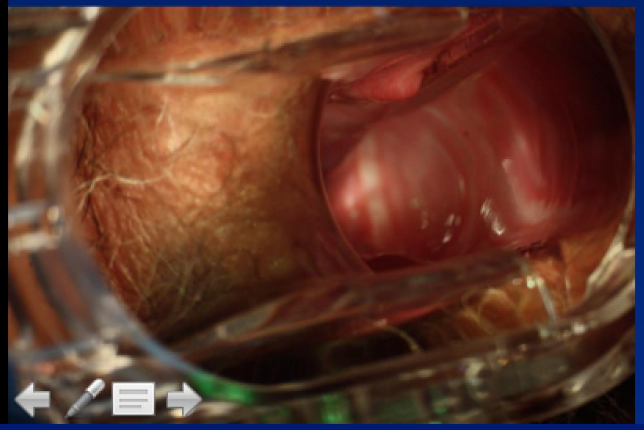

KN – 12-29-14

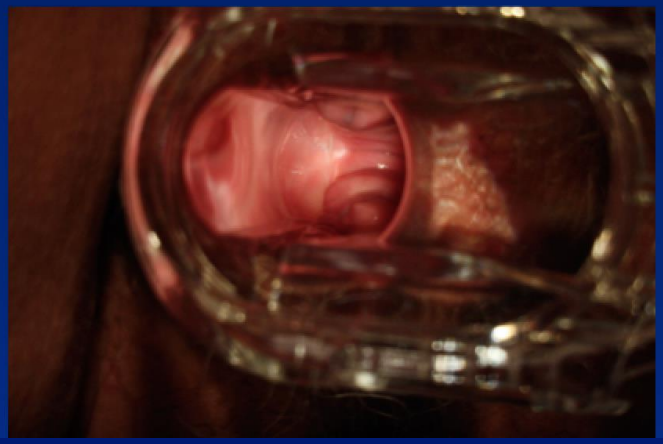

KN – 8-11-15

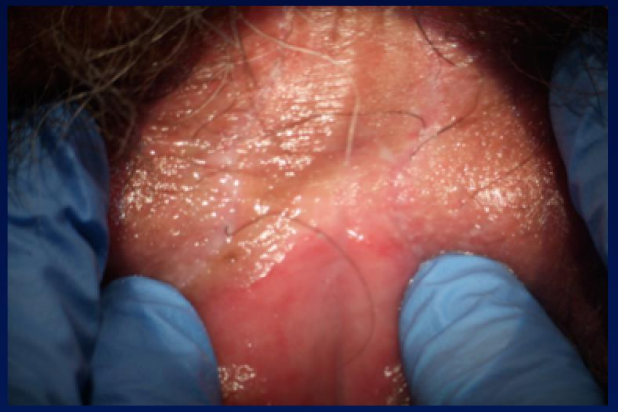

KS – Age 53: 7 - 24 - 13

KS – Age 54: 7 - 23 - 14

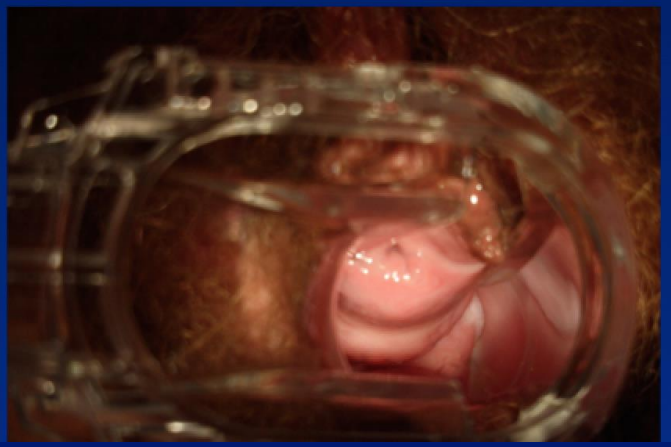

KS – Age 55: 7 - 28 - 15

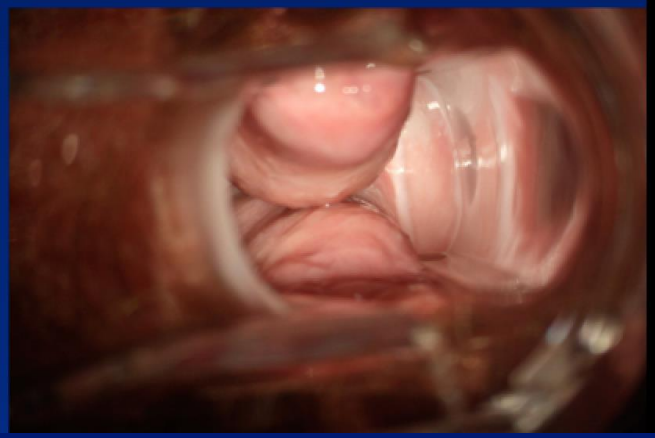

Diagnostic Testing

Endocrine

Neurologic

Vascular

Diagnosis and Treatment Algorithm for Female Sexual Dysfunction

Identification of the sexual health problems

Neurourologic Examination of the Female Patient

Sensory Exam
- pinprick , light touch

Motor Exam
- muscle tone
- muscle strength

Reflexes
- bulbocavernosus
- anal wink

The Neurourological Examination in Women

Claire C. Yang, MD

Department of Urology, University of Washington, and VA Puget Sound Health Care System, Seattle, WA, USA

DOI: 10.1111/j.1743-6109.2008.01022.x

ABSTRACT

The review provides a description of a physical examination protocol to rule out significant neurologic disease as a cause for a woman's sexual complaints, or to confirm a neurologic cause for the sexual dysfunction, particularly in women with known neurologic disease. **Yang CC. The neurourological examination in women. J Sex Med 2008;5:2498–2501.**

Key Words. Physical Examination; Female; Neurourology

The Neurourological Examination in Women

J Sex Med 2008;5:2498–2501

Claire C. Yang, MD

Neurologic genital examination can be performed along with usual vulvoscopic examination

Sensory exam - three branches of pudendal nerve: 1) light touch – cottonball - and 2) pinprick - 22 gauge 1 ½ inch needle - no bony joint on which to test proprioception

Cottonball/pinprick testing: right and left mons, periclitoral area (dorsal nerve of clitoris), labia majora, labia minora (perineal nerve) and perianal areas (inferior rectal nerve)

The Neurourological Examination in Women

J Sex Med 2008;5:2498–2501

Claire C. Yang, MD

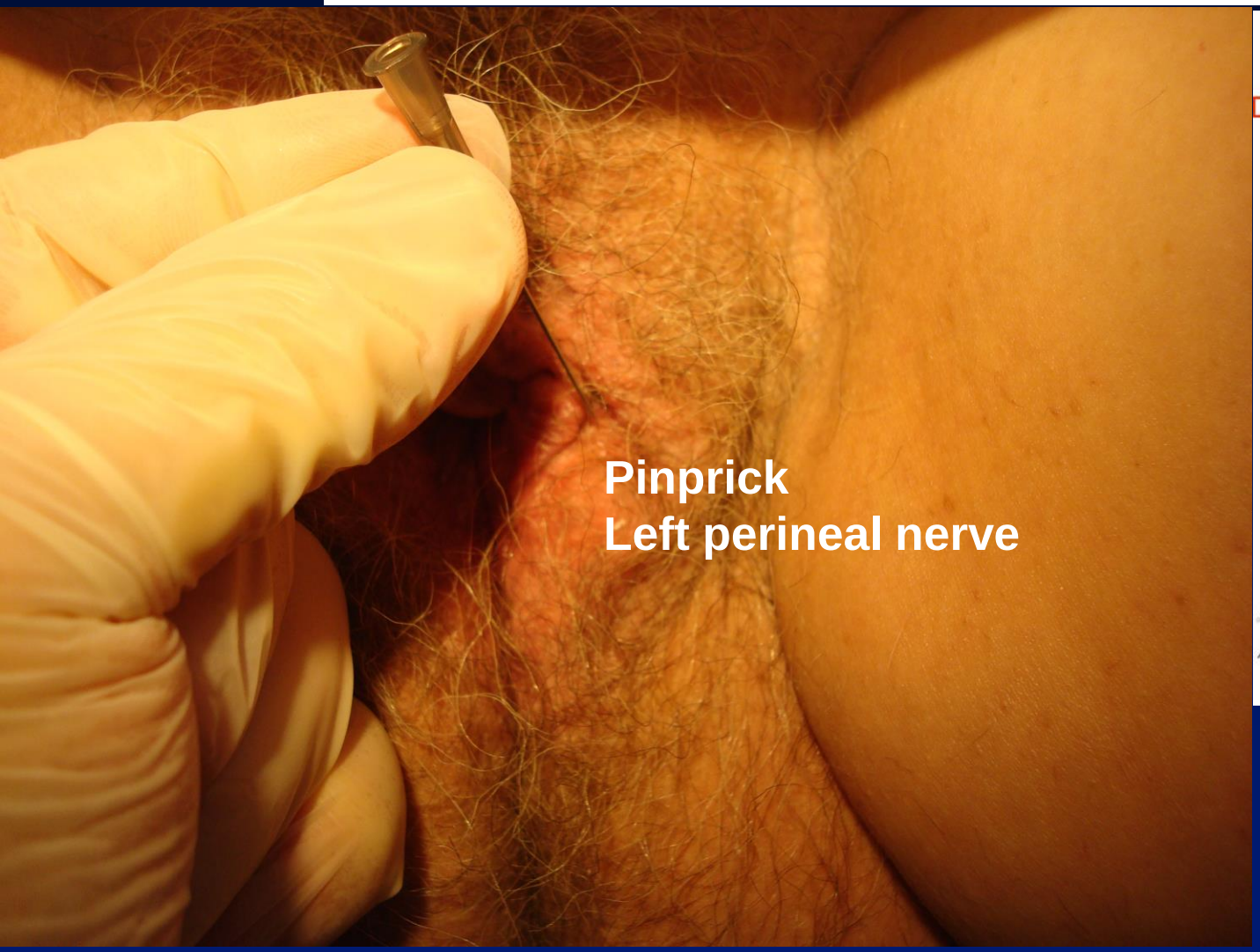

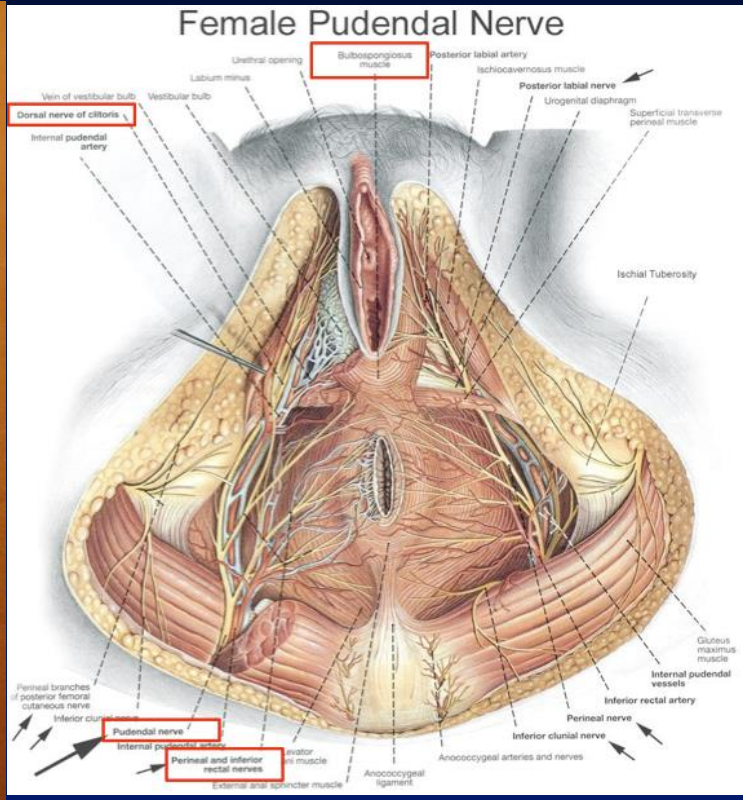

Courtesy Dr. I. Goldstein

The Neurourological Examination in Women

J Sex Med 2008;5:2498–2501

Claire C. Yang, MD

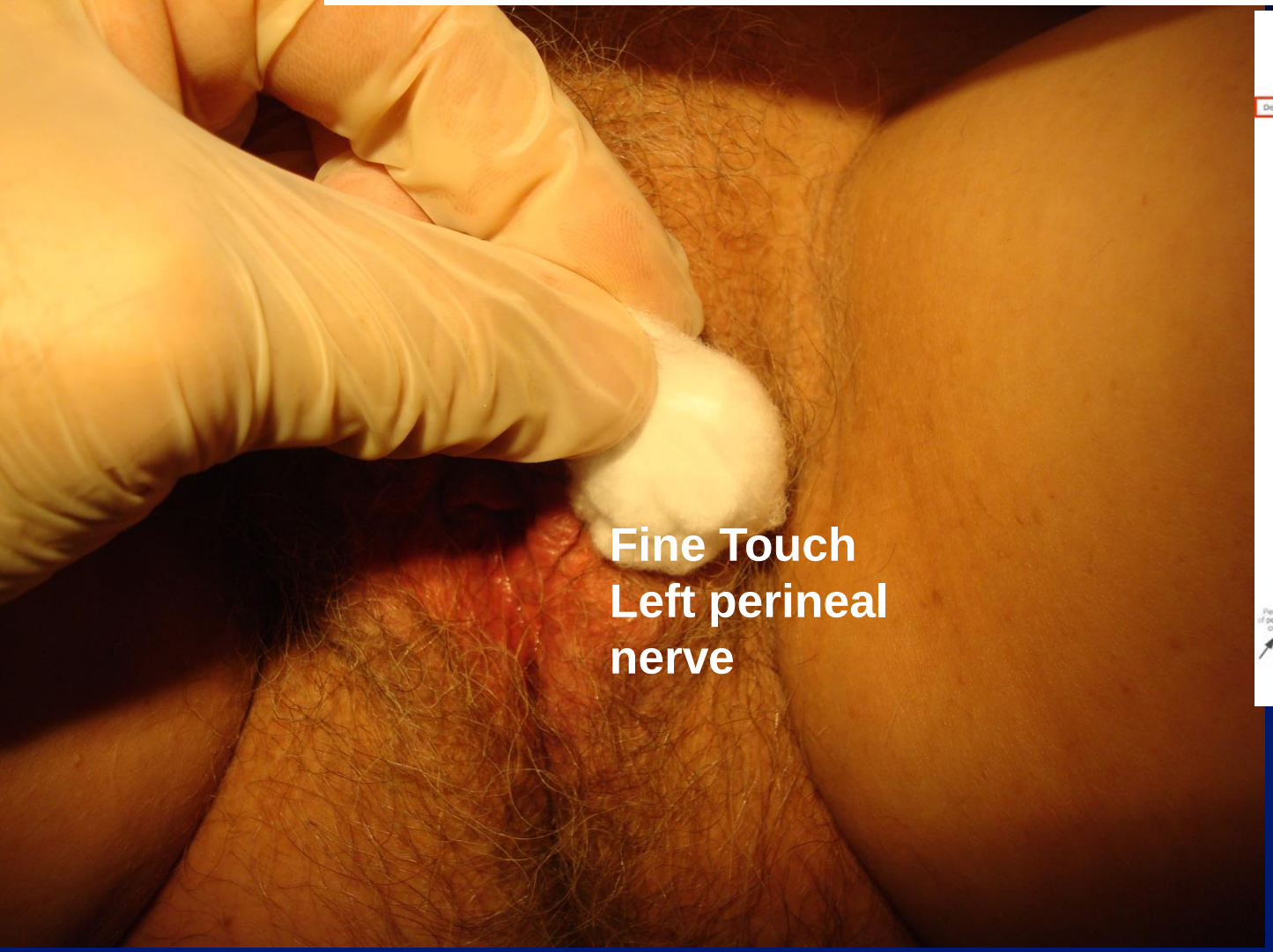

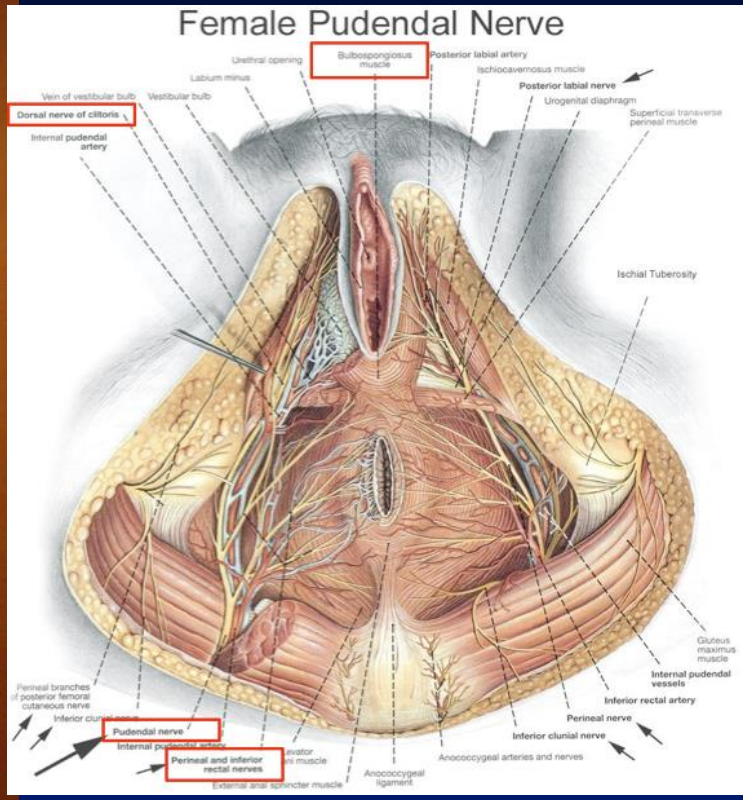

Courtesy Dr. I. Goldstein

The Neurourological Examination in Women

J Sex Med 2008;5:2498–2501

Claire C. Yang, MD

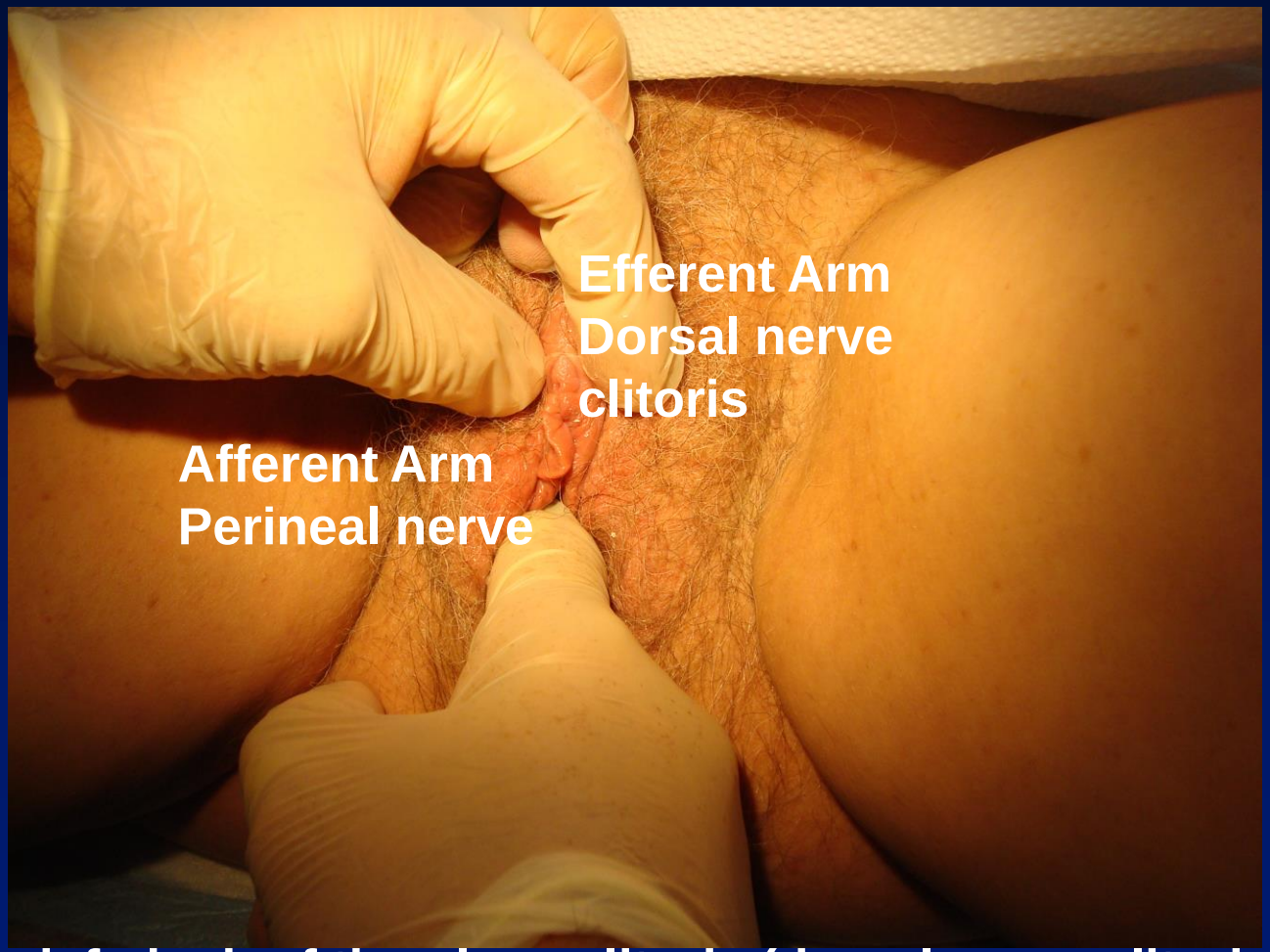

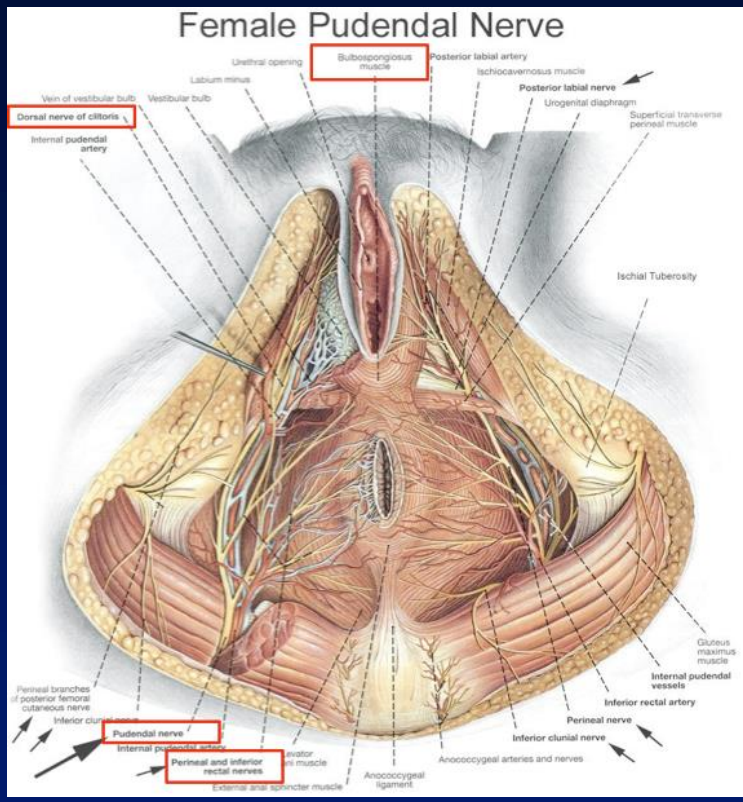

A brief pinch of the glans clitoris (dorsal nerve clitoris) will elicit contraction of the bulbocavernosus muscle (perineal nerve) as well as other pelvic floor muscles.

Courtesy Dr. I. Goldstein

The Neurourological Examination in Women

J Sex Med 2008;5:2498–2501

Claire C. Yang, MD

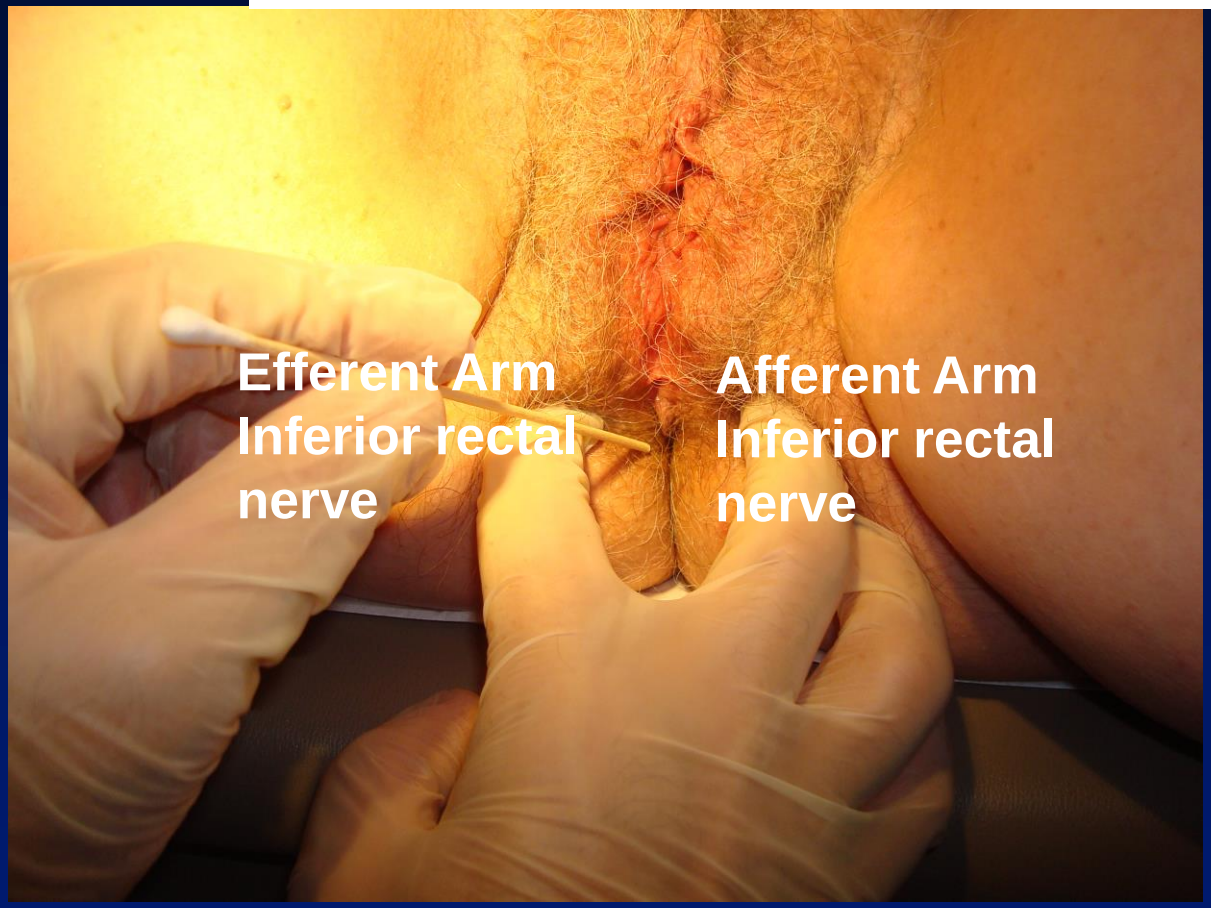

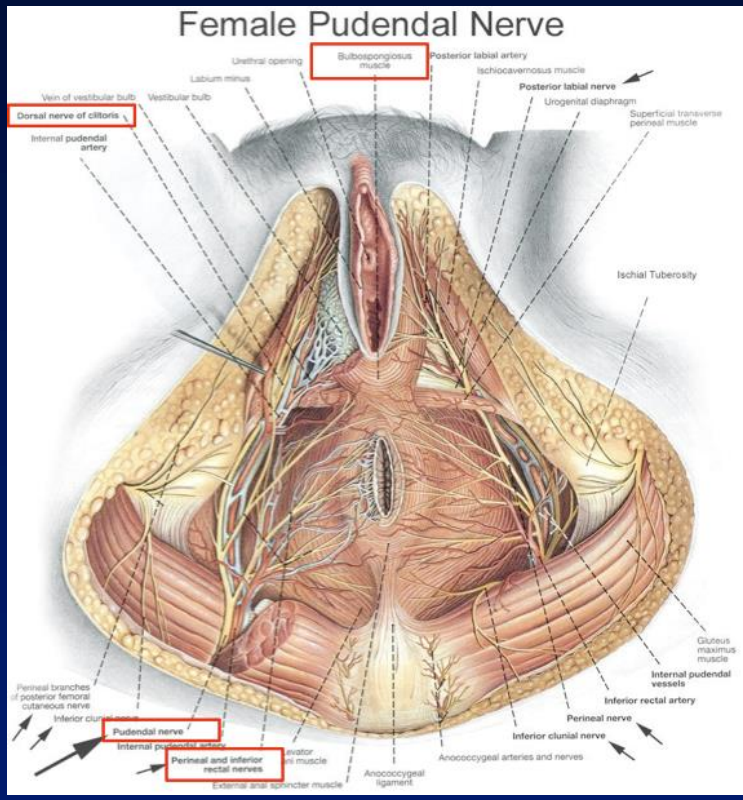

A brief contraction of the anal sphincter (inferior rexctal nerve) will be visible after touching the skin (inferior rectal nerve)

Courtesy Dr. I. Goldstein

Update on Physical Exam Testing Procedures

Quantitative Sensory Testing

Administration of quantified stimuli, vibration or temperature, in controlled way, subject defines sensory threshold by indicating onset of perceived sensation

Genital Biothesiometry

Update on Physical Exam Testing Procedures

A-beta fibers - largest fibers, mediate touch, mild pressure, sensation of joint position and **vibration**

A-delta fibers - smaller fibers, mediate sensation of **cold** and first components of pain sensation

C fibers - smallest slowest fibers, mediate **warm** sensation, main component of pain sensation and subserve most of autonomic peripheral functions

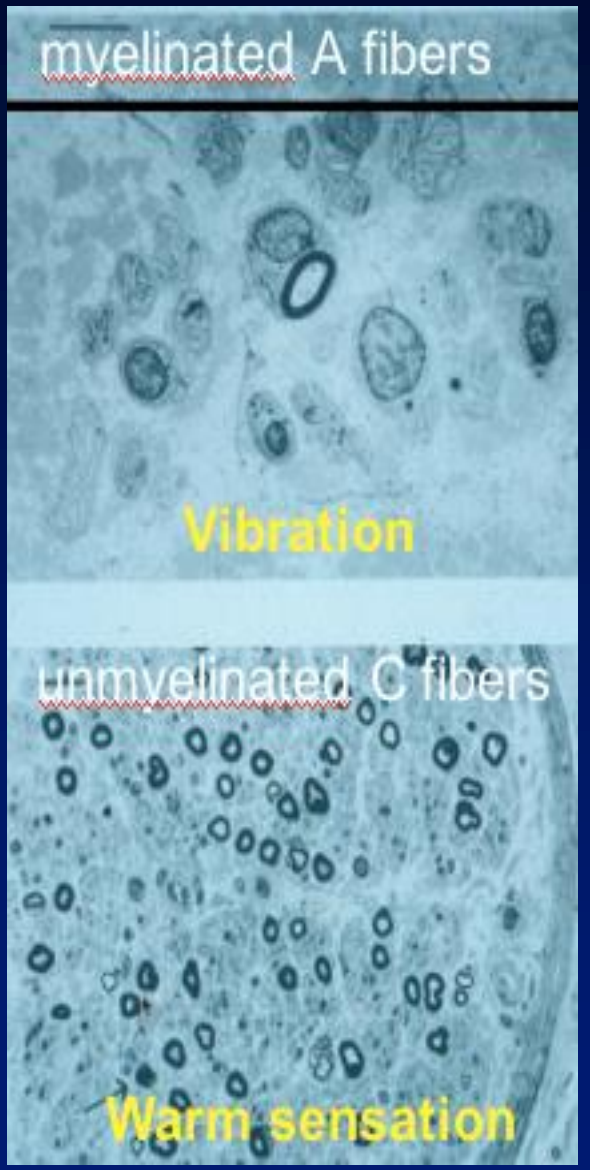

The Neurourological Examination in Women

Claire C. Yang, MD

J Sex Med 2008;5:2498–2501

Quantitative Testing of the Dorsal Nerve Branch of the Pudendal Nerve



Biothesiometry Testing - Dorsal nerve clitoris

Temperature Testing - Dorsal nerve clitoris

Neurologic Tests

Vestibular Biothesiometry (mean of 3 values per site)

R pulp index finger	4 V
glans clitoris	4 V
R Labia minora	4 V
L Labia minora	4 V

R pulp index finger	4 V
glans clitoris	12 V
R Labia minora	14 V
L Labia minora	13 V

The Neurourological Examination in Women

Claire C. Yang, MD

J Sex Med 2008;5:2498–2501

Neurologic Tests

Hot/Cold Perception Threshold (mean of 3 values per site)

R pulp index finger	20°	30°
glans clitoris	20°	30°
R Labia minora	20°	30°
L Labia minora	20°	30°

R pulp index finger	20°	30°
glans clitoris	12°	37°
R Labia minora	13°	40°
L Labia minora	12°	39°

Somatosensory Evoked Potential (SEP) of dorsal nerve of clitoris

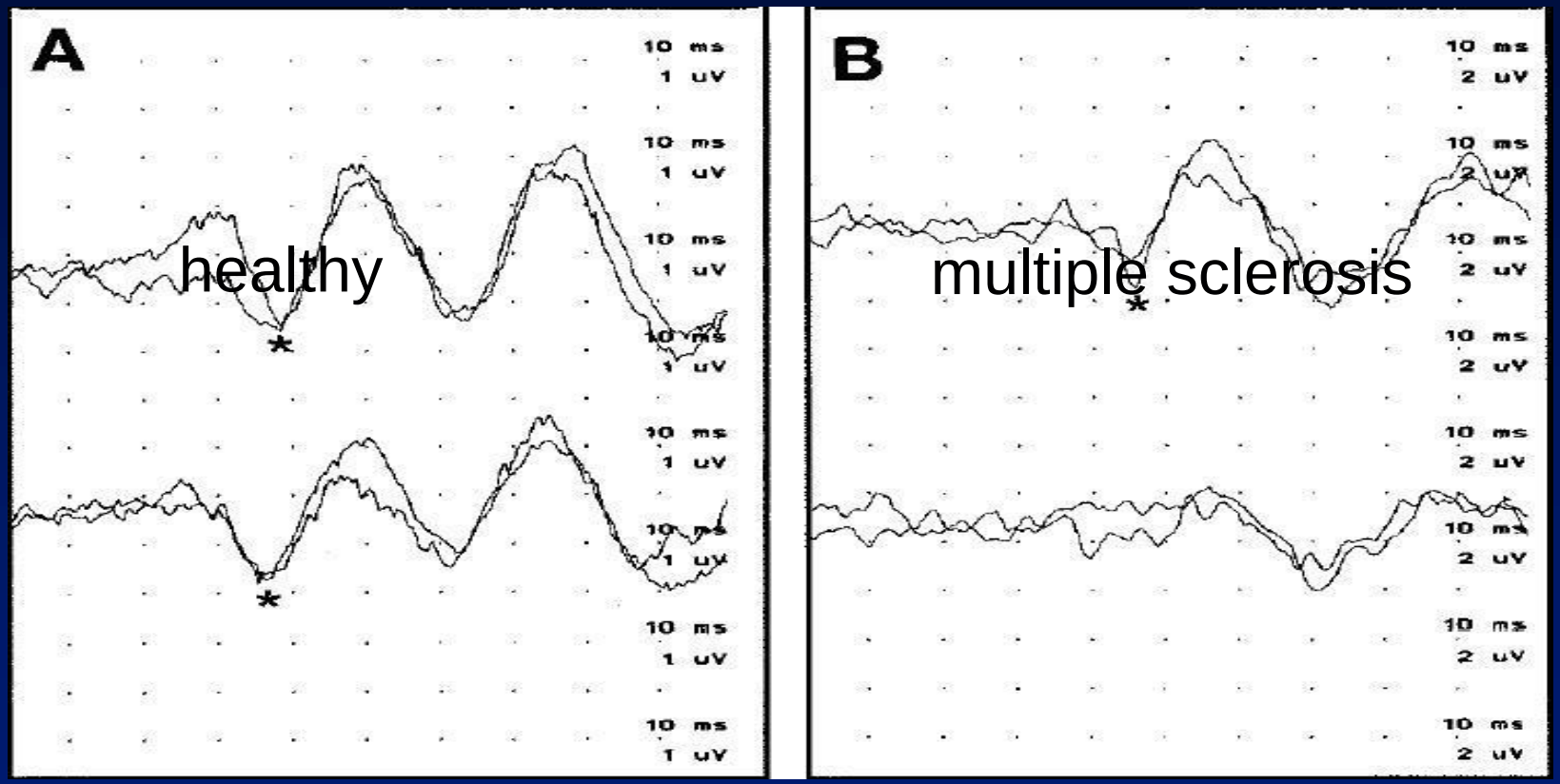

Nappi R, Salonia A, Traish AM, van Lunsen RHW, Vardi Y, Kodiglu K, and Goldstein I. Clinical Biologic Pathophysiologies of Women's Sexual Dysfunction. J Sex Med 2005 Jan 2(1): 4-25.

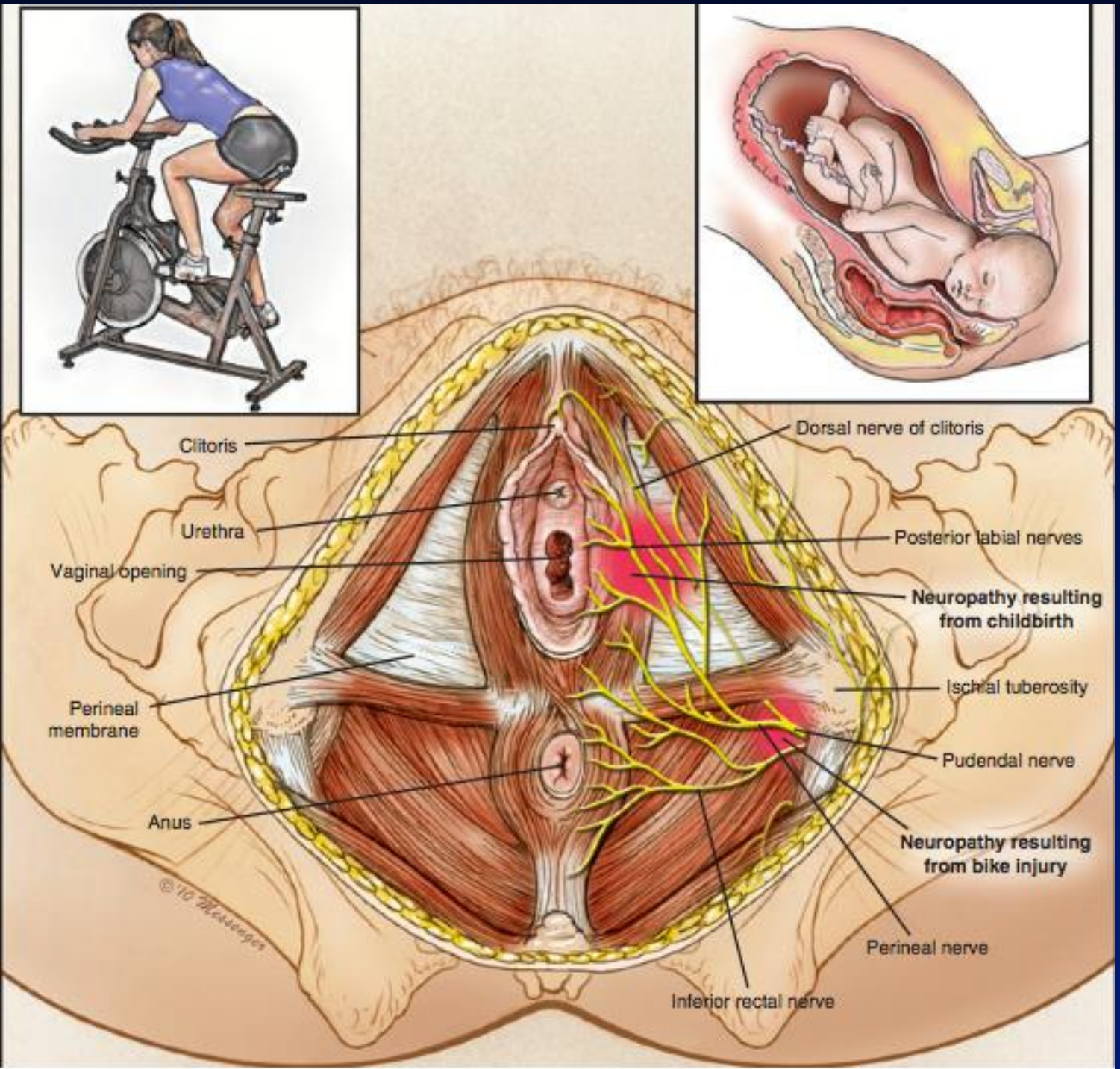

J Sex Med 2010;7:1716–1719

Techniques of Pudendal Nerve Block

Lauri Romanzi, MD

Weill Cornell Medical Center, New York Presbyterian Hospital, New York, NY, USA

ORIGINAL RESEARCH—WOMEN'S SEXUAL HEALTH

Genital Sensation and Sexual Function in Women Bicyclists and Runners: Are Your Feet Safer than Your Seat?

J Sex Med 2006;3:1018–1027

Marsha K. Guess, MD,* Kathleen Connell, MD,† Steven Schrader, PhD,‡ Susan Reutman, PhD,‡ Andrea Wang, MD,† Julie LaCombe, MD,† Christine Toennis, PhD,‡ Brian Lowe, PhD,‡ Arnold Melman, MD,† and Magdy Mikhail, MD†

Table 5 Regression models of vibratory thresholds and group (bicyclists vs. runners) by genital site*

Genital site	Final model†	N	Adjusted R^2	Beta‡	*P* value
Clitoris	Age	69	0.099	0.026	0.005
Left perineum	Group	67	0.126	1.738	0.002
Right perineum	Group	67	0.085	1.620	0.010
Anterior vagina	Age	70	0.132	0.122	0.001
Posterior vagina	Group	70	0.194	1.653	<0.001
Left labia	Group	68	0.060	0.902	0.025
Right labia	Group	68	0.113	2.010	0.003
Urethra	Age	70	0.212	0.145	<0.001

Diagnostic Testing

Endocrine

Neurologic

Vascular

Thermography as a Physiological Measure of Sexual Arousal in Both Men and Women

J Sex Med 2007;4:93–105

Tuuli M. Kukkonen, BA,* Yitzchak M. Binik, PhD,*† Rhonda Amsel, MSc,* and Serge Carrier, MD††

*Department of Psychology, McGill University, Montreal, Canada; †Sex and Couple Therapy Service, Department of Psychology, McGill University Health Center, Montreal, Quebec, Canada; ††Department of Urology, McGill University, Montreal, Canada

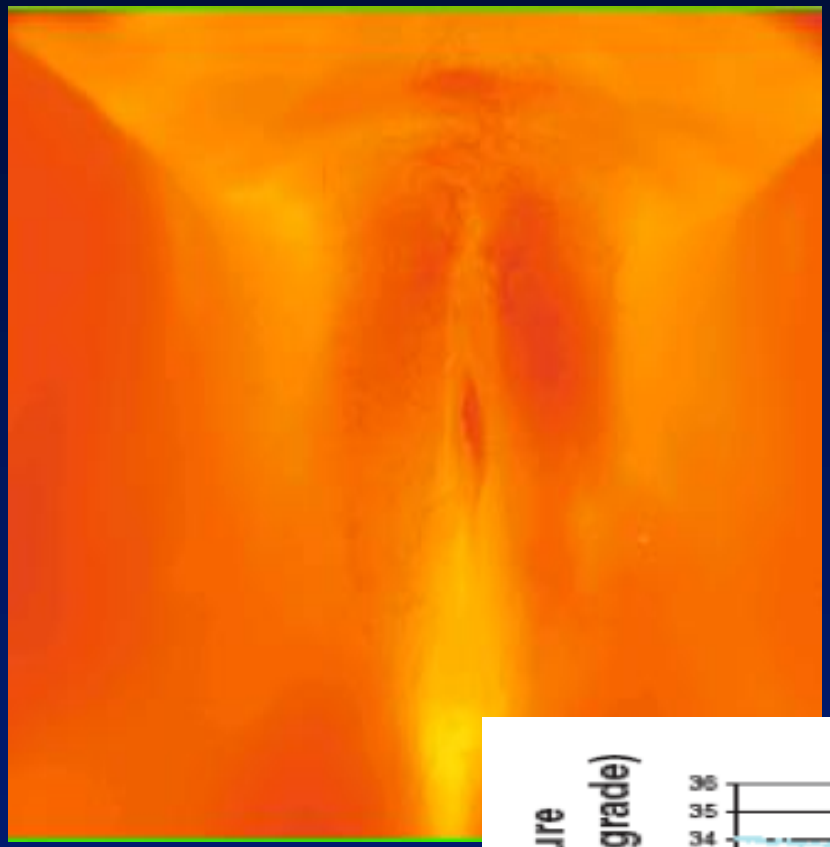

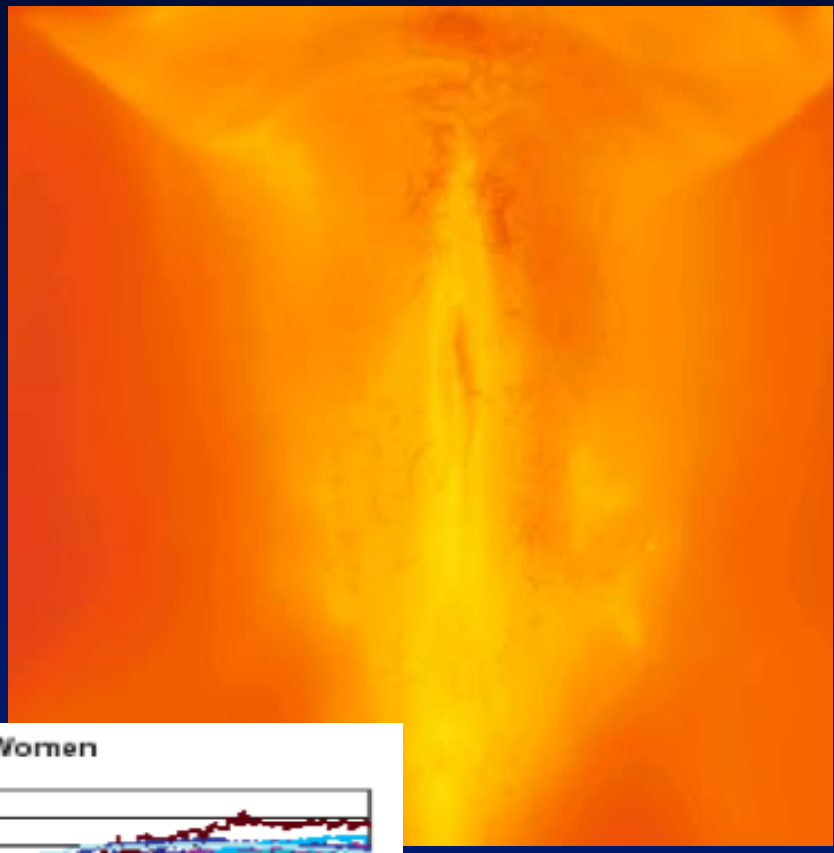

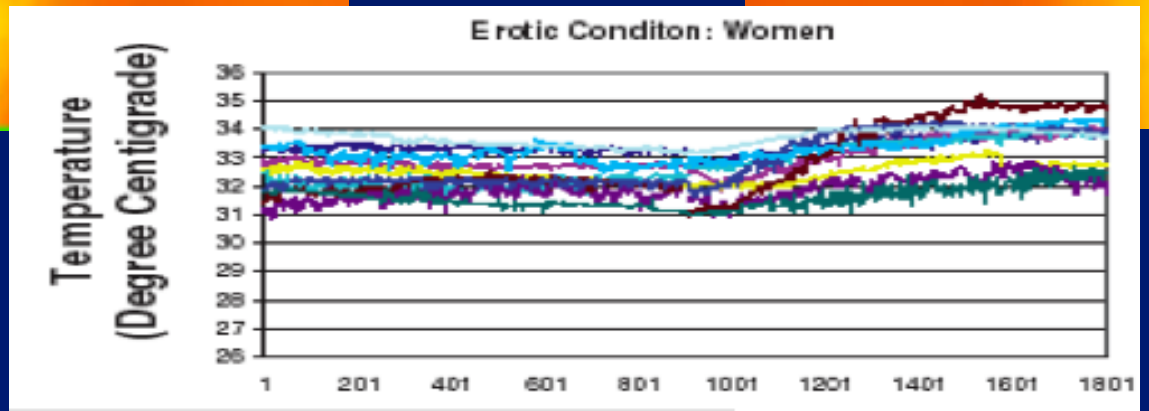

Forward Looking Infrared (FLIR) To Assess Sexual Arousal

Forward Looking Infrared (FLIR) is an imaging technology that senses infrared radiation and thermal energy

Forward Looking Infrared – (FLIR) can be used to help pilots and drivers steer their vehicles at night, and in fog, or detect warm objects against a cold background when it is completely dark - such as a cloudy, moonless night)

Forward Looking Infrared (FLIR) can be used to assess blood flow in tissues

Thermography as a Physiological Measure of Sexual Arousal in Both Men and Women

J Sex Med 2007;4:93–105

Tuuli M. Kukkonen, BA,* Yitzchak M. Binik, PhD,*† Rhonda Amsel, MSc,* and Serge Carrier, MD††

Courtesy Dr. I. Goldstein

Forward Looking Infrared (FLIR) To Assess Sexual Arousal

Forward Looking Infrared (FLIR) Termography is an imaging technology that **senses infrared radiation and thermal energy**

The vulva, vestibule, and glans clitoris emit thermal energy

It is possible to **detect increases in infrared radiation emission by remote sensing using a high-resolution, fast-scanning camera that can produce thermal images with a precision of 0.07 degrees C in a very short period of time**

Two women underwent FLIR testing before and after application of a study drug to the clitoris

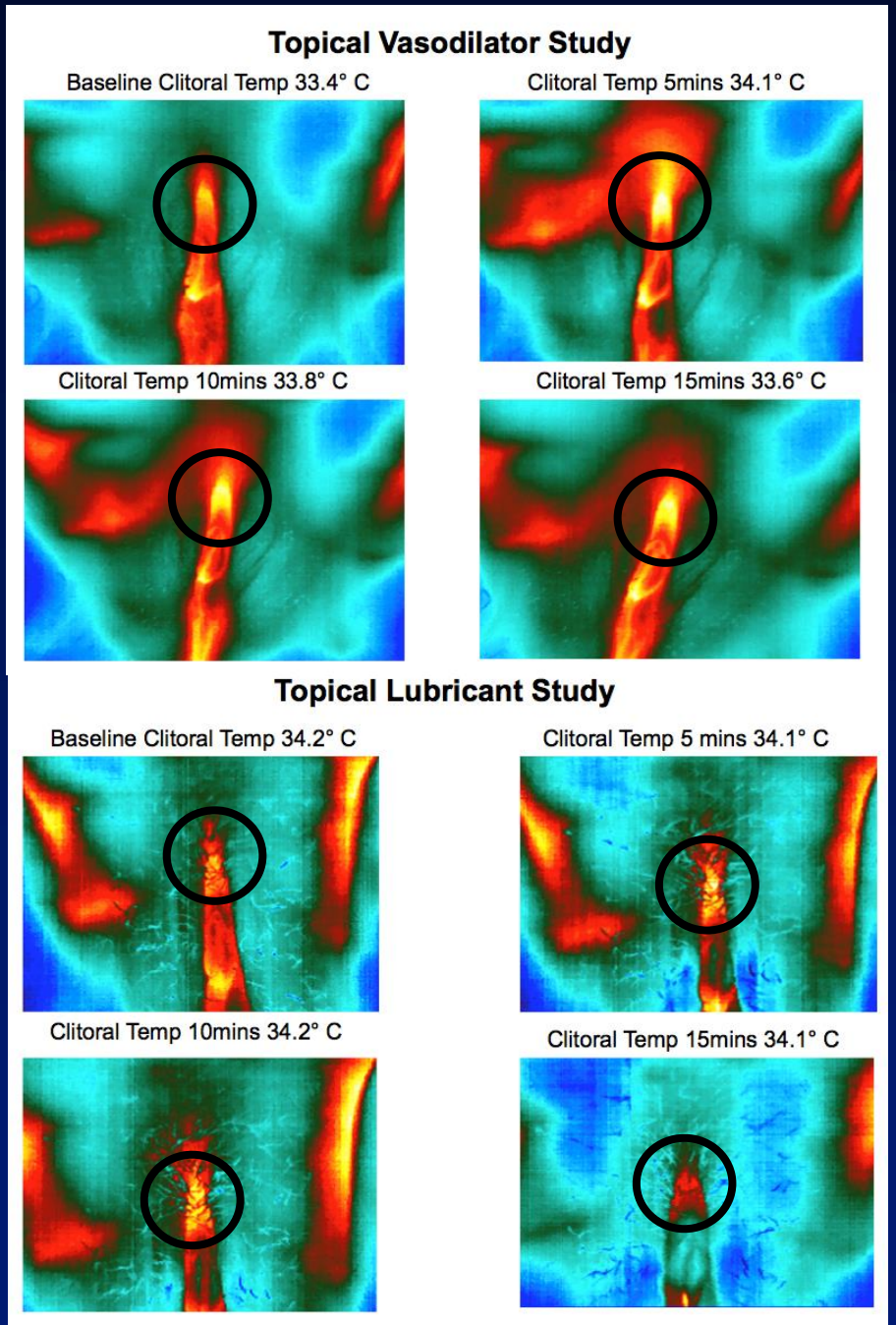

Courtesy Dr. I. Goldstein

Thermography as a Physiological Measure of Sexual Arousal in Both Men and Women

J Sex Med 2007;4:93–105

Tuuli M. Kukkonen, BA,* Yitzchak M. Binik, PhD,*† Rhonda Amsel, MSc,* and Serge Carrier, MD††

A Randomized, Single Center, Single-Blind, Crossover Thermographic Study to Evaluate the Effect of 1000 mcg of Topical Alprostadil Cream Compared to an Over-the-Counter Marketed Lubricant

Mean temperature change from baseline

VESTIBULE
significantly different
at 11 minutes

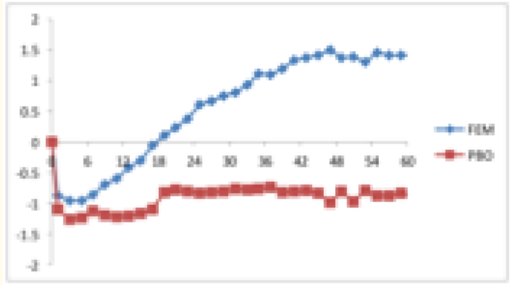

CLITORIS
significantly different
at 19 minutes

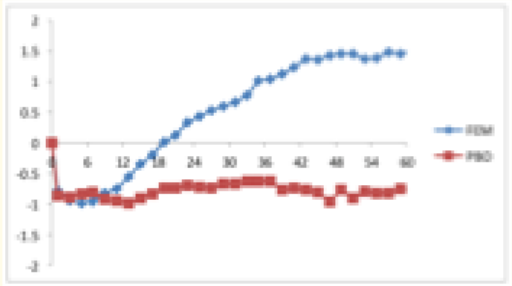

VULVA
significantly different
At 9 minutes

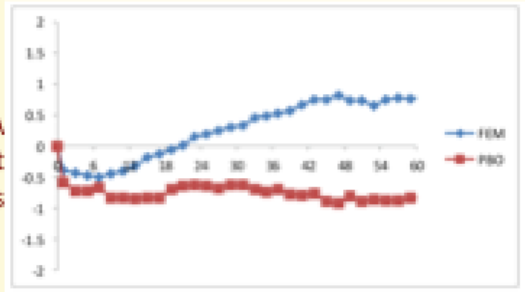

Topical alprostadil cream administered to healthy premenopausal women induced statistically significant sustained increases in genital temperatures of the vestibule, clitoris and vulva within 20 minutes relative to OTC lubricant

Anatomy of Fiera™

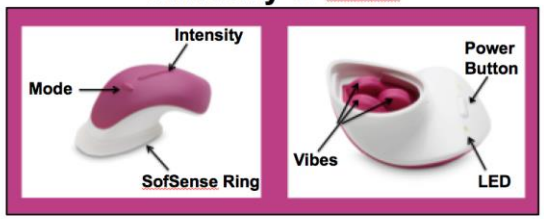

Placement of Fiera™

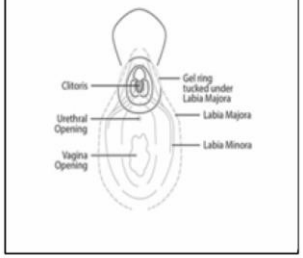

Baseline

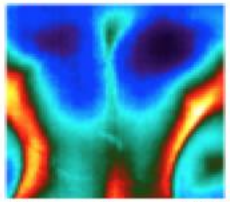

Clitoral Temp – 32.4 C
Vestibule Temp – 32.6 C
Vulva Temp – 32.7 C

Post-*Fiera* Use

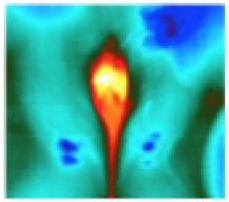

Clitoral Temp – 37.1 C
Vestibule Temp – 35.0 C
Vulva Temp – 345 C

Baseline

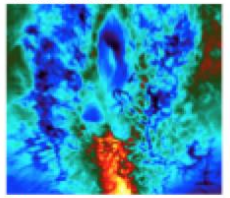

Clitoral Temp – 33.6 C
Vestibule Temp – 34.1 C
Vulva Temp – 33.8 C

Post-*Fiera* Use

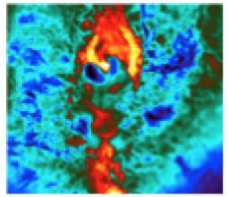

Clitoral Temp – 36.3 C
Vestibule Temp – 35.6 C
Vulva Temp – 34.6 C

Thermography Results

Clitoris:

Change from Baseline	Mean	Std Dev	Min Temp Δ	Max Temp Δ	P-Value
0 mins	2.43	0.96	1.20	4.70	<.0001
2 mins	0.90	0.56	0.10	1.70	0.0002
4 mins	0.62	0.56	-0.20	1.60	0.0028
6 mins	0.60	0.60	-0.50	1.50	0.0052
8 mins	0.58	0.53	-0.20	1.50	0.0030
10 mins	0.54	0.46	-0.10	1.40	0.0017

Vestibule:

Change from Baseline	Mean	Std Dev	Min Temp Δ	Max Temp Δ	P-Value
0 mins	1.63	0.58	0.70	2.40	<.0001
2 mins	0.66	0.48	0.10	1.50	0.0006
4 mins	0.50	0.50	-0.20	1.60	0.0054
6 mins	0.46	0.46	-0.20	1.30	0.0075
8 mins	0.44	0.44	-0.10	1.40	0.0053
10 mins	0.39	0.39	-0.10	1.30	0.0073

Labia:

Change from Baseline	Mean	Std Dev	Min Temp Δ	Max Temp Δ	P-Value
0 mins	0.82	0.48	0.10	1.80	0.0001
2 mins	0.34	0.34	-0.20	0.80	0.0049
4 mins	0.23	0.38	-0.30	0.80	0.0568
6 mins	0.21	0.37	-0.40	0.80	0.0739
8 mins	0.19	0.37	-0.40	0.80	0.1006
10 min	0.14	0.36	-0.60	0.70	0.1947

= statistically significant temperature increases

Conclusions

- Fiera™, which employs both suction and vibration, produced statistically significant increases in vulvar temperatures, which is a marker of genital blood flow and engorgement.
- Use of *Fiera* in this population of postmenopausal women, of whom the majority were not using any type of hormone therapy, produced sexual desire in 100% of the subjects while 83% experienced genital arousal.
- The congruence between genital arousal and development of sexual desire as a result of *Fiera* use is a notable finding that warrants further investigation.
- Limitations: study performed on a sexually healthy population, not "at risk" for FSD based on FSFI scores. Applicability to a sexually dysfunctional postmenopausal population has not yet been evaluated.

Duplex Doppler Ultrasonography

Sonographic landmark:

the angle of the clitoral shaft with the suspensory ligament

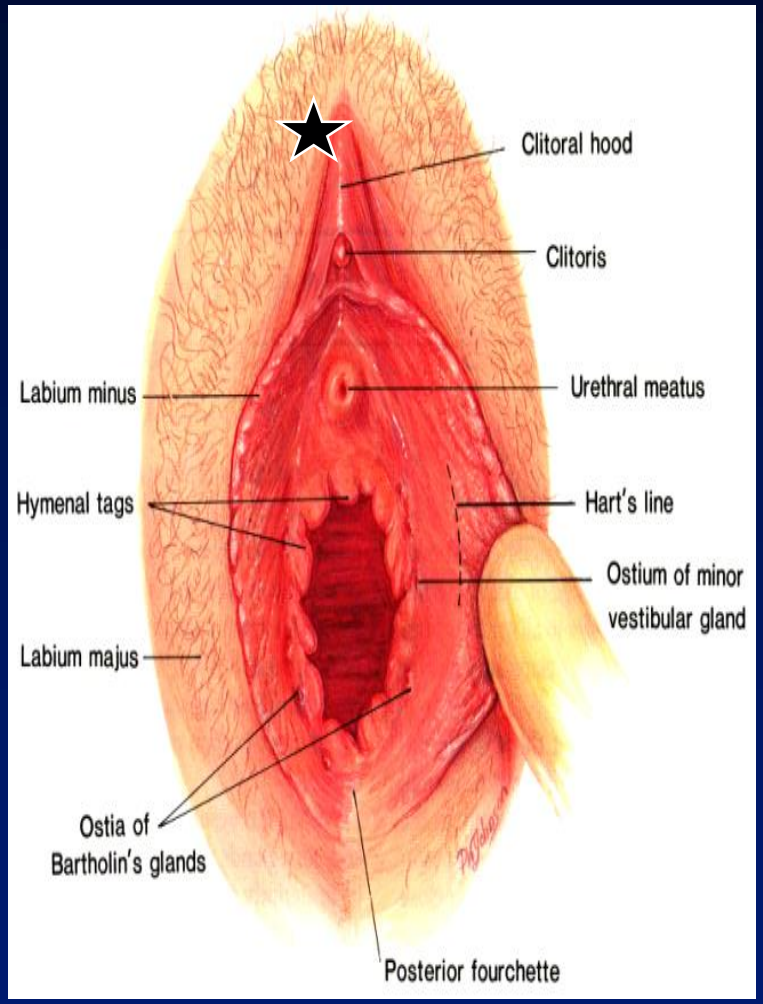

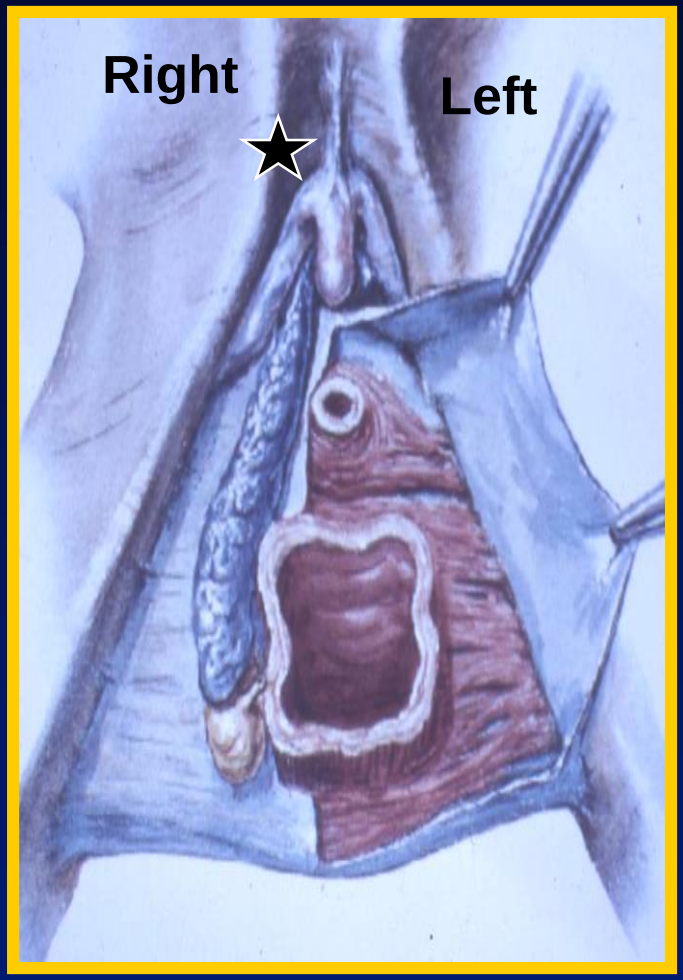

Garcia S, Talakoub L, Maitland S, Dennis A, Goldstein I, Munarriz R. Genital duplex Doppler ultrasonography before and after sexual stimulation in women with sexual dysfunction: gray scale, volumetric, and hemodynamic findings. Fertil Steril. 2005 Apr;83(4):995-9

Duplex Doppler Ultrasonography

Pre-Stimulation

Post-stimulation
PSV 60.9 cm/s
EDV 26.3 cm/s
RI 0.57

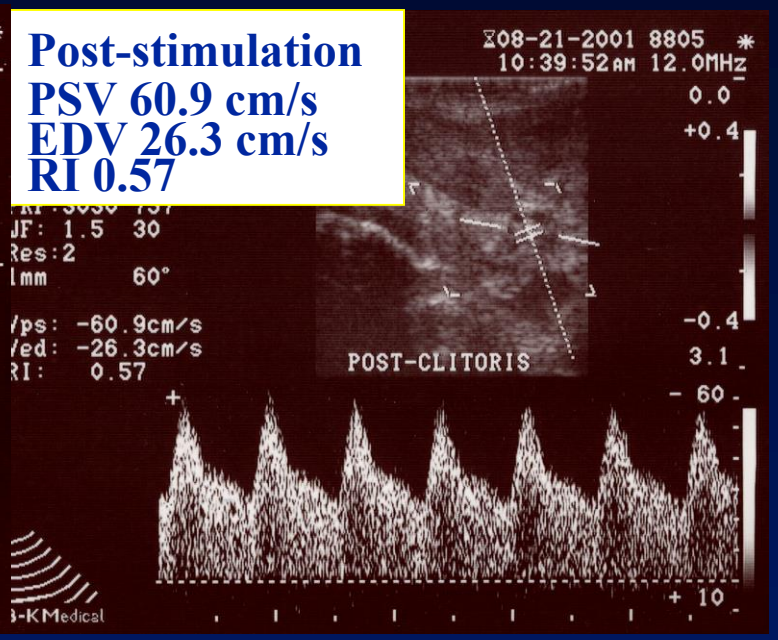

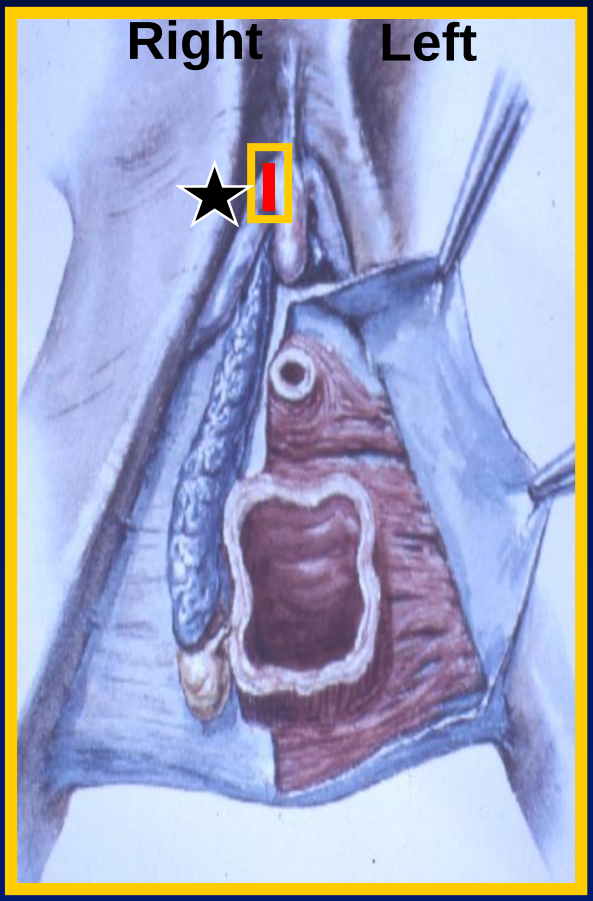

Courtesy Dr. I. Goldstein

Sexual Arousal/Genital Blood Flow in Women with Sexual Dysfunction

Clitoral Changes, Sexuality, and Body Image During the Menstrual Cycle: A Pilot Study

Elena Morotti, MD,* Bruno Battaglia, MS,* Nicola Persico, MD, Paolo Busacchi, MD,* Stefano Venturoli, MD,* and Cesare Bat

J Sex Med 2013;10:1320–1327

Thermography as a Physiological Measure of Sexual Arousal in Both Men and Women

J Sex Med 2007;4:93–105

Tuuli M. Kukkonen, BA,* Yitzchak M. Binik, PhD,*† Rhonda Amsel, MSc,* and Serge Carrier, MD††

Sexual Arousal in Women with Provoked Vestibulodynia: The Application of Laser Doppler Imaging to Sexual Pain

J Sex Med 2013;10:1052–1064

Stéphanie C. Boyer, MSc,* Caroline F. Pukall, PhD,* and Susan M. Chamberlain, MD†

The Labial Photoplethysmograph: A New Instrument for Assessing Genital Hemodynamic Changes in Women

J Sex Med 2005; 2: 58–65

Nicole Prause, BA,*† Jerome Cerny, PhD,† and Erick Janssen, PhD*†

Magnetic Resonance Imaging and the Female Sexual Response: Overview of Techniques, Results, and Future Directions

J Sex Med 2008;5:1559–1571

Kenneth R. Maravilla, MD,* and Claire C. Yang, MD†

Arterial occlusive pathology in the ilio-hypogastric-pudendal arterial bed in women

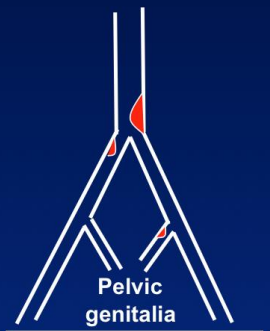

- ↓vaginal lubrication
- ↓vaginal wall pressures
- ↓vaginal length/width
- ↓clitoral blood flow

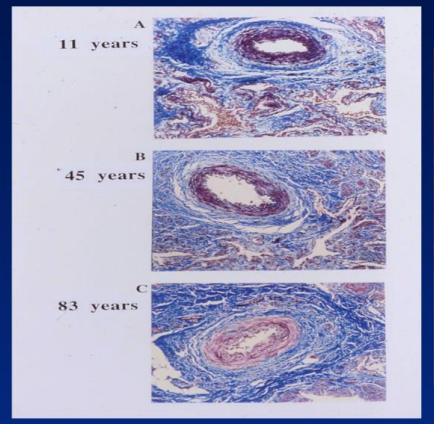

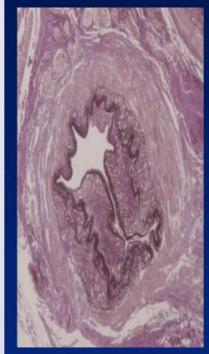

Tarcan T, Park K, Goldstein I, Maio G, Fassina A, Krane RJ, Azadzoi KM. Histomorphometric analysis of age-related structural changes in human clitoral cavernosal tissue. J Urol. 1999 Mar;161(3):940-4.

Park K, Goldstein I, Andry C, Siroky MB, Krane RJ, Azadzoi KM. Vasculogenic female sexual dysfunction: the hemodynamic basis for vaginal engorgement insufficiency and clitoral erectile insufficiency. Int J Impot Res. 1997 Mar;9(1):27-37.

Cardiometabolic Risk and Female Sexual Health: The Princeton III Summary

J Sex Med 2012;9:641–651

Martin Miner, MD,* Katherine Esposito, MD, PhD,† Andre Guay, MD,‡ Piero Montorsi, MD,§ and Irwin Goldstein, MD¶

*Men's Health Center, Department of Family Medicine and Urology, Warren Alpert School of Medicine, Brown University, Providence, RI, USA; †Division of Diabetology and Metabolic Diseases, Department of Geriatrics and Metabolic Diseases, Second University of Naples, Naples, Italy; ‡Center for Sexual Function, Lahey Clinic, Peabody, MA, USA; §Department of Cardiovascular Sciences, University of Milan, Centro Cardiologico Monzino, IRCCS, Milan, Italy; ¶Sexual Medicine, Alvarado Hospital, San Diego, CA, USA

Table 1 Risk factors for FSD

Risk factor	Authors	Study population	Outcome measure	Prevalence of FSD	Predictors of FSD
• Hypertension	Thompson et al. [8]	417 sexually active women in outpatient hypertension clinic	FSFI	42.1% of hypotensive vs. 19.4% of normotensive women	• High systolic BP levels • Increased age • Beta-blocker administration • Poorly controlled hypertension
• Hypertension	Inman et al. [9]	156 women, 71 with hypertension	FSFI	90% of hypertensive vs. 41% of normotensive women	• Increased age • Less education • Lower income • High BMI
• Hypertension	Allahdadi et al. [11]	454 women returning questionnaires, 109 hypertensive, 89 of 109 were being treated	Unvalidated questionnaire	N/A	• Hypertension
• Hypertension • Dyslipidemia/ hyperlipidemia	Nappi et al. [10]	127 women, 91 with diabetes, obesity, or hypothyroidism	FSFI	N/A	• High diastolic BP • Low HDL/cholesterol • High LDL/cholesterol
• Dyslipidemia/ hyperlipidemia	Caruso et al. [12]	556 women, 441 with dyslipidemia	FSFI	51% of women with hyperlipidemia vs. 21% without hyperlipidemia	• Increased age • High BMI • Low HDL/cholesterol • High triglycerides
• Dyslipidemia/ hyperlipidemia • Diabetes	Battaglia et al. [13]	595 with type 2 diabetes	FSFI	53.4% of women	• Increased age • Metabolic syndrome • Dyslipidemia • Depression • Marital status
• Diabetes	Burri et al. [15]	120 diabetic women in outpatient diabetes clinic, 180 women in gynecology clinic	Unvalidated questionnaire	27% of diabetic women vs. 15% of nondiabetic	• Depression
• Diabetes	Tarcan et al. [16]	652 women with type 1 diabetes	N/A	35% of women with type 1 diabetes	• Increased age • Marital status • Menopausal status • Microvasculopathy • Depression
• Diabetes	Doumas et al. [17]	595 with type 2 diabetes	FSFI	N/A	• Poor adherence to Mediterranean diet
• Smoking	Hannan et al. [5]	46,525 women in WHI	Question: How satisfied are you with your sexual activity?	N/A	*Risk of sexual dissatisfaction:* • Increased age • Marital satisfaction • Parity • Smoking history
• Metabolic syndrome/obesity	Veronelli et al. [19]	200 women, 120 with metabolic syndrome	FSFI	N/A	• High C-reactive protein
• Metabolic syndrome/obesity	Okeahialam and Ogbonna [20]	538 women	N/A	N/A	*Risk of impaired sexual desire* • Metabolic syndrome

BMI = body mass index; BP = blood pressure; FSD = female sexual dysfunction; FSFI = Female Sexual Function Index; HDL = high-density lipoprotein; LDL = low-density lipoprotein; N/A = not applicable; WHI = Women's Health Initiative

Based on limited current data, there appears to be an association between female sexual health and vascular risk factors (hypertension, hyperlipidemia, metabolic syndrome/obesity, diabetes, and coronary heart disease). More research is needed

Ergonomics of 2 Bicycle Saddles

Prof. Dr. Ingo Froböse, Prof. Dr. Luc Baeyens, Kim Tofaute et.al.

Pressure at the Pudendal Area in Women of a Normal Saddle with Gel and of a Saddle with a Hole

Fig. 1 – athletic position - 40°

Fig.2 – moderate position – 60°

Women's Bike Seats: A Pressing Matter for Competitive Female Cyclists

J Sex Med 2011;8:3144–3153

Marsha K. Guess, MD,* Sarah N. Partin, BA,† Steven Schrader, PhD,‡ Brian Lowe, PhD,‡ Julie LaCombe, MD,§ Susan Reutman, PhD,‡ Andrea Wang, MD,¶ Christine Toennis, BS,‡ Arnold Melman, MD,** Madgy Mikhail, MD,†† and Kathleen A. Connell, MD*

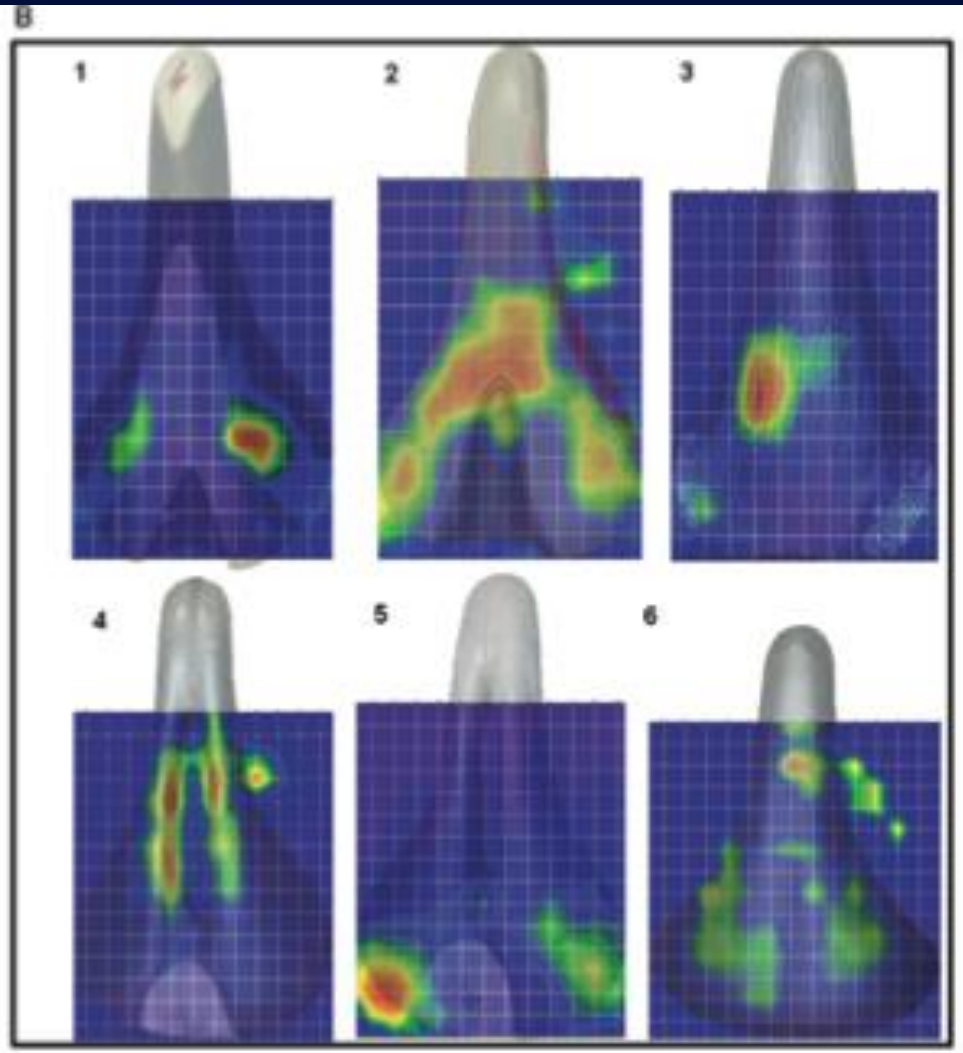

Table 4 Multivariable regression model of mean total saddle pressure

Final model for mean total saddle pressure ($F_{(3,\ 37)} = 24.53$, $R^2 = 0.6654$, N = 41)

Predictor variable	Coefficient (95% CI)	*P* value
BMI	0.56 (0.27, 0.86)	<0.000
Saddle width	–2.41 (–3.62, –1.19)	<0.000

CI = confidence interval; BMI = body mass index.

Ultrasonographic and Doppler Findings of Subclinical Clitoral Microtraumatisms in Mountain Bikers and Horseback Riders

J Sex Med 2009;6:464–468

Cesare Battaglia, MD, PhD,* Rossella Elena Nappi, MD,† Fulvia Mancini, MD, PhD,* Arianna Cianciosi, MD,* Nicola Persico, MD,* and Paolo Busacchi, MD*

*Department of Obstetrics and Gynaecology, University of Bologna, Bologna, Italy; †Department of Obstetrics and Gynaecology, University of Pavia Research Centre for Reproductive Medicine, Pavia, Italy

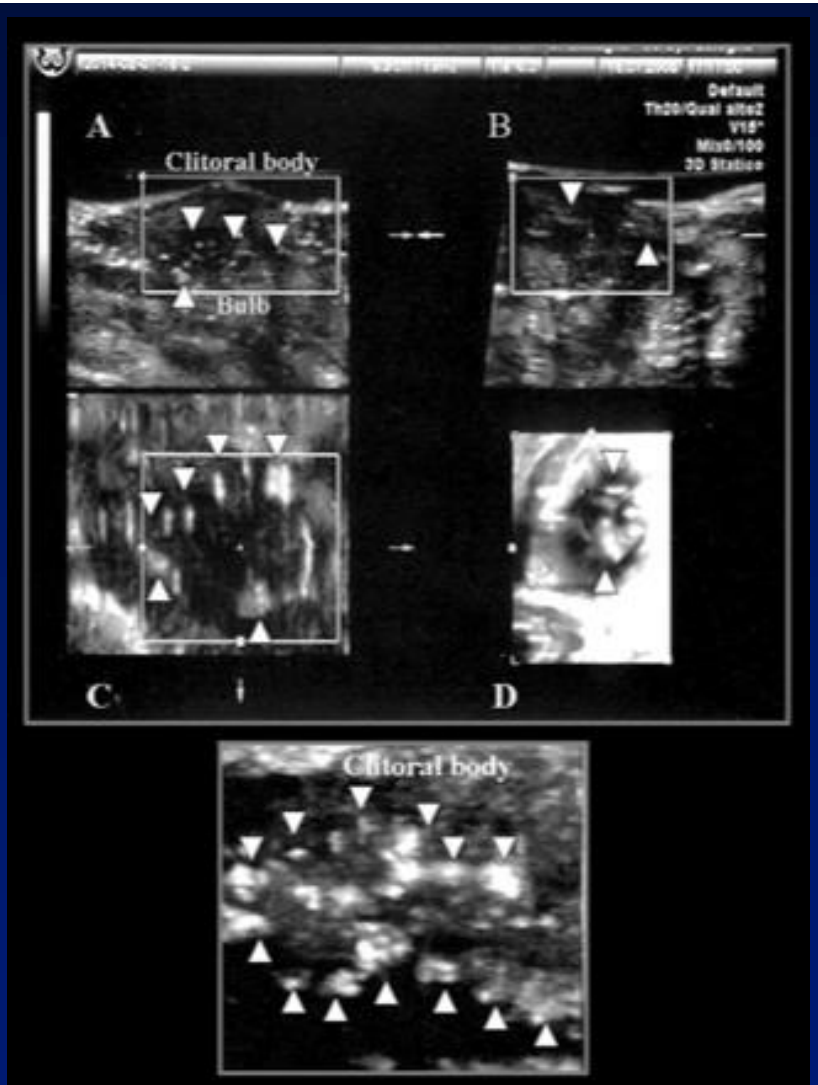

Elliptical Bicycle Riding – THE SAFE ALTERNATIVE

Clitoral Priapism

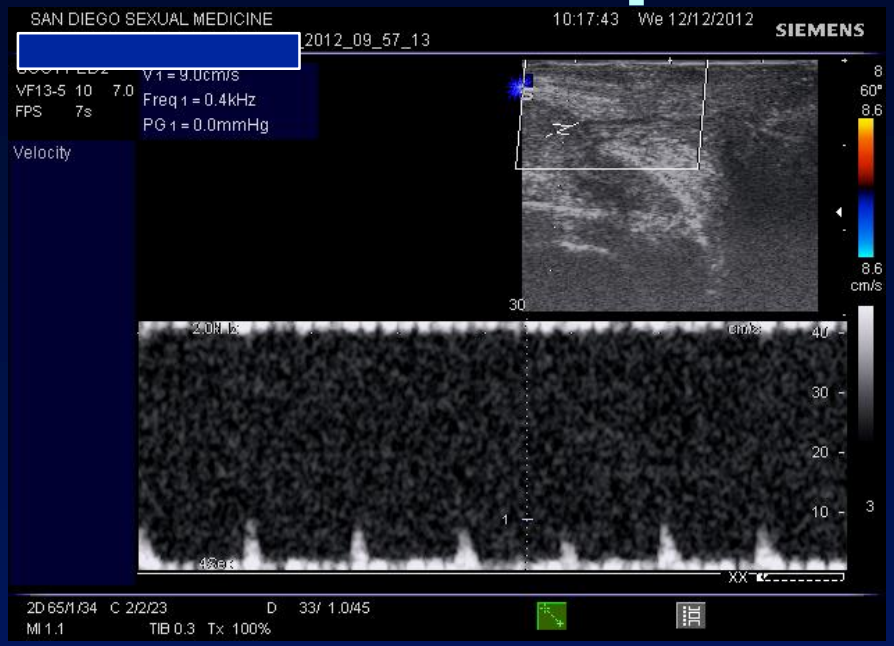

Courtesy Dr. I Goldstein

Clitoral Priapism

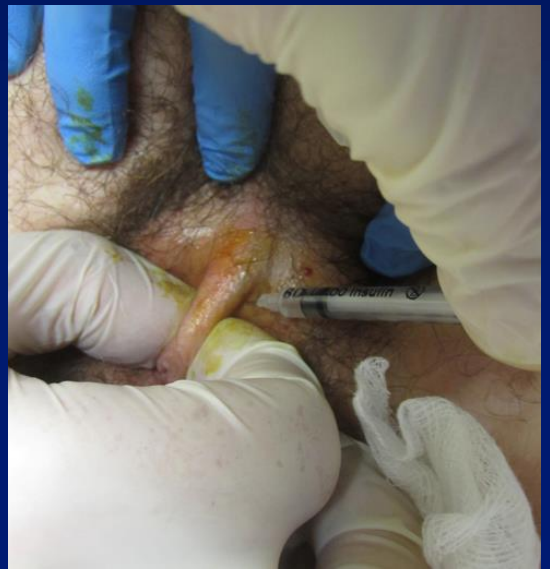

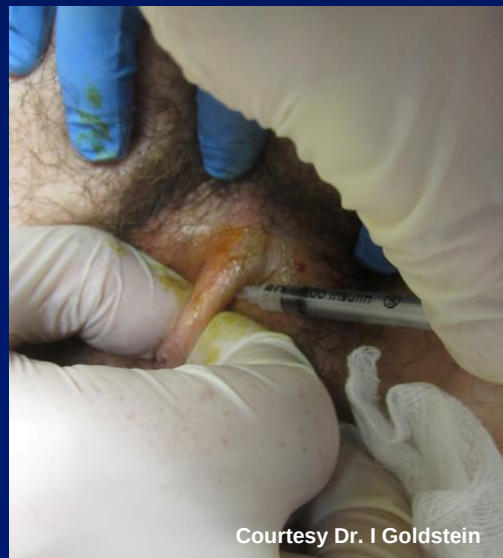

Courtesy Dr. I Goldstein

Clitoral Priapism

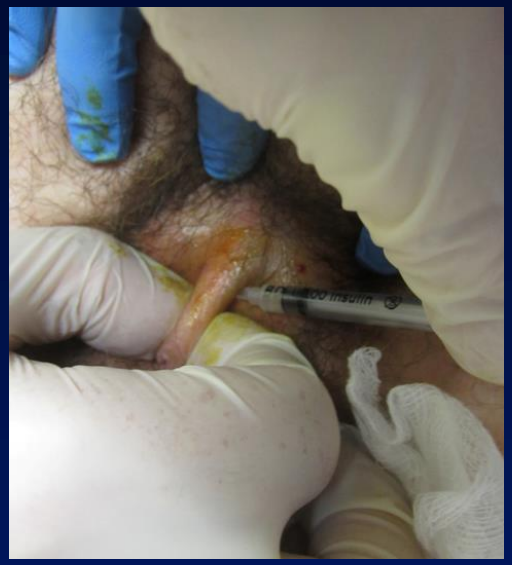

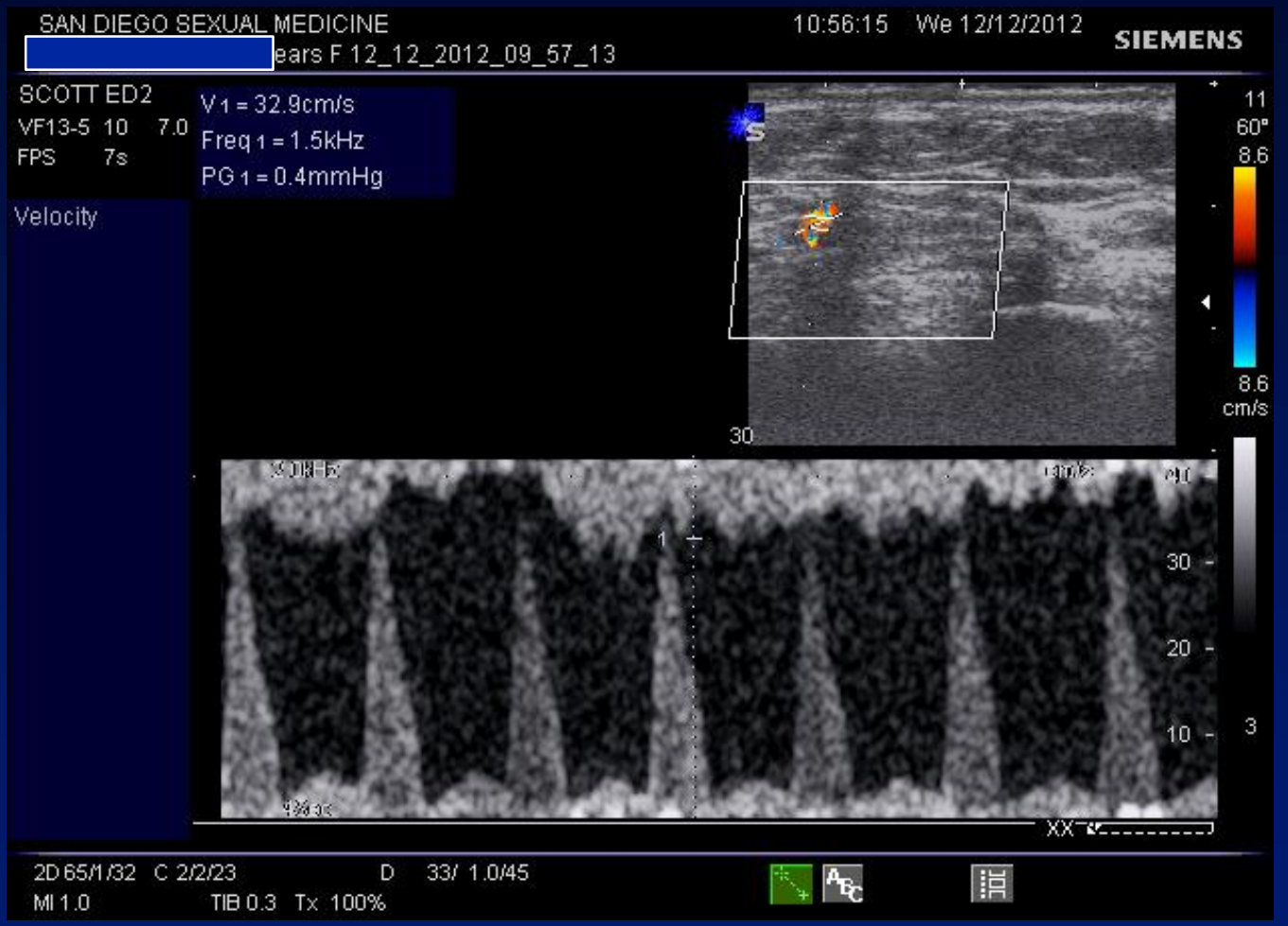

Dramatic relief of pain for 13 hours

Courtesy Dr. I Goldstein

Diagnosis and Treatment Algorithm for Sexual Dysfunction

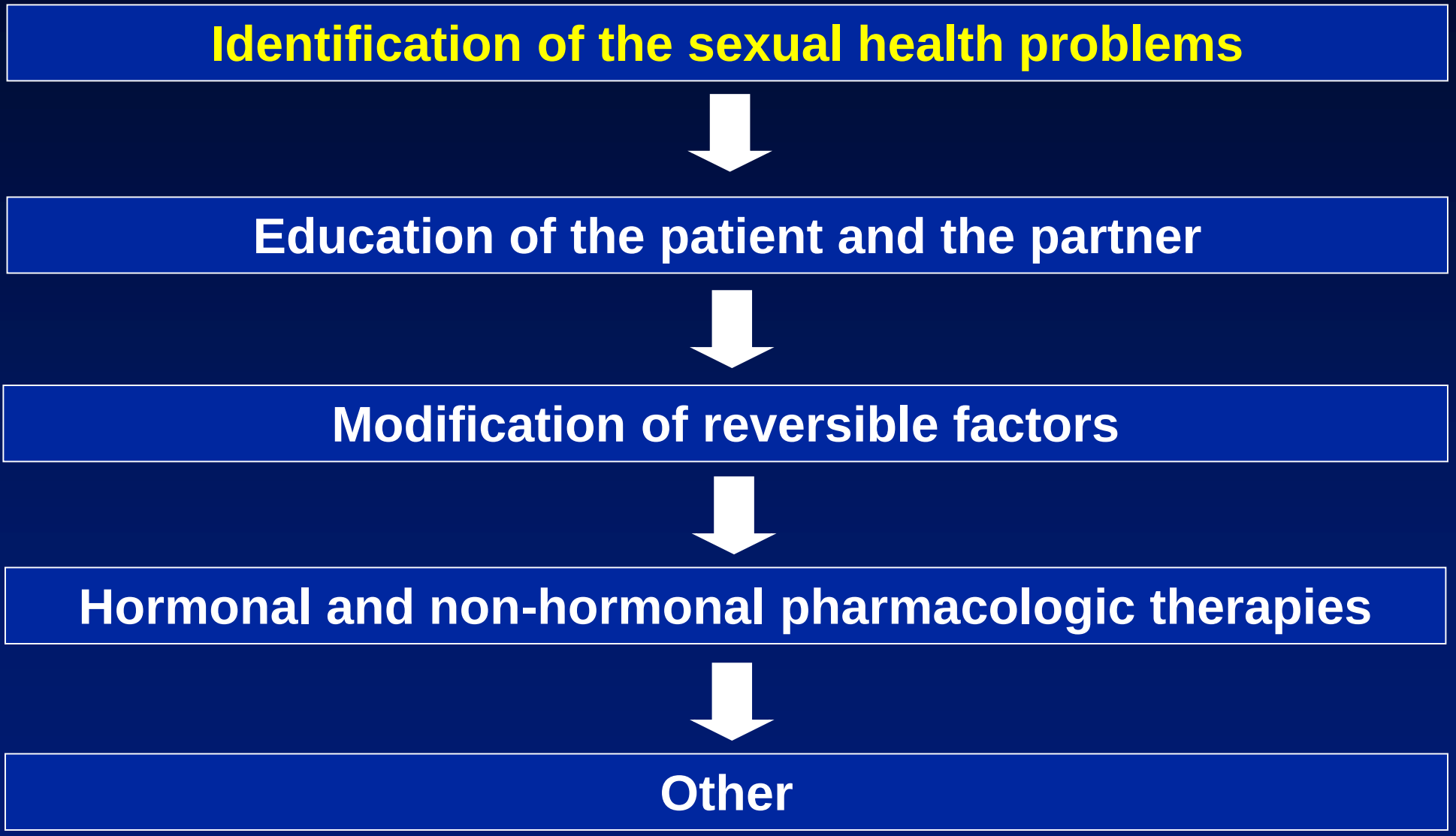

Goldstein I, Alexander JL. Practical aspects in the management of vaginal atrophy and sexual dysfunction in perimenopausal and postmenopausal women. J Sex Med. 2005 Sep;2 Suppl 3:154-65.